AN ATLAS OF GENERAL PATHOLOGY

WITH SPECIAL REFERENCE TO SWINE DISEASES

AN ATLAS OF GENERAL PATHOLOGY

WITH SPECIAL REFERENCE TO SWINE DISEASES

AN ATLAS OF GENERAL PATHOLOGY

WITH SPECIAL REFERENCE TO SWINE DISEASES

By

J. M. King, D. V. M., Ph.D.

F. S. Hsu, D. V. M., Ph.D.

C. B. Hong, D. V. M., Ph.D.

R. C. T. Lee, D. V. M., Ph.D.

A Special Publication of the

Joint Commission on Rural Reconstruction

and the

Pig Research Institute of Taiwan

Republic of China

May, 1976



Copyright © 1976 by the
Joint Commission on Rural Reconstruction
37 Nanhai Road, Taipei, 107
Taiwan, Republic of China

First Printing, May 1976
Composed & Printed by China Color Printing Company Inc.
Taipei, Taiwan, Republic of China

In Memory of
Laura Shu Yin H. Lee

Preface

This atlas is an attempt to put into book form pictures of the most common lesions and other findings observed during the necropsy and microscopic examination of animals and their tissues. Normal structures and changes as well as artefacts and changes due to decomposition are included as these also cause much difficulty in necropsy interpretations. A few less common lesions are included.

It is hoped that persons with the need to examine animal tissues will find this book useful, such as veterinarians in their clinical work, physicians working with research animals, wildlife biologists in their field studies and especially veterinary students in their pathology and necropsy classes. Other individuals, as animal husbandry and biology students with basic knowledge in anatomy, histology and medical terminology will also be able to gain much from it.

We have used the pig as the pattern animal as most of the pictures were taken of Taiwan pigs. Pictures from other species are included where necessary to demonstrate a lesion which may not occur in this species or which we did not have a picture of from a pig.

The caption content is based on our experience and general knowledge in pathology, and we leave it to the interested reader to get more complete information from the excellent texts, both veterinary and human, that are available.

We have tried to choose a specific lesion or change that will represent one period of time in the development of that change. We hope all our readers realize that pathological change is a dynamic process which changes sometimes rapidly, sometimes slowly. The same can be said of the extent and severity of a lesion and thus we have chosen, in most instances, to show a representative example and not one of each degree. As it would be impossible to picture each lesion in every developmental stage in all organs, we have chosen, in many cases, to demonstrate the lesion in only one or two. For instance, the infarcts pictured in the book are shown in only a few organs while in reality they can and do occur in many organs. Such a fact we would expect the reader to learn from the basic texts.

The format follows roughly the order in which the organ systems are examined grossly by one of the many techniques used in animals.

Most of the histological sections have been stained with hematoxylin and eosin (H&E), but a few special stains have been used and are so indicated.

The authors are indebted to our teachers Drs. P.Olafson, C.G.Rickard and K. McEntee.

We owe our thanks to Drs. R.J.Panciera,D.C.Dodd, H.Olander and Cornell University, Oklahoma State University, Carnegie-Mellon University as well as the Pig Research Institute of Taiwan, who or which have loaned us slides and allowed us to make pictures of them. We are deeply indebted to the Joint Commission on Rural Reconstruction of the Republic of China and

the Taiwan Sugar Corporation for their material and financial aid.

We would also like to thank our colleagues at PRIT: Drs. N.C.Chou, W.F.Chang, H.L.Han, R.S.Liu, C.S.Lee, S.Y.Liu, C.N.Wung, Miss C.K.Tyan and Miss S.C. Wong, who aided us physically and morally in the preparation of this book.

To those using this book we would like to encourage them, when making a diagnosis, to follow the "KIS" principle. "Keep it simple".

John M. King
N.Y.S. Veterinary College
Cornell University
Ithaca, New York, U.S.A.

Frank S. Hsu
Pig Research Institute of Taiwan
Chunan, Miaoli
Taiwan, ROC

Chuen B. Hong
School of Veterinary Medicine
College of Agriculture
National Taiwan University
Taipei, Taiwan, ROC

Robert C.T. Lee
Joint Commission on Rural Reconstruction
Taipei, Taiwan, ROC

Acknowledgement

The publication of this book offers me an opportunity to acknowledge the contributions of my professors at Cornell and many of my colleagues, without which the systematic study of veterinary pathology in Taiwan would have been impossible, not to mention the preparation of this volume. Their contributions tell in part the development history of veterinary pathology in Taiwan over a period of approximately twenty years. In recognition of the basic importance of pathology in veterinary teaching and research, I had a strong urge as early as 1949, when I was chief of the vaccine room of the Taiwan Provincial Veterinary Serum Institute, to pursue further studies in this field. However, not until 1958 when I was serving with the Joint Commission on Rural Reconstruction (JCRR) was I able to have the chance, with strong recommendation of the late Mr. James A. Hunter, chief of the Animal Industry Division of JCRR and the late Dr. William A. Hagan, Dean of the New York State Veterinary College at Cornell University, to be admitted to the Veterinary College at Ithaca. During the period of 1958-61 when I was working for my doctorate, I was indebted to Drs. Peter Olafson and Charles G. Rickard for the training they gave me in veterinary pathology, and to Dr. John M. King with whom I worked closely in the autopsy room, an experience that had benefited me profoundly.

After returning to Taiwan in the winter of 1961, I began to devote myself to establishing pathology laboratories and teaching. Among the laboratories so established, the most successful is the one associated with the Pig Research Institute of Taiwan (PRIT), which was set up with the cooperation of the Taiwan Sugar Corporation (TSC). The laboratory owes its proper and smooth functioning to the able leadership of Prof. F. K. Koh, Director of the Institute. It is this laboratory where most of the pathologic specimens for the present volume were collected.

In the more than ten years that followed, my colleagues at PRIT and TSC, Dr. Frank S. Hsu, Mr. N. C. Chou and my late wife Laura S. Y. H. Lee, helped take care of the pathology laboratory and kept busy in performing autopsies and collecting specimens. From the very start, it was our plan to use the laboratory for systematically maintaining our autopsy records and specimens and compile an atlas of swine pathology with these local materials for the benefit of Taiwan's veterinarians. Later, due to my heavy administrative responsibilities, I was unable to keep up with the pathology work. The burden of the task then fell mostly on them. Together with Dr. C. B. Hong, they carried on the work without interruption. I am glad that both Dr. Frank S. Hsu and Dr. C. B. Hong were able to attend Cornell University and complete their Ph. D. training in pathology during this period. They are the major co-authors of the book.

The publication of this book finally became a reality with the arrival of Dr. John M. King of Cornell University, who came to Taiwan at the invitation of JCRR to serve as a consultant in 1975-76. My special thanks are due to Mrs. John M. King who took pains to go over the

entire text. Without her encouragement, I wonder if their trip to Taiwan could have been so nicely arranged. In the preparation of materials for this book, naturally all the staff members of the laboratory as well as a number of other scientists were involved. Their names are given in the preface.

The Pig Research Institute of Taiwan and the Animal Industry Research Institute of the Taiwan Sugar Corporation offer excellent facilities for research in the various branches of swine science. The PRIT also provides a number of research posts for international cooperative projects. This book testifies to the beneficial results that may come out of an international level cooperative program.

To facilitate its use in veterinary teaching in Taiwan, the co-authors will work on a Chinese version to be put out later. Also being planned is the production of a set of slides with synchronized sound recording on tape. It should be pointed out here that all the aforementioned activities have been carried out with assistance from JCRR. It is through the Joint Commission's continuous support and direction that this volume has materialized.

I sincerely hope that this special publication of JCRR and PRIT will not only be useful in the study of veterinary pathology but also be helpful to those engaged in biologic and medical research.

Robert Chung Tao Lee, Ph. D.
Chairman
Chinese-American Joint Commission
on Rural Reconstruction

and

Chairman
Board of Directors
Pig Research Institute of Taiwan

Contents

	Page number		Plate number
Chapter I	1	Skin	1
Chapter II	28	Musculoskeletal System	
		Bones	55
		Joints	75
		Muscles	87
Chapter III	54	Peritoneum	106
Chapter IV	60	Liver	116
		Gallbladder	155
Chapter V	81	Pancreas	157
Chapter VI	83	Urinary System	
		Kidneys	161
		Bladder	215
Chapter VII	115	Female Genitalia	225
		Mammary Gland	243
Chapter VIII	127	Male Genitalia	249
Chapter IX	133	Respiratory System	
		Upper Respiratory Tract	261
		Pleura	274
		Lungs	283
Chapter X	181	Cardiovascular System	
		Pericardium	355
		Heart	360
		Blood and Blood Vessels	392
Chapter XI	208	Lymphoid System	
		Spleen	409
		Thymus	425
		Lymph nodes	427
Chapter XII	225	Alimentary Tract	
		Mouth and Esophagus	442
		Stomach	451
		Small Intestine	475
		Large Intestine	502
Chapter XIII	268	Nervous System	
		Brain	528
		Spinal Cord	559
		Eyes	564
Chapter XIV	287	Endocrine System	566
Index	293		



PLATE 1: LIVOR MORTIS

The dark areas of skin (livor) are the result of postmortem draining of blood (hypostasis) to these areas. The pale white areas (pallor) were the areas the pig was lying on with the resultant compression keeping the blood out of these areas. It can be determined from this that the pig died almost in sternal recumbancy, lying on its right legs and ventral abdominal wall. It was placed on its left side for the photograph. It should be noted that an animal may die in one position, but before much hypostasis and coagulation occur, the body can be moved and a different pattern of livor mortis produced. This is often important in forensic pathology. Related terms are algor mortis, the cooling of death, and rigor mortis, the stiffening of death.

PLATE 2: PASSIVE CONGESTION

The well delineated reddening of the skin with the same distribution internally is passive congestion. It is a result of decreased venous return from the sow lying on the cranial three fourths of this piglet's body. As most pig raisers have facilities to protect the piglets from being laid on, one should suspect that the piglet was sick and too weak to get out of the sow's way.

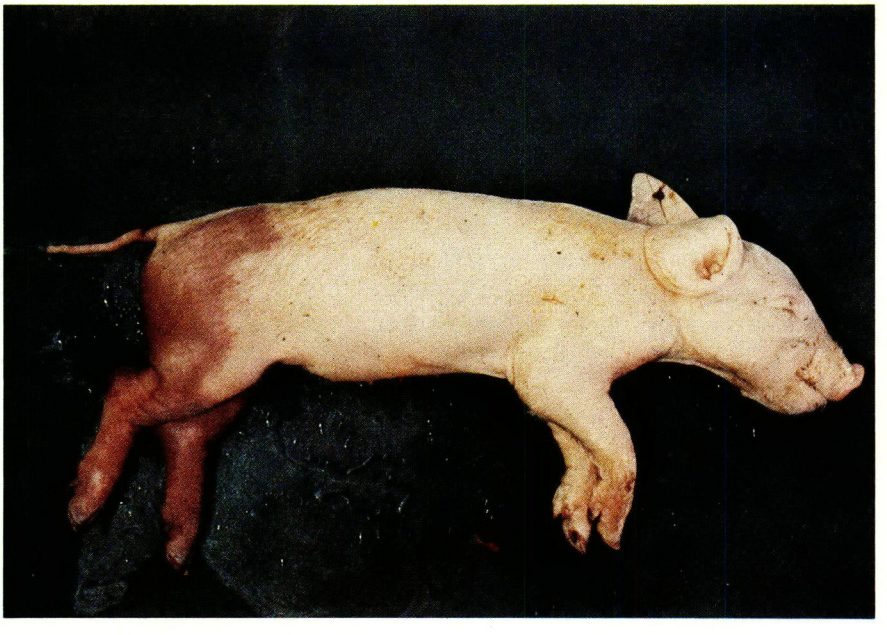



PLATE 3: BLOOD SMEARING OF RUMP AND TAIL

The skin of the rump, tail and perineum is distinctly smeared with dark, partially digested blood from the gastrointestinal tract. The pattern seen is from the tail swishing. While this is a case of intestinal hemorrhage associated with swine dysentery, it may also be seen in other hemorrhagic gastrointestinal problems as bleeding gastric ulcers and the hemorrhagic bowel syndrome (HBS) in pigs, etc..

PLATE 4: EAR BITE WOUNDS AND POSTMORTEM(PM) EPIDERMAL SLOUGHING

Several linear contusions are present as dark lesions in this ear lobe as a result of bites from other pigs. Along the free edge is a well healed almost square notch of the identification number system used in these pigs. A large sheet of superficial epithelium has sloughed showing the underlying congested tissue which is otherwise normal. This is most commonly seen as a result of heat as from the hot sun after death.



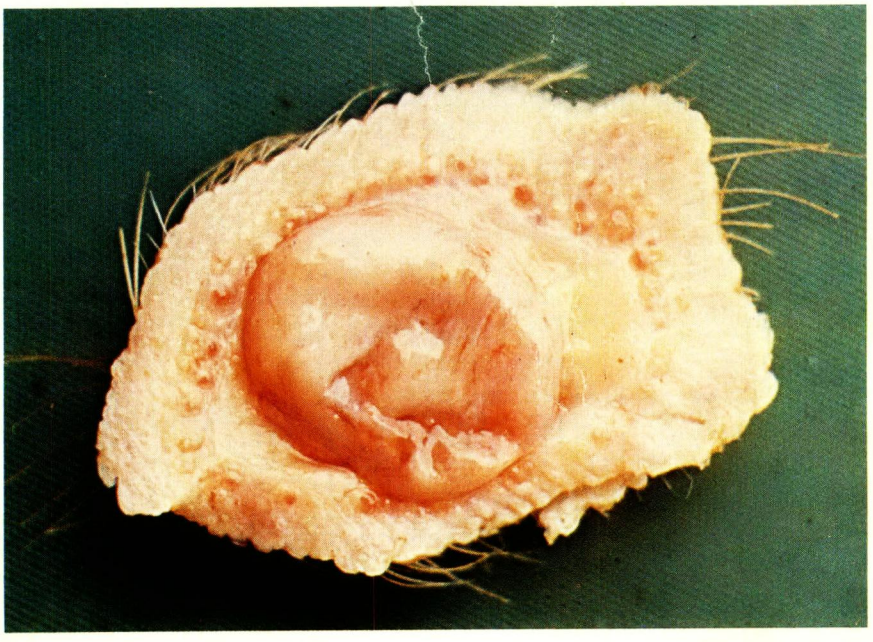

PLATE 5: BURSAL CYST

Externally this was a small fluctuating mass under the skin over the lateral surface of the left elbow in an adult boar. It is seen here as a distinct, rounded saclike structure partially collapsed and still attached to the skin. It consists of a connective tissue (CT) capsule with shreds of mature collagenous fibers and serous fluid internally. Some are considered normal in a few common locations. Most are a reactive process for protection over a bony prominence.

PLATE 6: ANEMIA

The entire carcass is paler than normal and what little blood is present is also pale and watery with greatly reduced viscosity. One's first guess in pigs should include a bleeding gastric ulcer, nutritional anemia (baby pig anemia), swine dysentery or hemorrhagic bowel syndrome. In cattle, we should also consider an abomasal ulcer, stomach worms (Hemonchus spp.) and lymphomatosis. Anemic sheep are commonly affected with stomach worms (Hemonchus spp.). Dogs, especially puppies, are easily made anemic by hookworms. Of course other causes can be enumerated for any specific area or prevalent disease conditions.

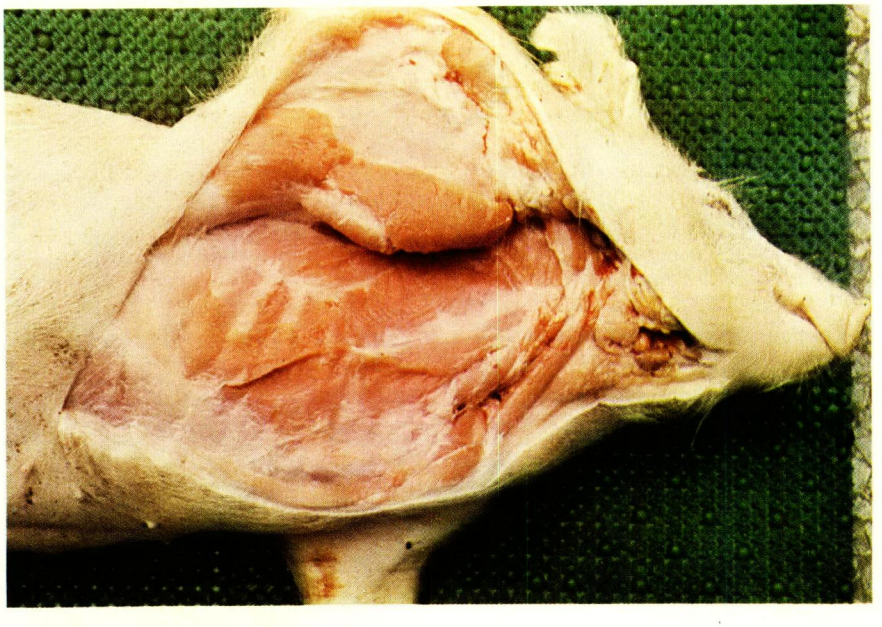



PLATE 7: ANEMIA

The conjunctival membranes and other ocular tissues as well as tissues exposed by the dissection process are markedly pale. The blood on the tissues is thin and watery. These lesions are quite diagnostic for anemia. In sheep, the first diagnosis should be Hemonchus contortus, the large stomach worm. Hookworms should be an initial guess in young puppies. In pigs, the common gastric ulcer is to be considered. Lymphomatosis and Hemonchus contortus again should be considered in cattle. There are many causes for anemia on a sporadic basis in the numerous animal species, and in endemic areas certain specific diagnoses may be more likely.

PLATE 8: GENERALIZED ICTERUS

The yellowish discoloration of this animal's body is termed icterus (jaundice). It is also to be seen in most of the normally whitish tissues in the body not seen in this picture such as the brain, joints and aorta. The three types of jaundice are hemolytic, from the breakdown of blood as in this case of neonatal isoerythrolysis in a foal, obstructive, from obstruction of bile flow into the intestine and hepatic or toxic, which is the result of liver damage preventing proper metabolism and elimination of normal blood pigments. Icterus is to be differentiated from the normal yellowish pigmentation (carotenoids) seen in some animal breeds such as Jersey and Guernsey cattle and less marked in horses. This is an example of endogenous pigmentation.

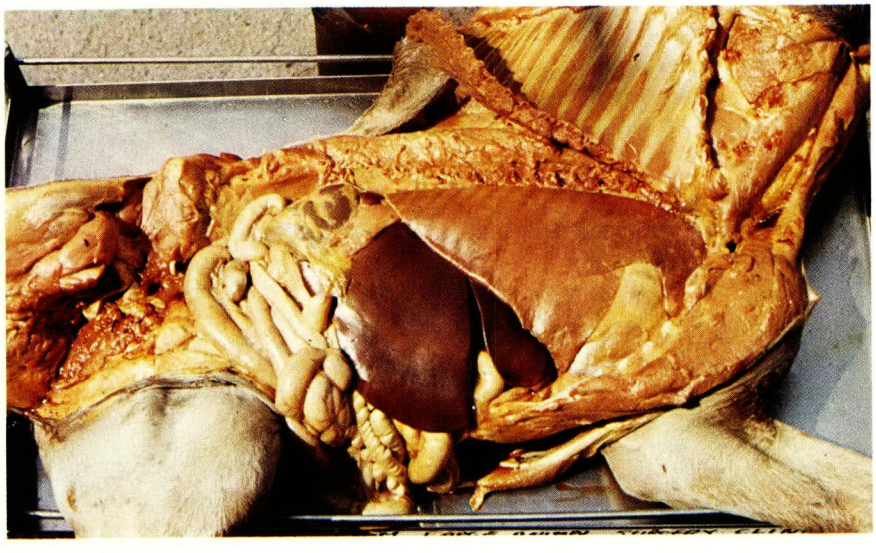

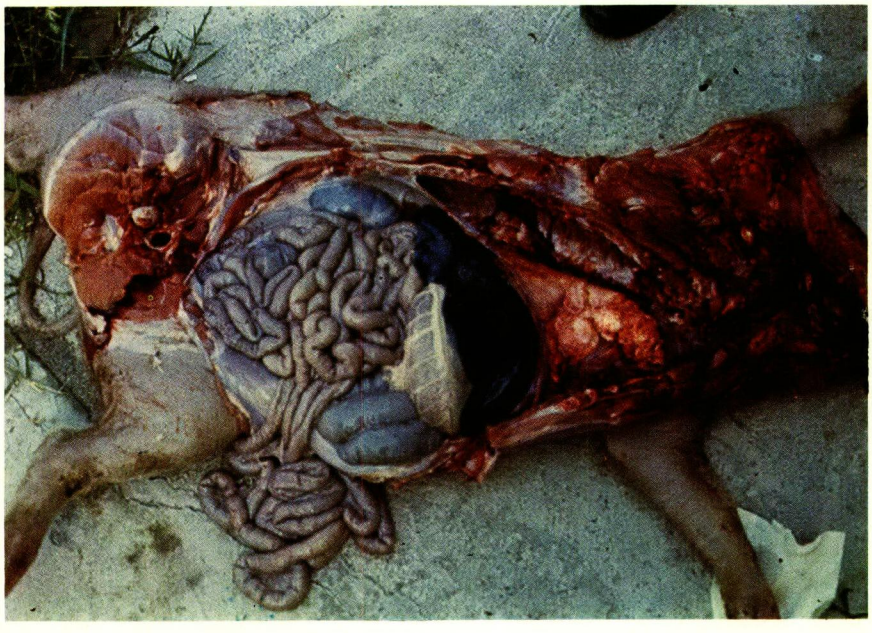

PLATE 9: GARDENIA POISONING

The bluish grey discoloration of this pig's skin, peritoneur ' other tissues not seen here as the aorta, brai l meninges are the result of being fed the seeds of the gardenia plant, Gardenia jasminoides. The actual agent involved is not known. Several elemental metals can also cause a similar lesion, and other chemicals are known to cause various pigmentary changes in body tissues. This pig had access to about a 10% level of dried gardenia seeds in its diet. This is an example of exogenous pigmentation.

PLATE 10: IMPERFORATE ANUS

This piglet has been partially necropsied to explain the cut tissue in the lower escutcheon. The highlighted area just under the tail base represents the location in which the anus should normally open. In this anomaly, the proctodeum has failed to open to form the anus. Surprisingly, these little pigs may live for weeks or even months with megacolon developing to accomodate the feces. This condition is to be differentiated from atresia recti in which the rectal lumen is constricted more cranially in the GI tract allowing insertion of a finger or blunt instrument into the anus at least as far up as the constriction.

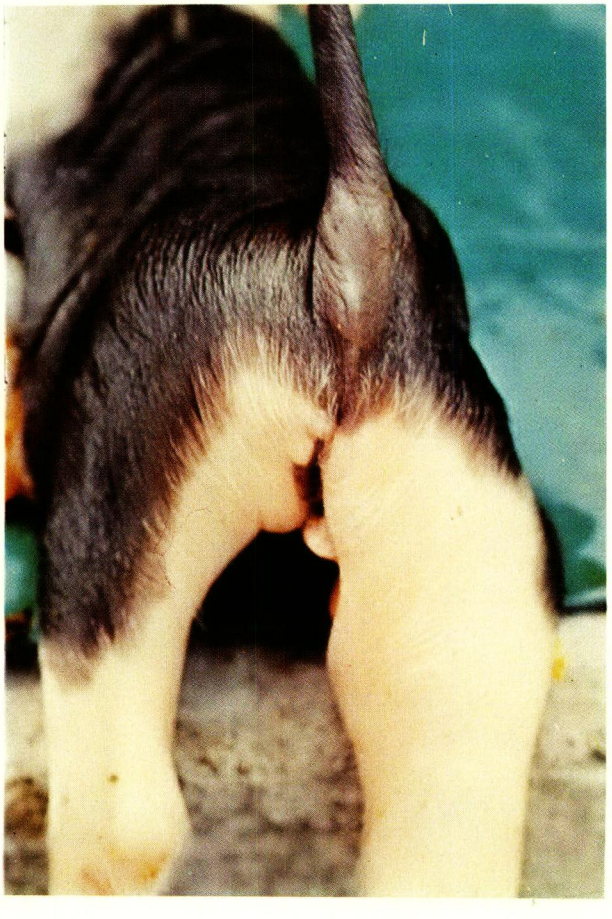



PLATE 11 EPITHELIOGENESIS IMPERFECTA

This partially necropsied and formalin fixed piglet shows scattered but clearly defined brownish areas of body surface completely devoid of skin. The whitish areas are essentially normal areas of haired skin. Even the distinct line up the lateral surface of the left foreleg is a line of defect. The brownish areas are congested dermis with some hemorrhage and exposed vessels as no epithelial layer covers them. This congenital anomaly is more common in pigs than other species. If these areas are small enough and infection is prevented, they may scar, epithelize and the animal may survive. This is a bilaterally symmetrical lesion.

PLATE 12: EPITHELIOGENESIS IMPERFECTA

This histological section shows a portion of hyperplastic epidermis on one side with a thin band of epidermis extending over the middle section of tissue and no epithelial covering over the other side. This thin band of epidermis is an attempt at epithelization of the defect in the skin. Some keratin and cellular debris lies on the epithelium but only cellular debris overlies the dermis in the remaining defect area. Histologically, this can be called an ulcerated portion of skin with progressing epithelization. It can be seen following loss of epidermis as from trauma or burns.

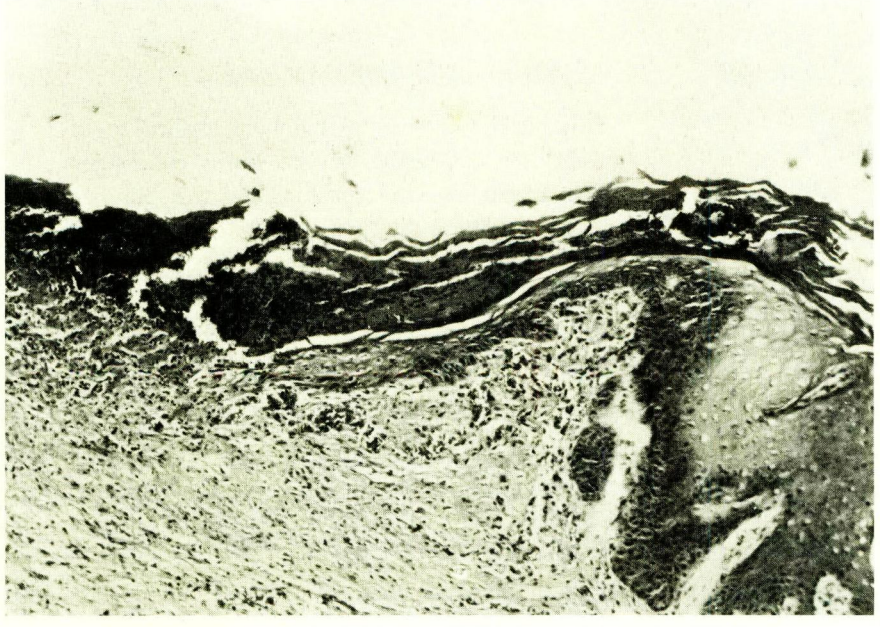

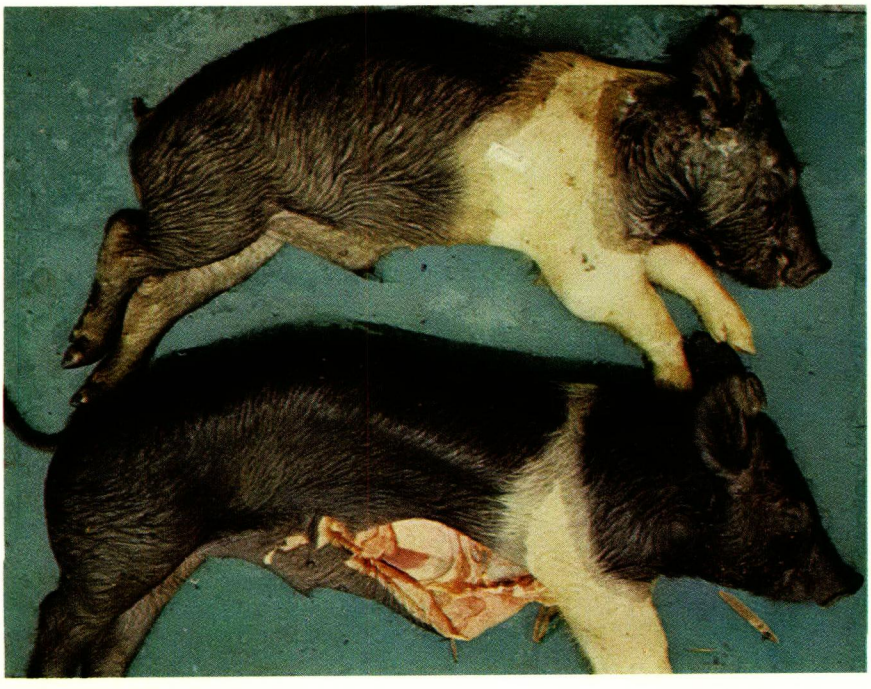

PLATE 13: RUNTING DISEASE

These two piglets are litter mates and were approximately the same size when born. Their heads now are about the same size but one piglet's body is noticeably larger. The smaller (runt) pig has a swollen right elbow joint which was found to be an abscess at necropsy. Scattered abscesses were seen in other areas and a chronic cranioventral pneumonia was also present. These lesions have all contributed to the disproportionate slow growth of the body while the head continued to grow at a relatively normal rate thus demonstrating the major feature of runting disease, a large head on a small body. The litter mate is normal. A runt is to be differentiated from a dwarf by the fact that a dwarf's body is proportional to its head size. Heart anomalies and renal lesions in young animals may also result in runting.

PLATE 14: PARAKERATOSIS

The major portion of this pig's skin is thick and wrinkled especially on the abdomen and legs. It does not appear to be irritating to the pig. Histologically, there is much excess keratin (hyperkeratosis), and in addition, the epithelial cells in many areas fail to keratinize, shrink or lose their nuclei as does normal skin. The epithelial cells in the keratin layer tend to retain their basic size and nuclei giving it the name parakeratosis. Most consider this a deficiency of zinc, but mineral imbalances involving zinc play an important role also.





PLATE 15: PITYRIASIS ROSEA

These lesions are mainly irregular rings and plaques of swollen reddened skin often with a central depression, scattered on the pig's abdomen and medial leg surfaces. They may also extend up along the sides and neck. Most do not appear to cause the pig any discomfort and spontaneously regress. An allergic cause is suspected but not yet proven.

PLATE 16: ALLERGIC DERMATITIS

Some cellular debris is present in the keratin layer of this skin section through a raised ring in a case of pityriasis rosea in a pig. A large number of round cells, mostly plasma cells and eosinophils, have infiltrated the dermis and around blood vessels with a few in the epidermis proper. In more chronic cases, lymphocytes and plasma cells predominate.

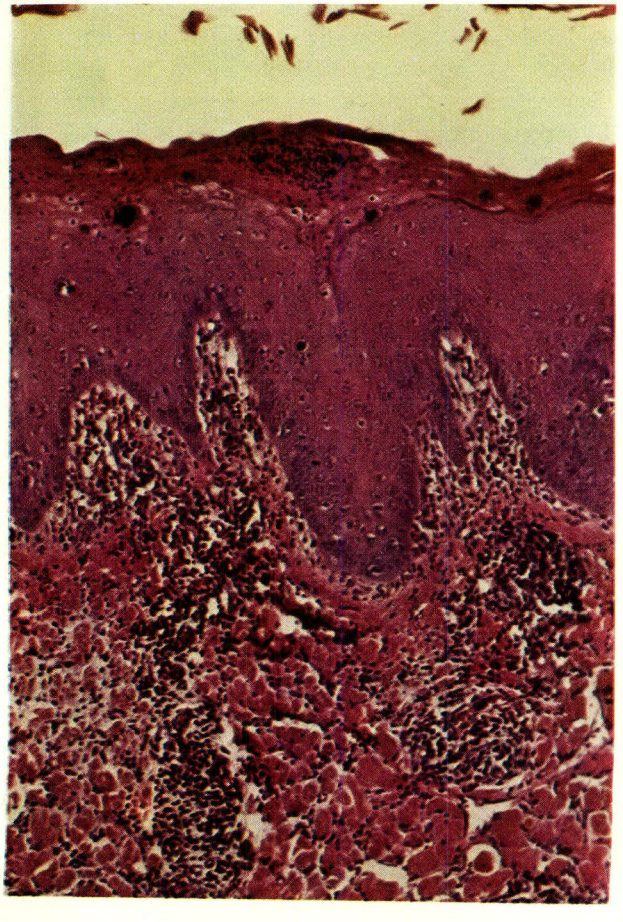

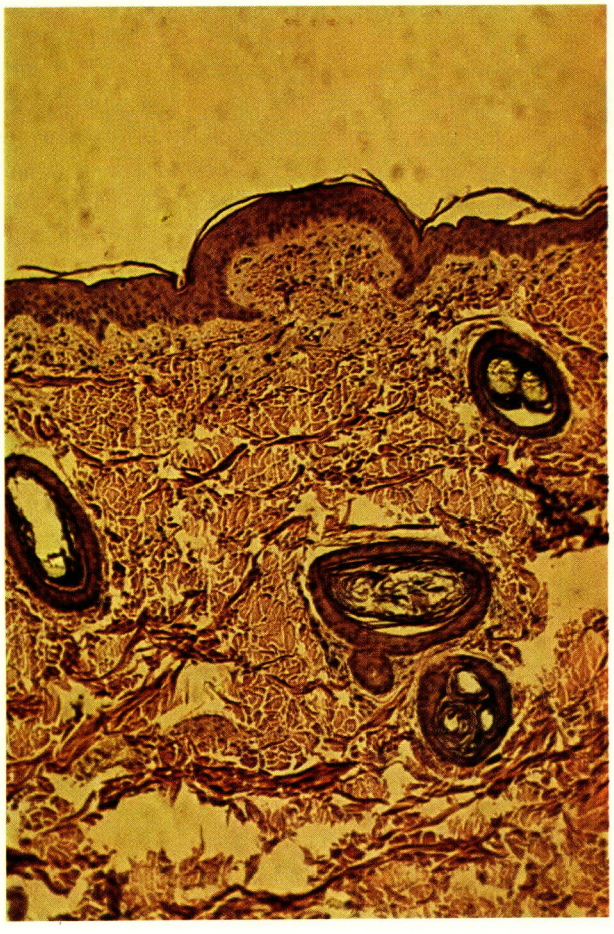

PLATE 17: ENDOCRINE ALOPECIA

The thinning of the epithelium, lack of accessory skin glands and the hyperkeratosis of the hair follicles all suggest that this animal has lost its hair clinically as a result of an endocrine dysfunction. The thyroid and adrenal glands are often at fault. There are other causes of alopecia (hair loss), but the gross distribution of hair loss and other lesions would help differentiate them.

PLATE 18: HIRSUTISM (HYPERTRICHOSIS)

The excessively long hair on this horse is termed hirsutism. A pituitary tumor is the usual cause of hirsutism in most animals. This horse had a chromophobe adenoma of the pituitary gland. The pathologically long hair must be differentiated from the normal long hair that develops in many animals that live in cold climates. A moderately long hair coat may be the result of cachexia or poor husbandry and grooming practices. This horse also has a sway back (lordosis).





PLATE 19: PHOTOSENSITIZATION

The excessive tearing (lacrimation) is the result of edema and keratitis caused, in this sheep, by the process of photosensitization brought on by an overdose of phenothiazine. The odd red color is from phenothiazine itself which has been eliminated in the tears. This is one of the major forms of this process and has been caused by an exogenous chemical (primary or exogenous photosensitization). Endogenous photosensitization is associated with compounds derived within the body and the third form, hepatogenous photosensitization, is associated with liver disease.

PLATE 20: FETAL ANASARCA

One of the two puppies is normal, but the other puppy is swollen with subcutaneous fluid. Both of these puppies were stillborn. The cause of this generalized subcutaneous edema is not known for sure, but there is some evidence that it may be related to an anomaly of the lymphatic system.

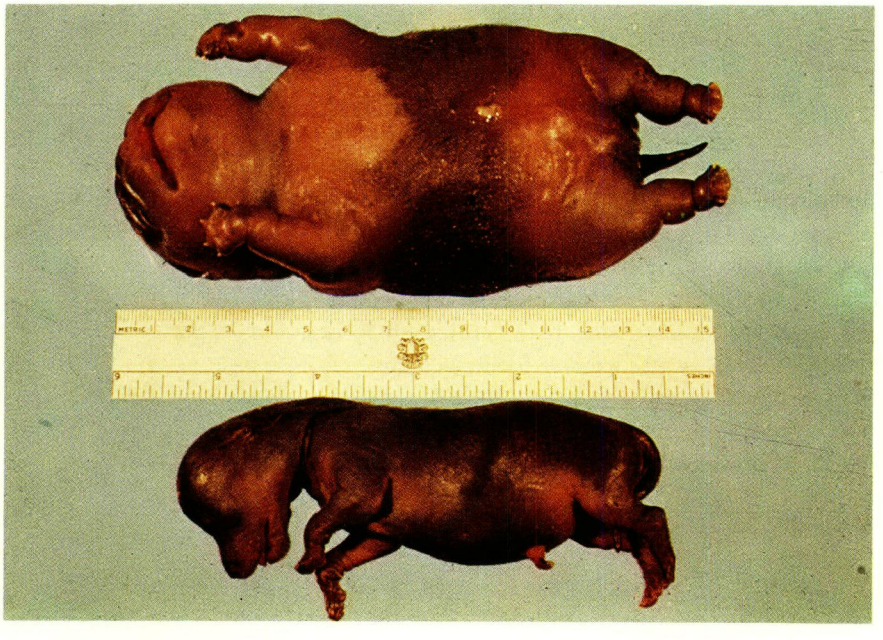



PLATE 21: EXTREMITY GANGRENE

The major portion of the ear of this cow has sloughed as a result of dry gangrene. The other ear, tail and both hind feet were also involved with loss of portions of each. Both front feet were several degrees cooler than upper areas on the same legs. Several other animals in this herd also had cooler feet than those considered normal in the herd, but did not have any evidence of gangrene. Such lesions are usually the result of ergot, fescue or chronic selenium poisoning.

PLATE 22: GENERALIZED EDEMA (ANASARCA)

The entire carcass, especially the head of this piglet is swollen and firm. At necropsy, a generalized watery infiltration (edema) of the subcutaneous tissues was noted along with a greatly enlarged thyroid gland. The pig differs from most other domestic animals in having a single thyroid gland in the midline near the thoracic inlet. Most other animals have two glands, some joined by an isthmus, located near the larynx. It is thought that its increased size and location may have obstructed the lymphatic return to cause the lymphedema. In this outbreak 20-30 litters were affected and losses stopped with iodine supplementation to the sows.





PLATE 23: SUBCUTANEOUS EDEMA

The overall appearance of this pig's body is that it is a fat animal, but closer observation shows the wasting of body muscles. The ventral abdomen is swollen with a definite ridge of demarcation between it and the flank. This, as proven when opened, is an infiltration of the subcutaneous tissues with clear watery fluid (edema). Palpation of the abdomen demonstrated the presence of excess abdominal fluid which caused the flank to bulge slightly. This pig had chronic passive congestion of the liver and chronic pleuritis and adhesive pericarditis. The adhesive pericarditis decreased venous return from the liver resulting in backing up of blood to the liver and subsequently to the gastrointestinal tract and abdomen.

PLATE 24: "PITTING" EDEMA

The skin over this area of edema has been pressed by the prosector's fingers to show that it "pits on pressure" and is indeed edema and not a pocket of pus or a hematoma. After a time the "pushed out" edema fluid will diffuse back into these areas and they will regain their smooth contour. Edema in soft tissues will almost always "pit" no matter what caused the edema. In this case, the pig had chronic passive congestion of the liver (nutmeg liver) from a constrictive pericarditis decreasing venous return from the liver.





PLATE 25: ERYTHEMA

These flat, reddish, various sized blotches are mainly on the ventral portions of the skin with a few about the head and neck. Their borders fade gradually into the normal surrounding skin which distinguishes them from hemorrhage. Histologically, capillary congestion, fibrin thrombosis, endothelial degeneration and necrosis are well marked in these areas. Degenerating inflammatory cells are prominent around many of the capillary tufts in the dermal papillae. This condition occurred along with a massive cortical necrosis of both kidneys. The exact pathogenesis is unknown.

PLATE 26: SUBCUTANEOUS HEMORRHAGE

The reddish purple discoloration of the skin is due to hemorrhage into the subcutaneous tissue. No appreciable distortion of the affected area is otherwise noted and no muscle or bone damage was found. This should make one consider a bleeding disease such as Warfarin poisoning, Vit K deficiency, liver disease with prothrombin deficiency, or even a toxic agent as a snake bite. An iatrogenic lesion from an accidental needle injury to a major artery should also be considered. This problem was treated successfully by Vit K therapy.



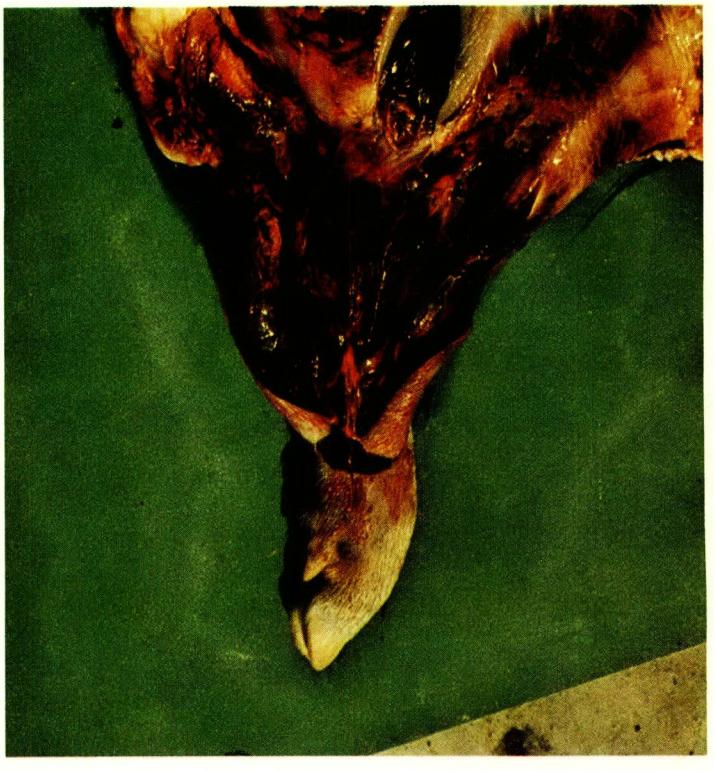

PLATE 27: SUBCUTANEOUS HEMORRHAGE

The bloody subcutaneous tissue about this pig's rear leg is the result of a Vit K deficiency and was corrected in the swine herd by Vit K therapy. Trauma, snake bites or other bleeding diseases can also be initially suspect.

PLATE 28: SUBCUTANEOUS HEMATOMA

The massive amount of blood in the left groin area of the one piglet and in the subcutaneous tissues of anothers left foreleg are hematomas associated with a suspected Vit K deficiency. Hemorrhages as a result of a bleeding disease such as this can be located in almost any tissue including the brain and heart. Even a small hematoma may cause death if located in a vital area. The kidney is a common site for internal hemorrhage from a bleeding disease and hematuria may be one of the first signs.





PLATE 29: CHEMICAL DERMATITIS

The two large dark patches on the skin below the hock are areas of surface congestion, hemorrhage and some necrosis raised off the dermis by a fluid filled cavity, a blister. These are second degree burns. The scattered patches and spots of severe congestion around and above the hock represent first degree burns. These were caused by an irritating chemical accidentally spilled on the pig. Any form of excess heat and many chemicals can cause a similar lesion.

PLATE 30: SWINE POX DERMATITIS

Most of these small, red, roundish lesions scattered around this gilts teats are in the scab stage of the pox lesion. The prior stages have already been completed. These are to be differentiated from the elongated lesions of teeth marks in nursing animals. This was a case of swine pox.

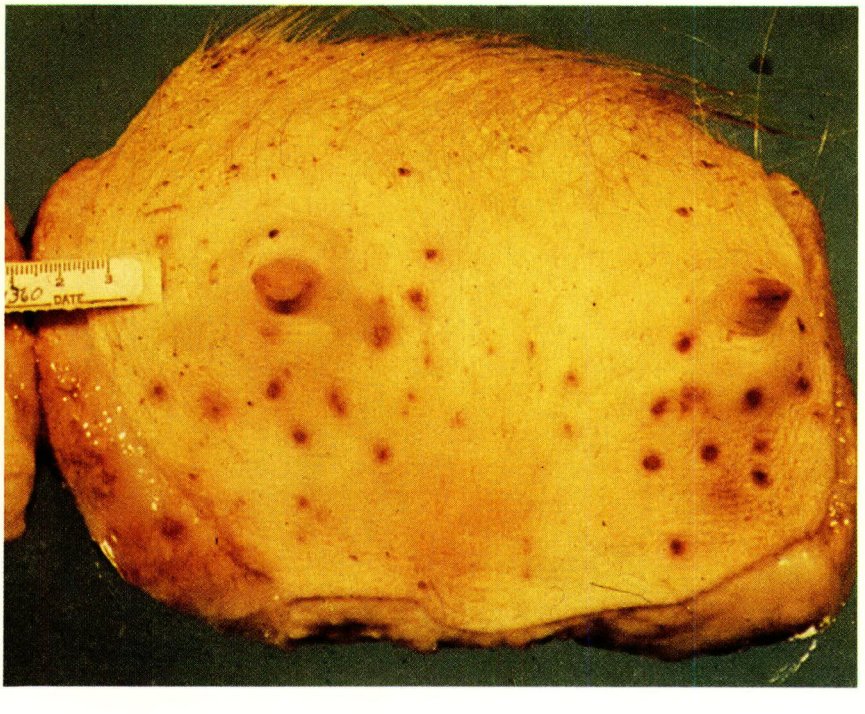

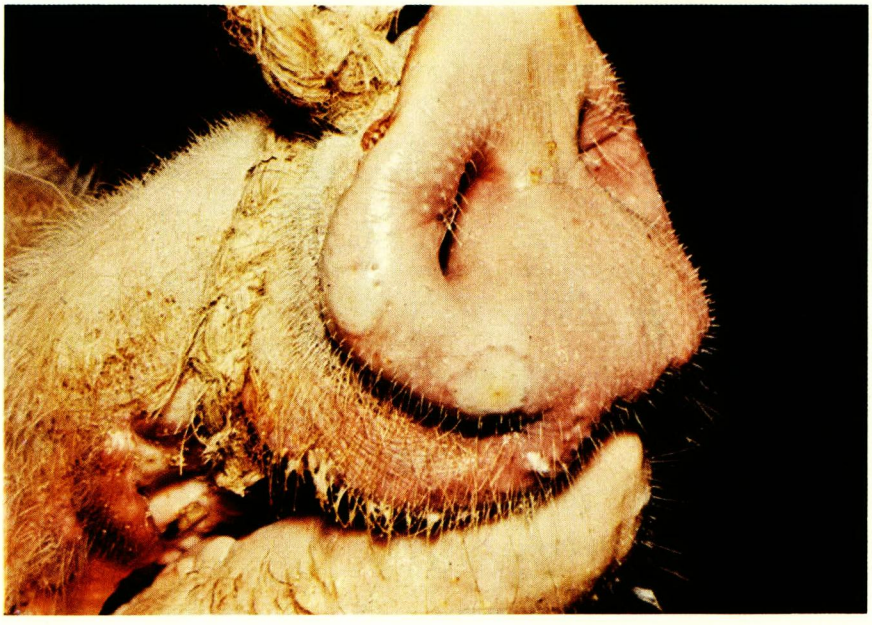

PLATE 31: SWINE VESICULAR DISEASE DERMATITIS

These two opaque plaque like vesicles on one side of the snout are the early lesions of degeneration and necrosis in the epithelium caused by the virus. Similar lesions may be seen on the udder and in the interdigital spaces. With time, they will slough centrally leaving a central reddened ulcer and a peripheral zone of opaque, swollen epithelium. A nonsuppurative encephalitis with a fairly characteristic partial wall necrotizing vasculitis with many neutrophils is commonly observed and was seen in this natural case of swine vesicular disease.

PLATE 32: SWINE VESICULAR DISEASE DERMATITIS

The several pale, slightly raised plaque like lesions on the udder proper and the teats are areas of epithelial degeneration and necrosis. Several have a brownish red, cratered center of ulceration remaining after the epithelium had sloughed. This was a natural case of swine vesicular disease. One has to differentiate this lesion from other viral diseases making similar lesions such as foot-and-mouth disease, vesicular exanthema and vesicular stomatitis.





PLATE 33: INTERDIGITAL VIRAL DERMATITIS

The reddened, slightly exudative lesion between this pig's toes is an example of epithelial degeneration and necrosis in a case of swine vesicular disease. Although its pathogenesis is the same as that of lesions on the snout and udder it is more irregular in appearance as its location allows for more superimposed traumatic damage. Other viral diseases, trauma and some bacterial infections may cause similar lesions.

PLATE 34: SWINE VESICULAR DISEASE DERMATITIS

The opaque white area on this pig's snout between the external nares is a plaque of epidermal degeneration and necrosis. This, while an experimental lesion, is similar to the natural lesions seen in swine vesicular disease. It will often slough leaving a thin underlying layer of basal epithelium and thus no inflammatory reaction is seen. When only the epidermis is involved, the more correct term should be epidermitis.





PLATE 35: SWINE VESICULAR DISEASE EROSION

The pinkish, hourglass area on the snout of this piglet between the external nares is a late stage lesion of swine vesicular disease. It is an area with the superficial epidermis already sloughed leaving a thin layer of basal epidermis to cover the quite vascular dermis making it pink. This is to be differentiated from an ulcer which is the loss of the entire layer of epidermis exposing the dermis or deeper mesodermal tissues.

PLATE 36: DERMATITIS

Scattered chronic inflammatory cells are seen in the dermis and rete pegs with the basal epithelium still relatively normal. The more superficial epithelium has become parakeratotic with swollen degenerating cells and some inflammatory cells infiltrating the area of epithelial degeneration. Over most of the surface, the keratinized layer is still intact although undermined by the degenerating areas. While this is a case of swine vesicular disease many other dermatoses can have a similar appearance.

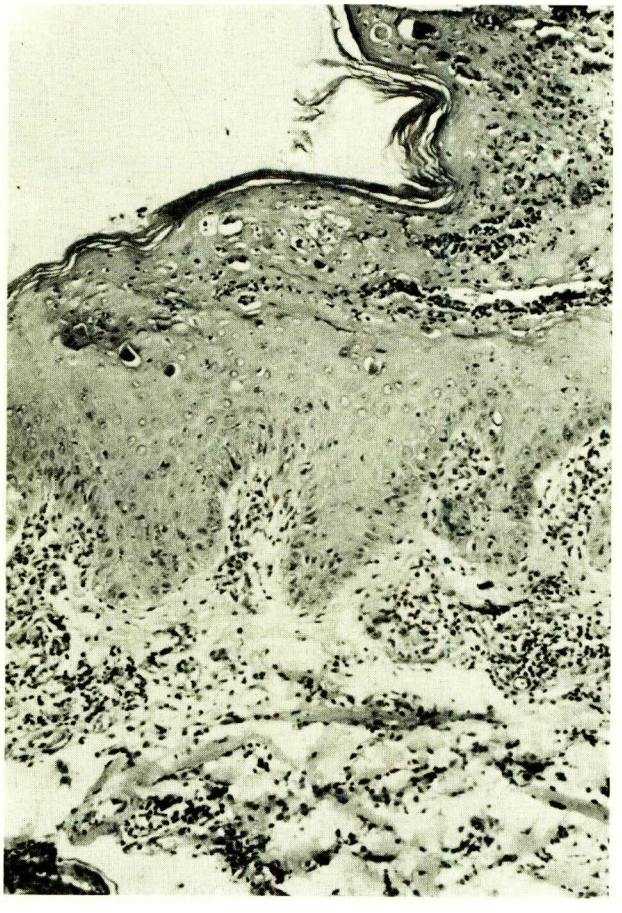



PLATE 37: SWINE ERYSIPELAS

The scattered red patches are areas of congestion which later may actually become infarcts as the causative organism, in this case E. rhusiopathiae, proliferate in the vessels to form thrombi. They also may have metastasized as bacterially infected emboli from a vegetative endocarditis. In some cases, massive areas even the entire skin of the back may become infarcted and slough. Of diagnostic importance is the presence of a straight side to one or many of these patches. Rhomboid patches are so common that this disease is also called diamond skin disease. One can pour alcohol over a lesion of a dead animal, burn it, peel the epidermis off and culture the dermis where the organisms are often found in great numbers. Arthritis and vegetative endocarditis in either heart, often with renal and splenic infarcts are also common lesions of chronic erysipelas. The splenic infarcts in this disease are to be differentiated from those of hog cholera by the absence of vegetative endocarditis in hog cholera.

PLATE 38: IMPETIGO

Numerous, scattered, discrete nodules of skin abscesses in various stages of development, from early dark red nodules to yellowish more elevated ones with a yellowish core, are present on this pig with impetigo. In turn, several of these have ruptured showing a cheesy dry core, while others have turned a dark brown and still others are just reddened areas of skin with a tiny central ulceration. Streptococci are often isolated from these lesions.



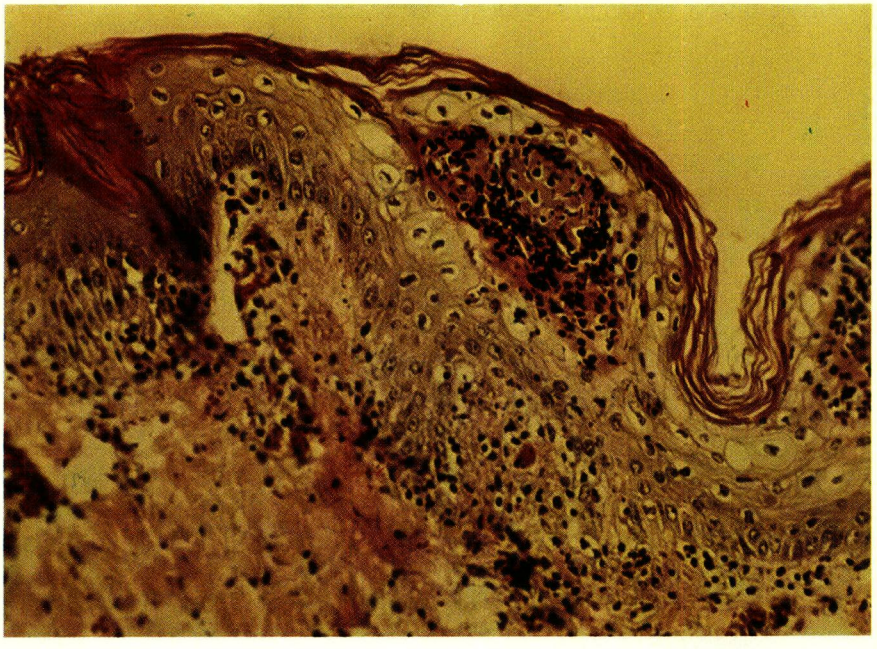

PLATE 39: INTRADERMAL ABSCESSATION

A relatively normal keratin layer is present over the epidermis. In one area of the epidermis itself there is a collection of neutrophils (abscess) about some pink epidermal debris, and in the underlying dermis, a moderate number of inflammatory cells have infiltrated. Grossly, this section came from a pig with lesions of impetigo, a disease from which Streptococci are usually isolated.

PLATE 40: GREASY PIG DISEASE (EXUDATIVE EPIDERMITIS)

Patchy areas of usually brownish to dark black deposits of debris on the skin about the snout, ears, eyes, feet and legs, especially the forelegs, are quite greasy on palpation. With a little water, the debris can be mixed into a soapy emulsion on the surface. Staphylococcus hyicus is the causative agent, but one often is able to culture almost any organism from such a contaminated surface.





PLATE 41: EPIDERMITIS

Many of the superficial epithelial cells are swollen and vacuolated with an infiltration of neutrophils in several foci. Keratin and necrotic cellular debris is lying on the surface and the vessels in the rete pegs are markedly congested in this section of skin from a pig with exudative epidermitis (greasy pig disease). This lesion is not diagnostic and may be seen in many types of dermatitis.

PLATE 42: DECUBITAL SORES

The roundish red areas over both carpi and the point of the sternum are crusted over areas of ulceration that have resulted from prolonged abnormal pressure to these areas. In this case, a central nervous system lesion was suspected to have made the animal unable to stand on its forelimbs. The pig was able to push itself around with its hind legs. Decubital sores are common in any "downer" animal over their bony prominences. Surprisingly, young piglets with this "front limb paresis" syndrome often get better with time and without specific therapy. A defect in nervous tissue maturation is suspect.





PLATE 43: TAIL AMPUTATION

The tail was partially amputated and has healed. Two abscesses formed in the caudal vertebral canal, probably from an ascending infection. These caused spinal cord compression which finally resulted in posterior paralysis. As a result of the paralysis, the pig tried to ambulate with its front limbs dragging its hindquarters which caused the scabby lesions (decubital sores) on the tail stump, hock and tarsus of the hind legs. Many suspect that tailbiting in piglets is the most likely cause for loss of the tail or portions thereof.

PLATE 44: EAR NOTCH INFECTIONS

Several of these man made ear notches have necrotic debris attached to them. The right ear is swollen and dark with congestion from an apparently spreading inflammation from the infected ear notch. On some farms where such an identification mark is used without some control of sepsis, this lesion serves as a likely "portal of entry" for septicemia causing organisms. Any of numerous organisms may be isolated from such a lesion.



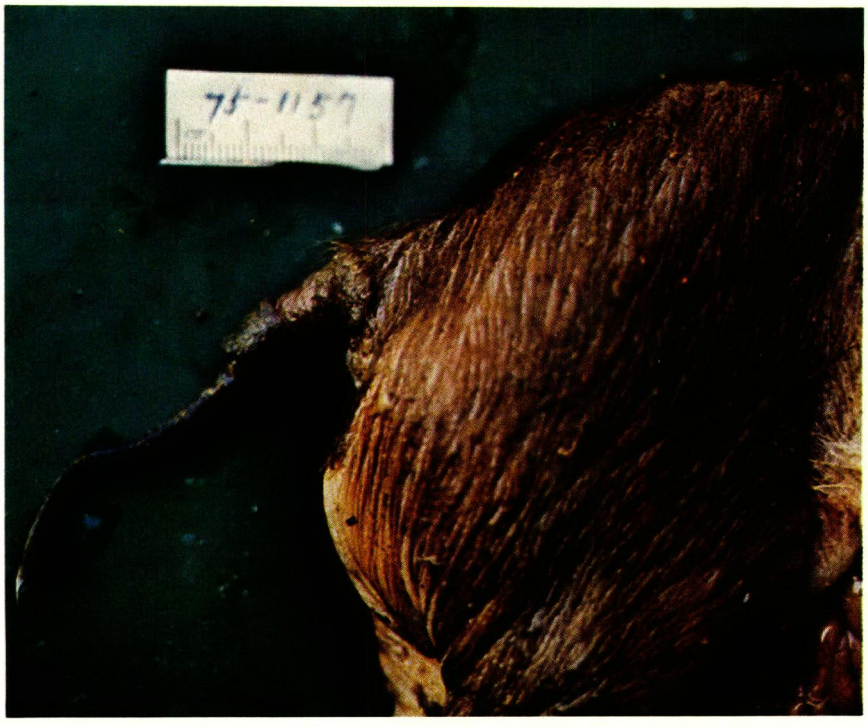

PLATE 45: TAIL NECROSIS

Almost three fourths of this piglet's tail is rigid and dry with much of the skin having sloughed as a result of the dry gangrene that affected it. The denuded portion will subsequently slough or be pulled off. Some consider this to be a result of tail biting while others suggest that S. necrophorus infection, spreading cranially from the tip, is at fault. Even a physiological factor as a heat regulatory mechanism causing vasoconstriction in newborn animals may be involved as is suspected in "ringtail" in rats. This lesion also may serve as a "portal of entry" for any septicemia causing microorganisms.

PLATE 46: ULCERATIVE DERMATITIS

This is an early stage lesion of a suspected spirochete granuloma and is located on the lateral hock. It has an irregular outline with a raw central portion. The edges are slightly thickened. In later stages, the whole area may swell with chronic purulent inflammation and pus may be expressed. Some cases reveal the organisms when smears of the tissue are stained with silver stains. While spirochetes are usually suspect, there is some doubt that they are primary, as in most cases a predisposing traumatic injury is usually noticed.

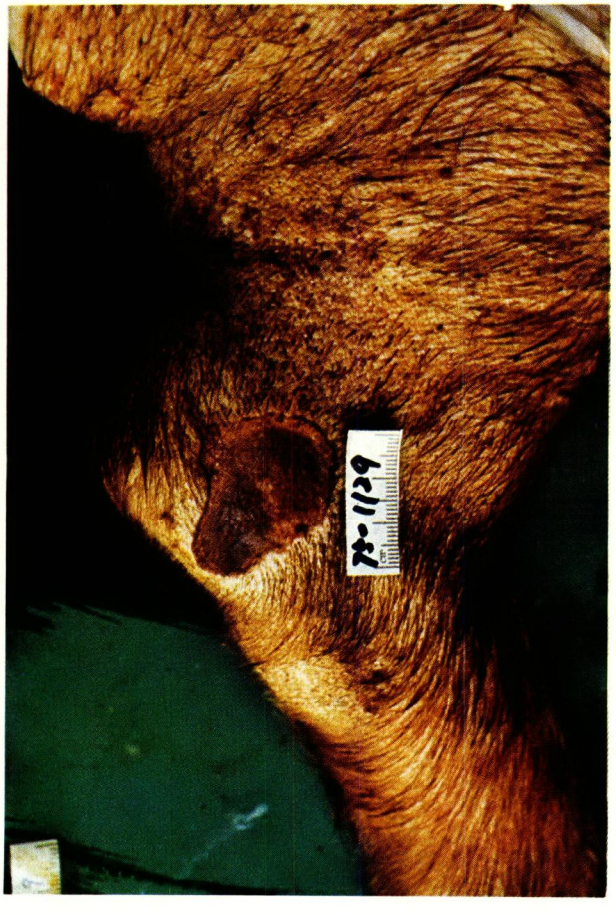



PLATE 47: SPIROCHETAL GRANULOMA

The large, relatively hairless area in this boars upper lip has several small surface openings from which a dark, foul smelling purulent debris can be expressed. A large pocket of similar purulent debris was present in its left jaw angle as well. Some, not all, of these can be shown to have spirochaetes associated with them by the use of silver stains on fresh smears of affected tissue. The true role of the spirochete is not known. C. pyogenes and S. necrophorus are also isolated in such cases. These lesions may be found associated with wounds of any type.

PLATE 48: SPIROCHETAL GRANULOMA

This large area of chronically infected granulation tissue has many pockets of dark, purulent, foul smelling pus which communicate with each other and openings (fistulae) in the skin through which pus can be expressed. A moderate amount of blood was admixed with the purulent debris and is the cause of the greyish blue background (pseudomelanosis) of the reactive connective tissue in the lesion. While many organisms may be isolated including C. pyogenes and S. necrophorus, there are some who show that spirochetes may be seen in silver stains of early lesions. This lesion about the upper gum is a common location, but they may be seen associated with any wound including decubital ulcers over bony prominences.

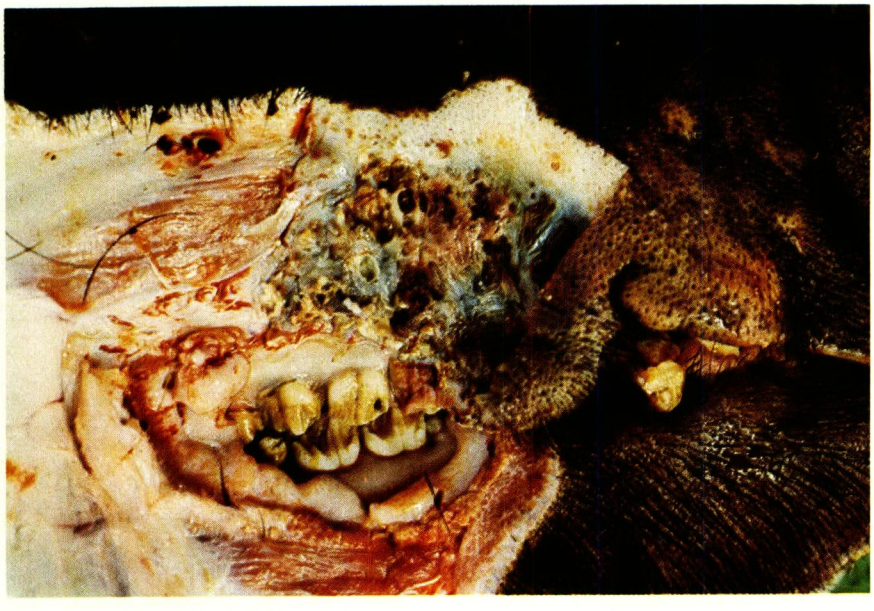

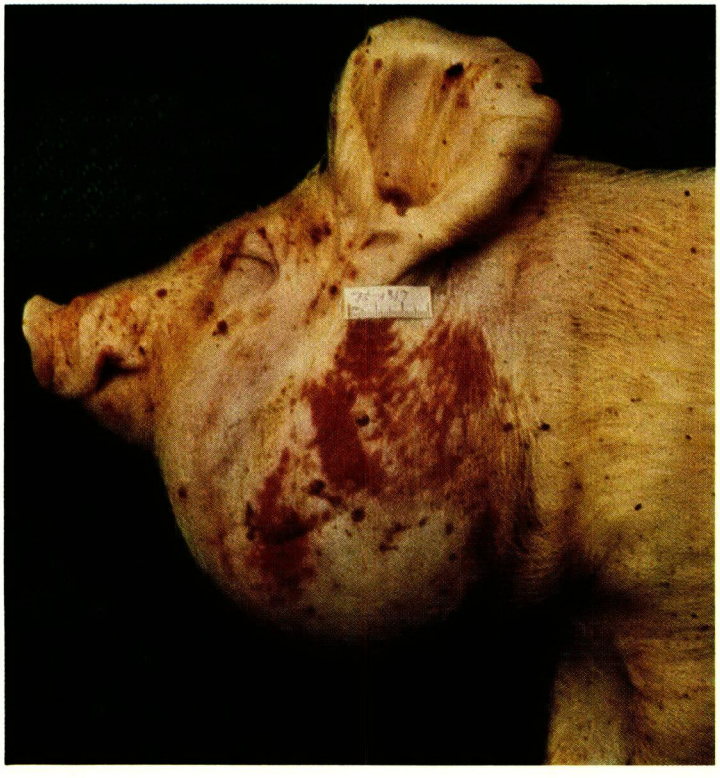

PLATE 49: JAW ABSCESSATION

The enlarged mass on the left jaw of this pig is soft and fluctuating but not warm. An abscess or a dilated salivary gland duct cyst (ranula) was suspected. When incised, a thick creamy pus was found in a 5mm. thick connective tissue walled pocket. C. pyogenes was isolated, but any one of numerous organisms including Streptococcus spp. may have been found. It is thought that such a lesion in this location develops in a lymph node draining an infection of the oral cavity, such as in a tonsil.

PLATE 50: MYCOTIC DERMATITIS

The discrete, dull, grey foci scattered on this aborted calf's skin are foci of Aspergillus spp. growth. There are similar lesions on the white skin but they are more difficult to see. Mycotic abortion cases such as this are one of the common causes of abortion in cattle. More often found however, is the mycotic growth in the placenta which becomes thickened, dull and less vascular as the mold has a tendency to cause thrombosis. Mucor spp. makes a similar lesion.

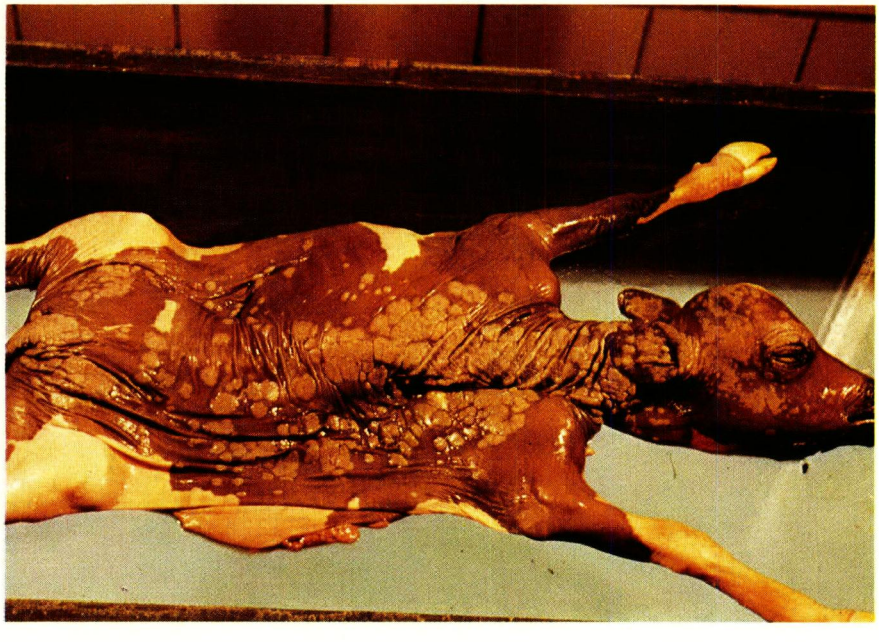



PLATE 51: PARASITIC DERMATITIS

This generalized form of dry scabby dermatitis is an example of sarcoptic mange. This usually causes the pig much discomfort and is to be found in almost any size pig and in many other species. Numerous negative skin scrapings should be made, looking for the mites, before ruling out this diagnosis. Pigs with exudative epidermitis (greasy pig disease) usually have a darker, more moist and greasy appearing lesion. Pigs affected with parakeratosis usually have the thickened skin ventrally.

PLATE 52: PARASITIC DERMATITIS

Slight keratin excess is seen on the surface and a section of a mange mite, probably Sarcoptes spp, with a spiked cuticle and amorphous internal structure is seen within the epithelial layer itself. The space between the parasite section and the basal epithelium is an artefact. Sometimes many sections of skin must be examined to find a single organism. A variable number of round cells often including eosinophils may be found in the underlying tissues.



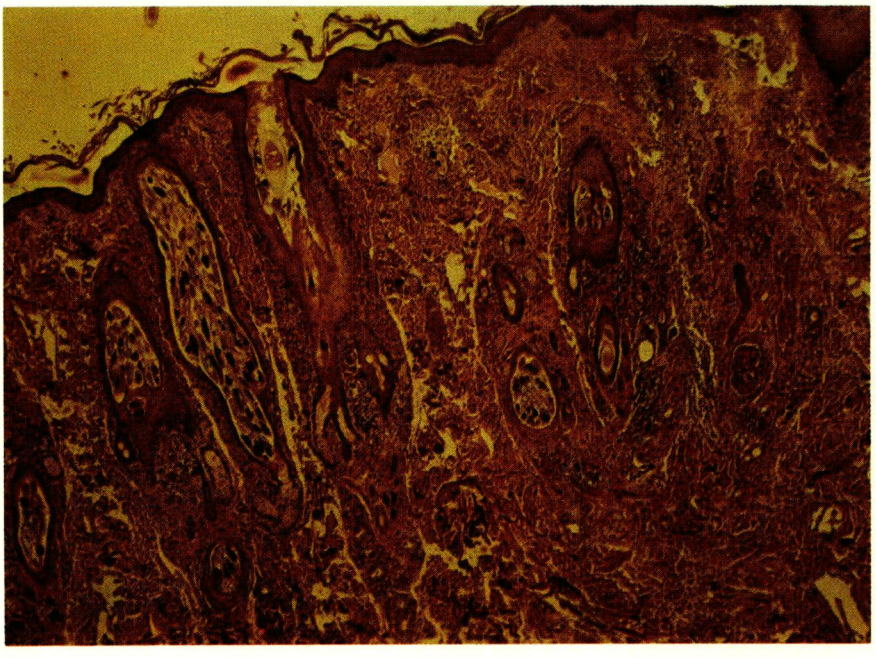

PLATE 53: DEMODECTIC DERMATITIS (DEMODECTIC MANGE)

The hair follicles are dilated with many sections of the follicular mite, Demodex folliculorum. Usually only a few or none may be found on the surface, which necessitates multiple, rather deep scrapings to make the diagnosis clinically. These are found in almost all species. A few foci of chronic inflammatory cells and pieces of parasite are scattered in the dermis. These probably are the result of trauma to the skin rupturing the follicles and pushing the mites and debris into the stroma. Regional lymph nodes show reactive hypertrophy and hyperplasia. Sections of parasites may be found in the regional nodes and even in the lung from lymphatic spread.

PLATE 54: SQUAMOUS CELL CARCINOMA

A piece of ear cartilage runs diagonally at one side of this picture. On both sides of it are many islands, both small and large, of stratified squamous cell carcinoma. The basally oriented cells are more basophilic than the superficially located cells. The pinker superficial cells with their keratin content are sloughing and forming the characteristic epithelial pearls. Several other tumors such as the anal gland adenoma also form epithelial pearls.

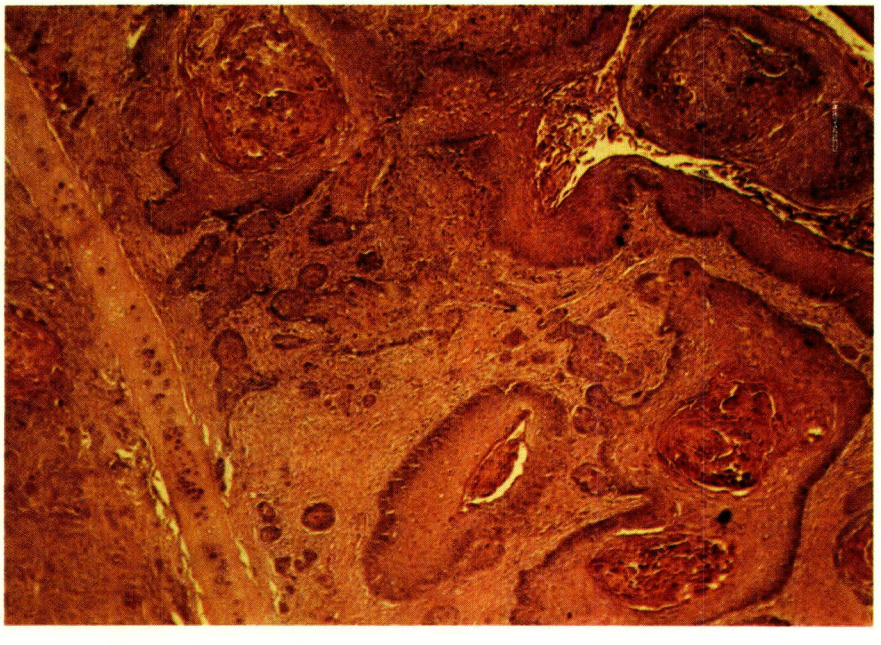



PLATE 55: FRONTAL SINUSES

These are three representative skulls of various aged pigs to show the normal variations of frontal sinus development and skull bone thickness. Only a small sinus is in front of the cranial vault in the smallest and youngest pig's skull with the relatively thin frontal bone. These enlarge many times to the size of the largest and oldest pig's skull shown here. This large skull is from a 4 yr. old sow.

PLATE 56: LIMB ANOMALY

In this piglet, one hindleg is absent and the one remaining is malformed as is part of the pelvis. The forelimbs are normal. The photogaphed defect may represent a combination of sirenomelus (fusion of both hind limbs) with a pelvic deformity. In general, when one anomaly is found, others should be looked for even in other systems. This multiplicity of anomalies is especially apropos when considering microphthalmia as this eye defect often is associated with a wry tail and heart anomalies. There is a whole group of musculoskeletal anomalies that are best described after the bones have been cleaned or cleared and stained preferentially to demonstrate the defects. Alizarin Red S is commonly used in bone staining techniques.

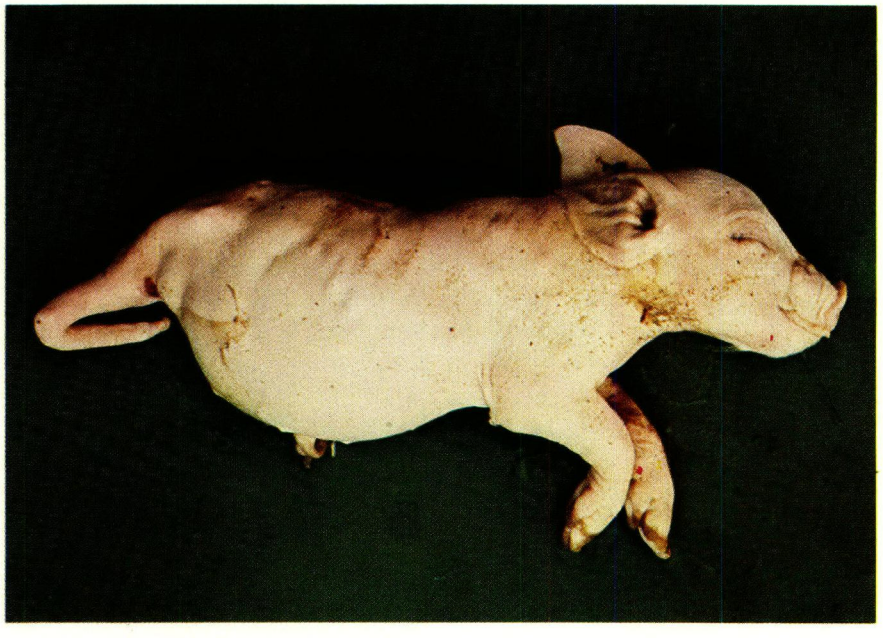

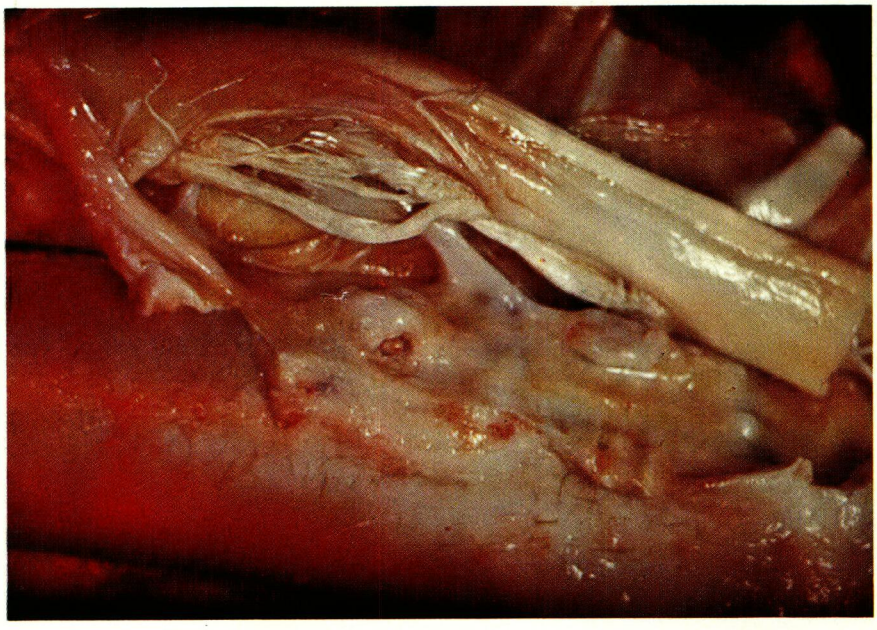

PLATE 57: MULTIPLE CARTILAGENOUS EXOSTOSES

This young foal had multiple knobby masses of bony material that protruded from the surface of many of its leg bones and caused much traumatic damage to the soft tissues above them. The animal was killed because of the lameness produced. The irregular exostoses are seen here on a metacarpal bone and have caused mechanical disruption of the tendons above them. Some believe these to be embryologically misplaced epiphyseal plate tissue which continues to produce cartilage. It is also suggested here that it may be a defect of periosteum in which the fetal perichondrium was not replaced in patches by the periosteum.

PLATE 58: MULTIPLE CARTILAGENOUS EXOSTOSES

These two pieces of long bone which have been cross sectioned through their diaphyses show several irregular outgrowths of bone which have a grey, shiny mass near their apex or just to one side of it. These grey foci are pieces of growing cartilage under which the normal spongy bone is also growing and pushing outward to form the exostoses. These are considered to be caused by misplaced pieces of epiphyses which continue to function and produce cartilage. Although most cases are found as sporadic ones, there are some that are known to be hereditary.





PLATE 59: PROTRUDING WING OF THE ORBITAL SPHENOID BONE

The half round, curved piece of bone in the anterior half of the cranial vault is the wing of the orbital sphenoid bone protruding medially which caused a distinct indentation of the cerebral hemisphere. It is a bilaterally symmetrical lesion. This lesion is seen in the majority of cases of dwarfism, especially in calves, and is a useful diagnostic lesion as other lesions in the dwarf are usually lacking. Many dwarfs have a clinical history of bloating.

PLATE 60: BRACHYGNATHIA AND OSTEOPETROSIS

The lower jaw is markedly shortened (brachygnathia) and the long bone pictured has no marrow cavity, as what should be marrow cavity is occupied by bone (osteopetrosis). These are commonly associated congenital anomalies. This is a foal with the disease, but it is mostly seen in certain breeds of beef cattle. All the long bones in this foal had this lesion. Most cases are associated with anemia because of the lack of bone marrow for hematopoiesis.





PLATE 61: CERVICAL VERTEBRA DISLOCATION

The jaws of this pig are still skin covered and some of the pleura covered ribs are seen at the other side of the picture. Just behind the head is a marked amount of hemorrhage. In this area, the soft tissues were torn by trauma allowing for excessive movement of the head before and during the necropsy. Several of the associated lymph nodes are blood filled. The history also suggested this possibility, but caution should be used in such cases as, while the blood is still fluid, one can create this "lesion" artificially by roughly handling the carcass after death.

PLATE 62: FEMORAL FRACTURE AND ABSCESSATION

The major mass in this picture is the granulation tissue response about the fracture site at the distal third of the femur. Much blood and dense white tissue, both fibrous and cartilagenous, is seen in the deeper tissues. Deeper to the pale white tissue is clotted blood, fibrin, and purulent debris which is not easily seen here. In the more distal portion of the leg, much edema is present. This pig had soft bones from a in-balanced diet with subsequent fracture, some callus formation, and finally infection. Maceration (cleaning) of the bones revealed no erosion of bone tissue to suggest prior infection.



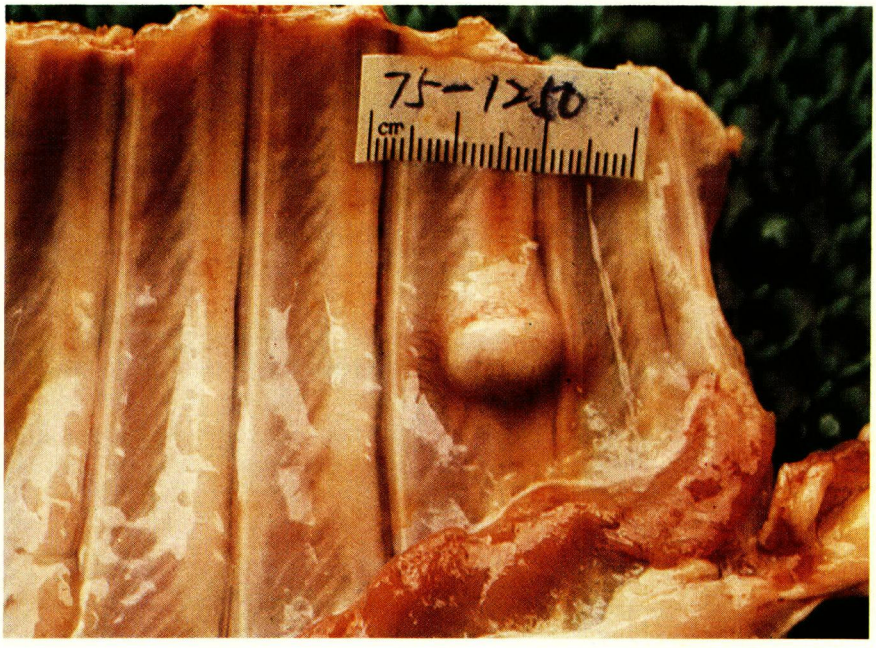

PLATE 63: FRACTURE CALLUS

This hard, firm lump in the midshaft of the rib is the response to a fractured rib. Often these are multiple and most are found as an incidental finding during the necropsy. Trauma at birth or shortly after is the usual cause.

PLATE 64: VERTERBAL FRACTURE

The last lumbar vertebra has been fractured by compression and pushed ventrally. Some edema and congestion is present in the cauda equina of the spinal cord which probably accounts for the posterior paresis shown by this pig clinically. Its bladder was greatly dilated with urine and the ribs were cut easier than normal on removal. A well developed line of osteodystrophy was seen at the costochondral junction of the ribs. A metabolic imbalance of vitamins and minerals is the best suspected cause, but any disorder of this nature can be involved.





PLATE 65: HYPERTROPHIC PULMONARY OSTEOARTHROPATHY (HYPERTROPHIC OSTEODYSTROPHY)

There are roughened proliferations of periosteal bone (hyperostoses, exostoses) about the proximal half of each first phalanx shown here and about the distal end of only one large metacarpal bone of this horse. Most other long bones were affected. The periosteal bone proliferation affects most of the long bones near either end, but does not interfere with the joints proper which suggests that the name may be a slight misnomer. Most of these lesions are associated with a thoracic cavity lesion such as a lung or esophageal abscess or tumor, but they are also related to a urinary bladder tumor in a few instances. The mechanism to explain the ability of a lung or urinary bladder mass to cause this is not known, but a neurovascular effect is considered the probable answer. Some remission of the hyperostosis is seen with surgical removal of the causative mass if possible. As this is a generalized effect on the axial skeleton, it is difficult to explain the unilateral lesion in this case. A few instances of this lesion as a single localized lesion are associated with a local interference of blood supply to the area.

PLATE 66: NUTRITIONAL SECONDARY HYPERPARATHYROIDISM

The upper jaws of this pet opossum are greatly thickened and the teeth are spread apart as a result (not seen). This has given this animal a wide face compared to the thin face of a normal opossum. The cause of this is a nutritional imbalance brought on by the almost exclusive meat diet. It is suggested that the meat with its extraordinary high level of phosphorus caused the calcium phosphorus imbalance which stimulated parathyroid hormone production which in turn resulted in loss of calcium from and an increase of connective tissue in the jaw bones (osteodystrophia fibrosa). The jaws of this animal had almost returned to normal after one year on a proper diet. Although somewhat similar in effect, this problem is to be differentiated from that caused by renal failure (renal rickets).



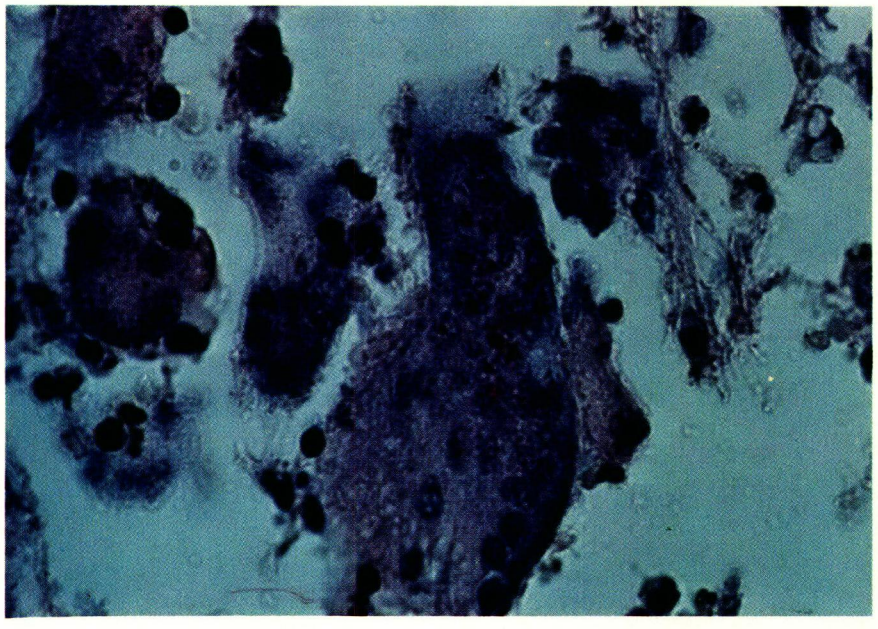

PLATE 67: ACID FAST INCLUSIONS

This is an osteoclast from the bone of a pig that died with lead poisoning. The tissue has been stained with an acid fast (A F) stain to demonstrate these red granules. They are also found in renal tubule cells, hepatic cord cells and some endothelial cells, especially in the brain.

PLATE 68: OSTEODYSTROPHY

The three cut surfaces of costochondral junctions all show the slight enlargement of this zone and the relatively pale zone (osteodystrophy) in the region of most marked swelling just above the cartilage. A pale zone in this area is quite common in newborn animals, but it is not present in animals several weeks old or older except as evidence of an abnormal bone growth. Almost all of the metabolic and nutritional bone diseases, including the mineral/vitamin imbalance problems such as rickets, may show this lesion. It should be noted that one of the more common causes of rickets is hypervitaminosis A as vitamin A is anti-vitamin D. This relationship should also be considered in cases of "grass tetany" and "winter tetany" in sheep and cattle. The excess Vit A in grass tetany is understood to come from the carotene of the ingested grass. In winter tetany, which affects beef cattle nursing large calves, it is postulated that mineral and vitamin loss in the milk along with ample Vit A stores in the cow may be involved.



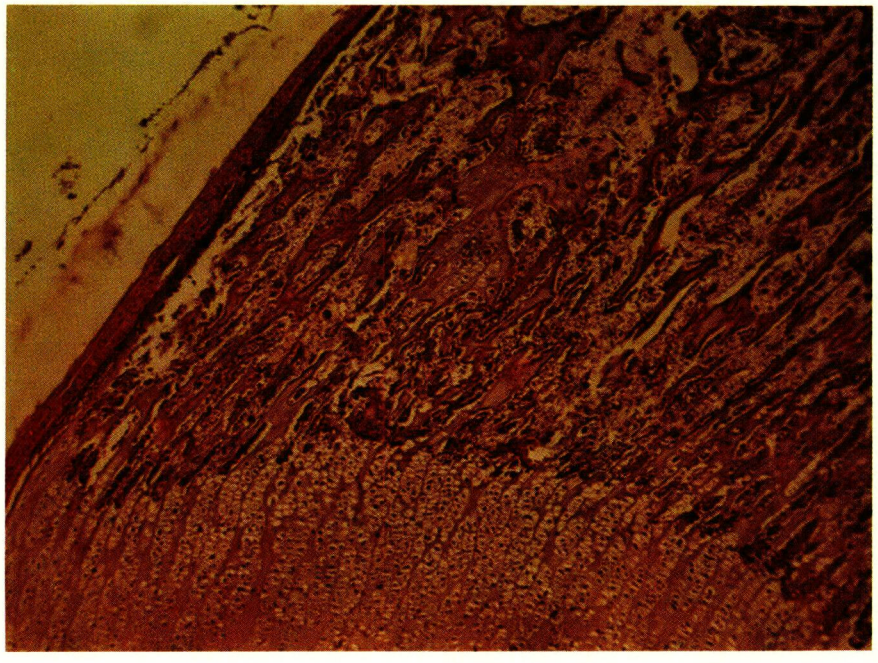

PLATE 69: OSTEODYSTROPHY

The cortical bone is quite thin as most of the bone spicules in the epiphysis and several irregular islands of cartilage still remain abnormally separate from the epiphyseal plate. The bone spicules in the diaphysis are crooked and in most cases, but not seen here, there are more neutrophils than normal. A vitamin/mineral imbalance is usually at fault.

PLATE 69A: OSTEOPOROSIS

This epiphyseal plate of the humerus is markedly reduced in thickness. In contrast, the resting cartilage is extensively thickened. Note also the short and irregular hypertrophied cartilage and greatly reduced amount of bone matrix. Osteoblasts are scanty, small and flattened. The amount of change depends on the severity of the deficiency or degree of disordered mineral metabalism. The alteration is nonspecific because protein deficiency, vitamins B and C deficiency and other factors may interfere with osteoblast activity and result in these changes.





PLATE 70: FOCAL OSTEOSCLEROSIS

This proximal humeral metaphysis of this 40 Kg. pig shows a heavily calcified matrix in the distal edge of epiphyseal plate and the primary spongiosa which shows a heavy opacity to X-rays (lead line). Apparently, diseases such as heavy metal poisoning (lead, bismuth, phosphorus, etc.), malnutrition and infectious diseases, which are capable of retarding growth, may induce these changes.

PLATE 71: OSTEOMYELITIS

The distal epiphyseal region of this femur shows several yellowish, irregular areas filled with soft, curd like pus. In one area, the infection has perforated into the joint cavity. No skin lesion or penetrating wound was found or suspected so it is considered a hematogenous infection. The epiphyses of young animals is a common location for osteomyelitis. This is explained in part by the fact that their epiphyses are nourished by "end artery" vessels passing through the plate and thus are more subject to septic embolism. These vessels are closed off by epiphyseal plate closure in the adult which rarely get this lesion, but in the aged, when the vessels again perforate the plate and act as "end arteries", they are prone to the lesion once more.

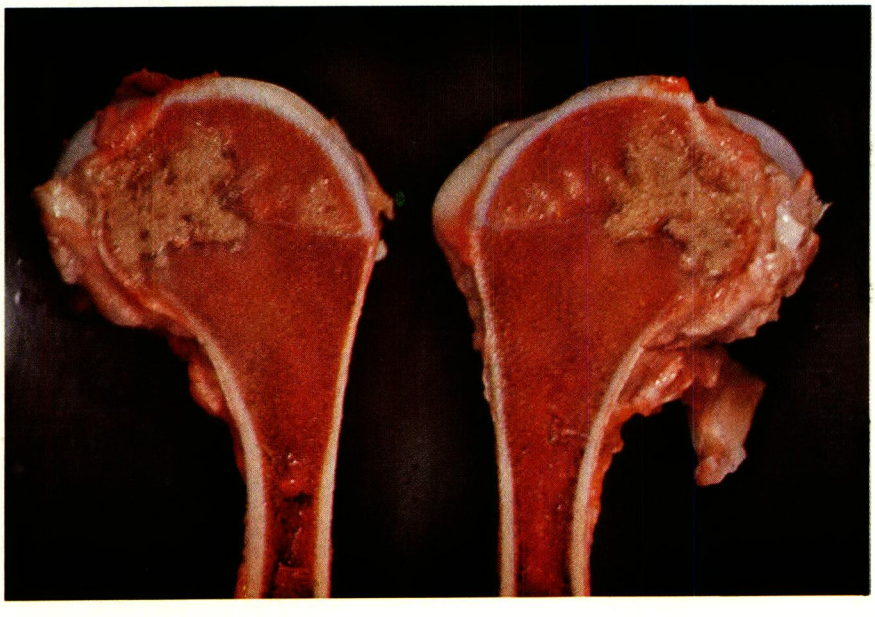



PLATE 72: SEQUESTRATION

All four cannon bones of this several weeks old foal have been cut longitudinally to show the necrotic pieces of bone (sequestra) separated from the normal bone at their distal epiphyseal plate region. These necrotic pieces of bone are recognized by their dull, yellowish appearance with a red zone of vascular response separating them from the normal bone. The bones with the three largest sequestra also have another area of infarction and beginning sequestration at the very distal end of the bone just under the articular cartilage. Although no cause was established for these, it is thought that a vascular problem was at fault. Histologically, much necrosis was evident, but no evidence of infection was seen.

PLATE 73: BONE MARROW INFARCTION

One normal bone is shown for comparison. The other bones all show yellowish dull areas in the marrow space, especially in the spongy bone and under the articular cartilages. These are for the most part infarctions of the spongy bone and some have a faint zone of inflammation about them. In the marrow cavity of the three longest bones can be seen shiny, yellowish soft, fatty tissue like masses of neoplastic lymphoid cells which also make up much of the infarcted areas. These bones are from a young calf with lymphomatosis, but similar lesions can be seen in most species.





PLATE 74: SEROUS ATROPHY OF FAT (MUCOID DEGENERATION)

The bone marrow cavity is filled with a gelatinous, watery material, serous atrophy of fat, instead of the normal fat marrow, in this starved, adult animal. Some slightly red marrow is seen in several scattered areas just under the cortical bone along the sides of the marrow cavity. The replacement of bone marrow fat by serous atrophy of fat is a chronic process and suggests that the animal has been malnourished for a prolonged period of time. The exact time is difficult to establish in most cases. One would have to know how much of each nutrient was deficient and how much the animal had in its body stores at the beginning of the starvation period. The bone marrow is mostly red in young animals because it is actively producing blood cells, but as the animal ages, the red marrow is replaced by fat. In an adult animal that is anemic for a period of time, the bone marrow will develop islands of red marrow again for hematopoiesis as it did in this case. This can be termed compensatory hyperplasia of bone marrow.

PLATE 75: FIBRINOUS ARTHRITIS

In this acute form of arthritis, several yellowish clumps of fibrin are seen in the open joint cavity. No hemorrhage, edema or cartilage lesion is seen in this case but in more chronic forms they may be found. Such a lesion is not diagnostic except for suggesting that a septicemic disease such as polyserositis is or has been present. Only a culture can identify the causative agent.



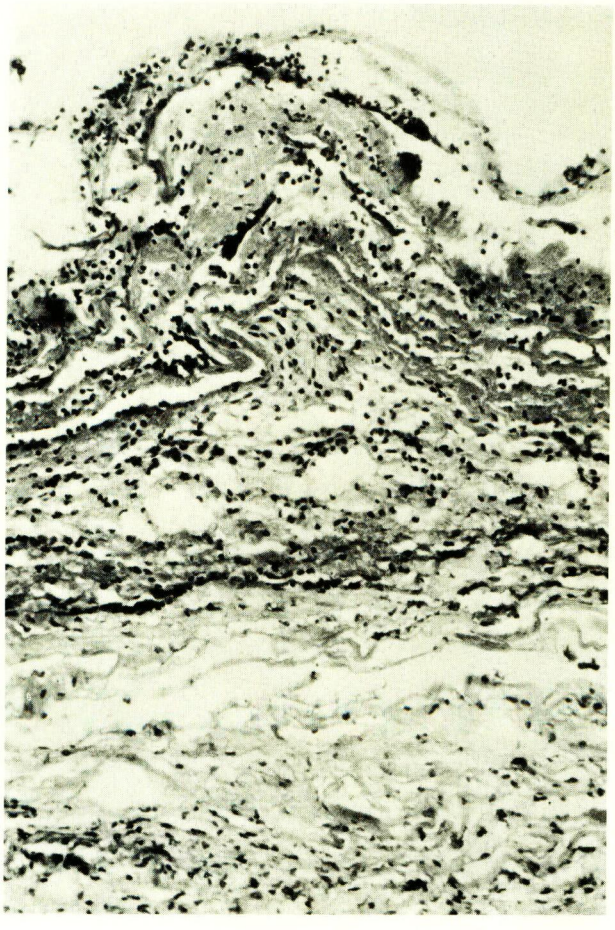

PLATE 76: SEROFIBRINOUS ARTHRITIS

The loose connective tissue (synovial membrane) of the joint has a few inflammatory cells scattered in it. On the surface is a layering of fibrin and neutrophils with dark masses of debris and possibly clumps of bacteria. A culture is necessary for agent identification.

PLATE 77: CHRONIC SUPPURATIVE ARTHRITIS

In this fattening pig's shoulder joint, there is a marked amount of firm, organizing fibrin, and the capsule of the joint is markedly thickened with connective (fibrous) tissue. One can call this an active chronic infection because the fibrin indicates that it is active and the connective tissue indicates that it is chronic. Surprisingly, little articular lesion per se is present.

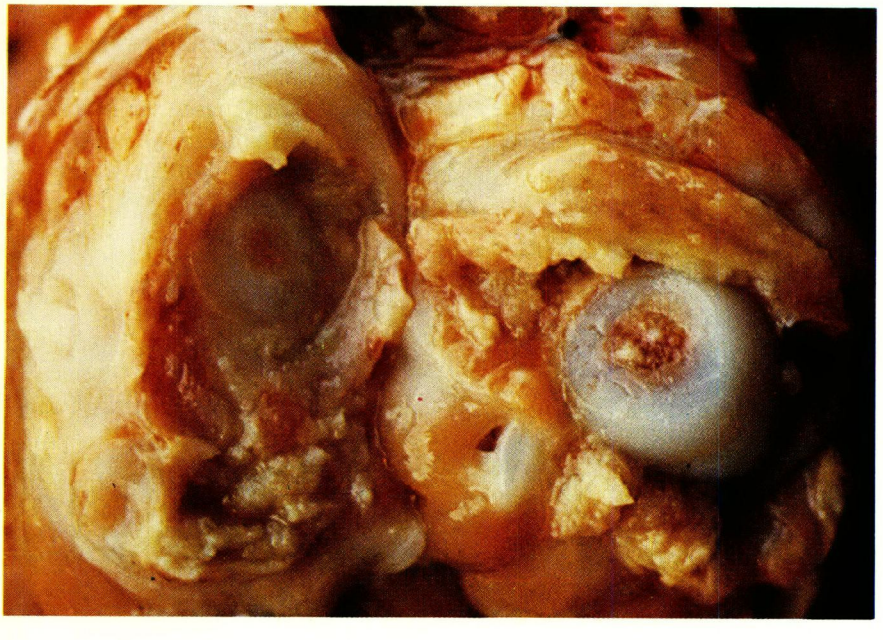

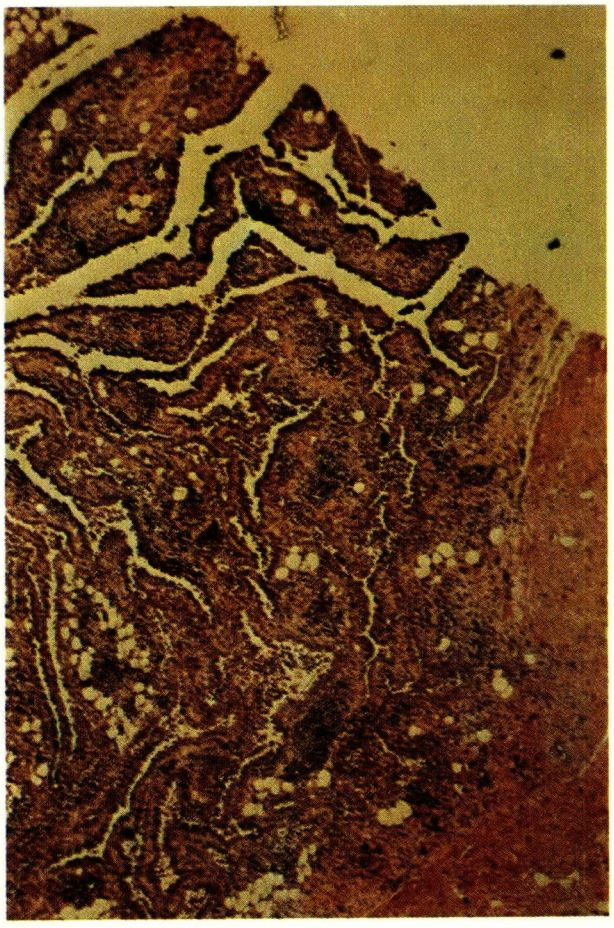

PLATE 78: CHRONIC ARTHRITIS

A well marked synovial proliferation into finger like projections with an almost glandular mesothelium is seen here. Many chronic inflammatory cells are present in the villi along with some fat cells appearing as clear vacuoles. Numerous clumps of neutrophils and chronic inflammatory cells are in the joint spaces between these projections of synovial tissue. E. rhusiopathiae was isolated, but many other organisms that can and do cause chronic arthritis may make a similar lesion.

PLATE 79: FOOT ROT (SPIROCHETAL INFECTION)

Both feet are swollen with one foot having lost the nail of one toe. The entry wounds have temporarily dried over at this time. Sometimes these lesions are located over bony prominences or associated with skin wounds as from castration. No proof that a spirochete is primary has been forthcoming, but they are often seen in smears or other preparations (not cultures) of the area.



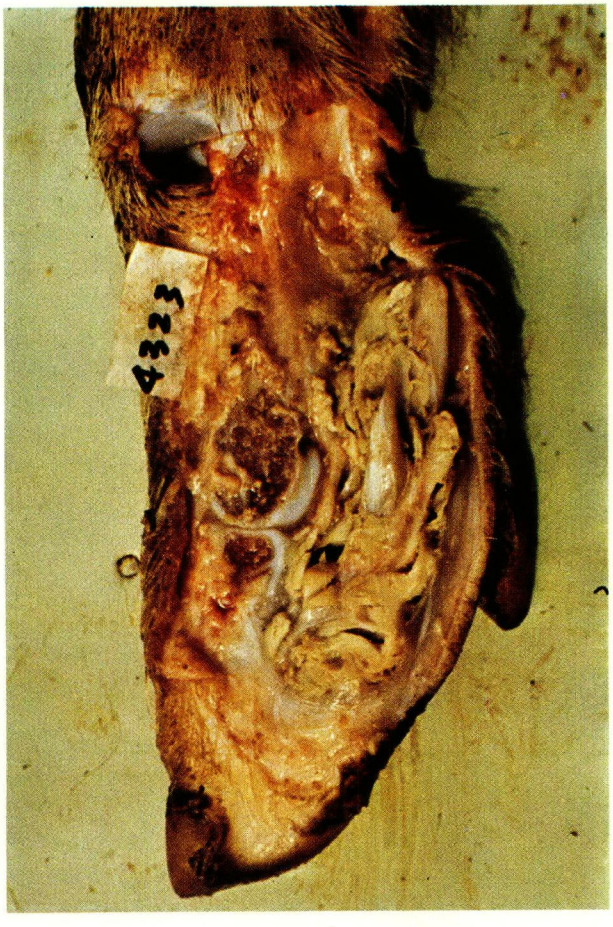

PLATE 80: FOOT ROT (SPIROCHETAL INFECTION)

This opened lesion shows an infected foot with a marked fibrinous, purulent exudate in the tendon sheaths and other soft tissues. The joint and joint cavities of the digit are not affected. Various organisms may be isolated from such a lesion if open to the surface. Spirochetes may be seen in some cases with special silver stain preparations.

PLATE 81: JOINT ABSCESSATION

This enlarged and lumpy area of the right shoulder joint is due to abscessation in the tissues around and in the joint proper. C. pyogenes was isolated, but any of the pus forming organisms could have been involved. This case is further complicated by the fact that this humerus had a nonhealing (false joint) fracture that was also infected. All of this pig's bones were relatively soft from a minerally unbalanced diet. It is probable that the fracture came first and infection which spread to the joint second.





PLATE 82: SPONDYLOSIS

The large spicules and plates of bone that are seen bridging the intervertebral space of the last lumbar vertebra and sacrum are classified as a noninflammatory degeneration (spondylosis) of the vertebral column with ankylosis. This is to be differentiated from spondylitis which is an inflammatory process of the vertbrae. These are quite common in older animals especially old bulls and dogs. Nutrition may play a most important role in their production. This specimen came from a two year old, cage reared, Beagle dog. In the older animals, the lesions are usually more extensive and fuse the vertebrae (ankylosis) more solidly than shown here.

PLATE 83: COSTOCHONDRAL JOINT INFECTION

These six joints show a greenish yellow purulent debris with a relative thickening of the surrounding soft tissues. This piglet had an open lesion at the base of the tail from suspected tail biting, but any wound can serve as the portal of entry and almost any organism may be cultured from the lesion. Of course, the portal of entry for some of these organisms may have long since closed and not be found at necropsy.



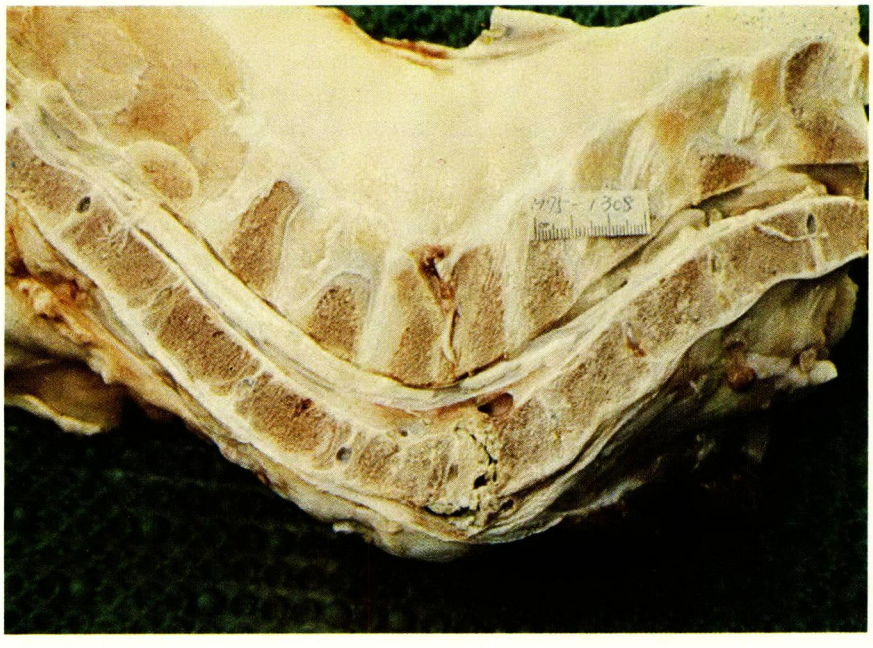

PLATE 84: VERTEBRAL ABSCESS WITH CORD COMPRESSION AND LORDOSIS

The body of L2 has been replaced by a greenish pocket of pus and as a result, has almost completely compressed the vertebral column in this location. This has allowed the spinal column to bend ventrally at this site giving a distinct swaybacked (lordosis) appearance to the back. Any bacteremia could have allowed the bacteria to settle here and produce the abscess, but C. pyogenes was isolated from this case. This can also be considered an example of spondylitis.

PLATE 85: OSTEOGENIC SARCOMA

This highly cellular neoplasm came from the tail of a cow. Most of the cells are small and uniform in appearance, but there are many multinucleate giant cells scattered throughout the mass. In association with these giant cells, apparently osteoblastic, is the pink homogeneous deposition of osteoid. The osteoid is becoming mineralized in many scattered foci to form bone. The differentiation of the malignant form of this neoplasm from its benign form is not always easy. In many tumors of this type, there may be islands of neoplastic cartilage and other neoplastic mesodermal tissue. These other tissues may even make up the bulk of the whole tumor, but as a neoplasm should be named after its most mature tissue, the bone classification should have priority. In the same vein and especially to aid the clinician, a tumor of mixed benign and malignant components should be classed with the most malignant component.

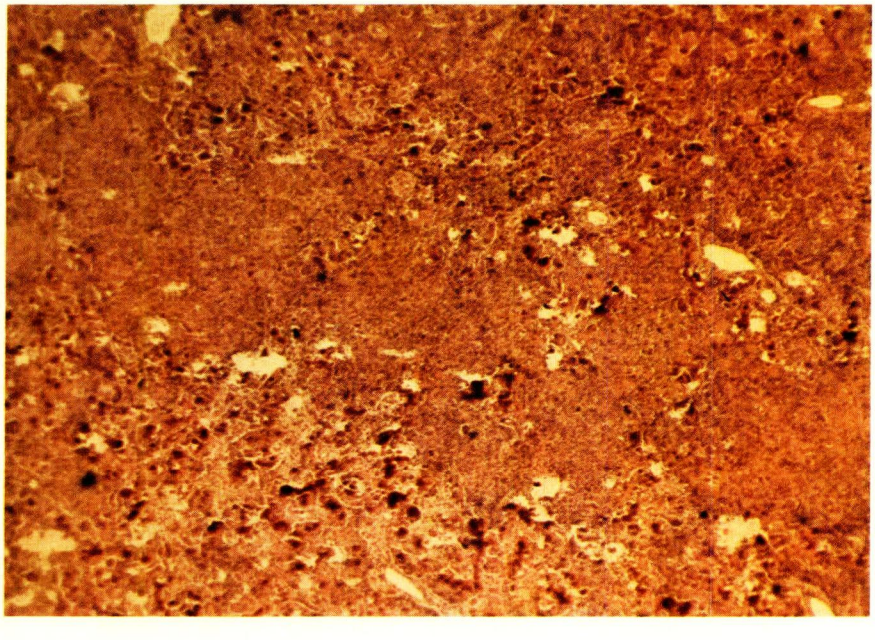

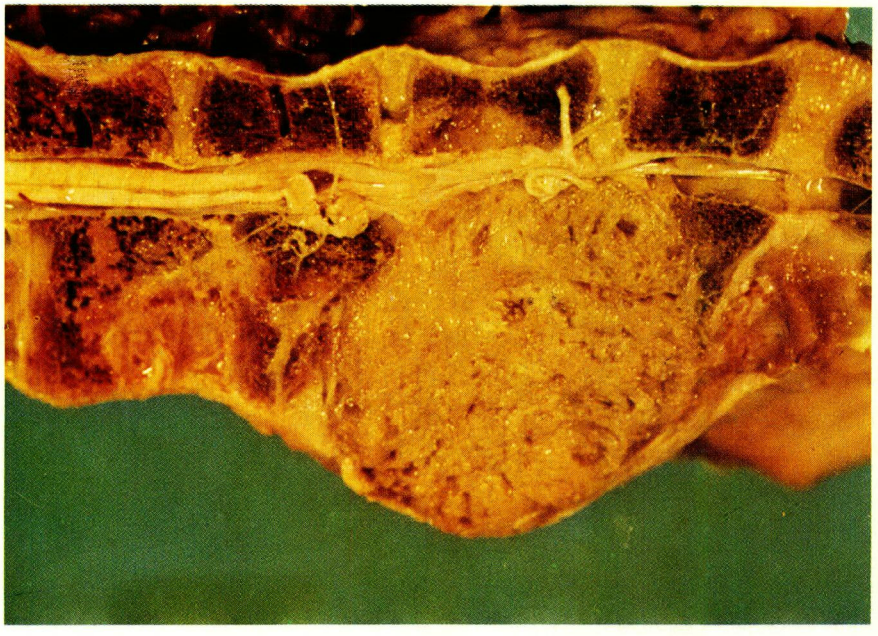

PLATE 86: VERTEBRAL NEOPLASIA

Although this relatively well defined mass is indeed a metastatic squamous cell carcinoma from the mammary gland, it should be called just a "mass" grossly as it would be difficult to differentiate it from an abscess. The pockets seen actually exuded a yellow, opaque, cloudy debris when cut and expressed. This material was epithelial and keratin debris. Of course other metastatic foci and a known primary mass would help in the differential.

PLATE 87: UMBILICAL HERNIA

The large ventral mass is filled with omentum and a portion of small intestine (hernial content). These have protruded out through an opening (hernial ring) at the umbilicus. The skin, subcutaneous tissues and peritoneum make up the hernial wall. Most of these are congenital (associated with birth), and most are thought to be genetic (related to hereditary factors) in origin. In male pigs, the normal preputial diverticulum when filled with urine is often mistaken for this lesion.





PLATE 88: LEFT INGUINAL HERNIA

The large mass seen on external examination was eccentrically placed on the left side and no skin wound was found. The sac was the left scrotal cavity and the content, which could be almost any of the movable viscera, was the urinary bladder and a major segment of the ileum. A post castration infection (scirrhous cord) may look like this externally. It should be noted that the ileum is more likely to be involved than other intestine in displacements of any type in the abdomen.

PLATE 89: LEFT INGUINAL HERNIA

The large curved mass in the picture is the hernia in the left scrotal sac, above it can be seen the fluid filled ileum entering the inguinal ring which serves as the hernial ring. A much smaller diameter portion of ileum is coming out of the hernia. The urinary bladder fundus is also part of the hernial content but it is not seen in this picture. A congenitally large inguinal ring or an abnormally relaxed one may allow this to develop. It is known to be genetic in some animals.

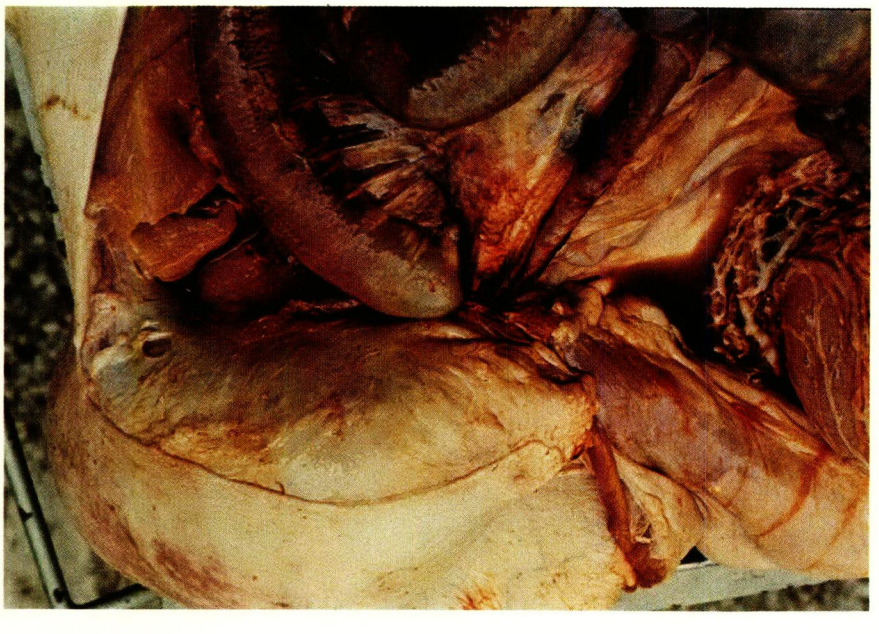

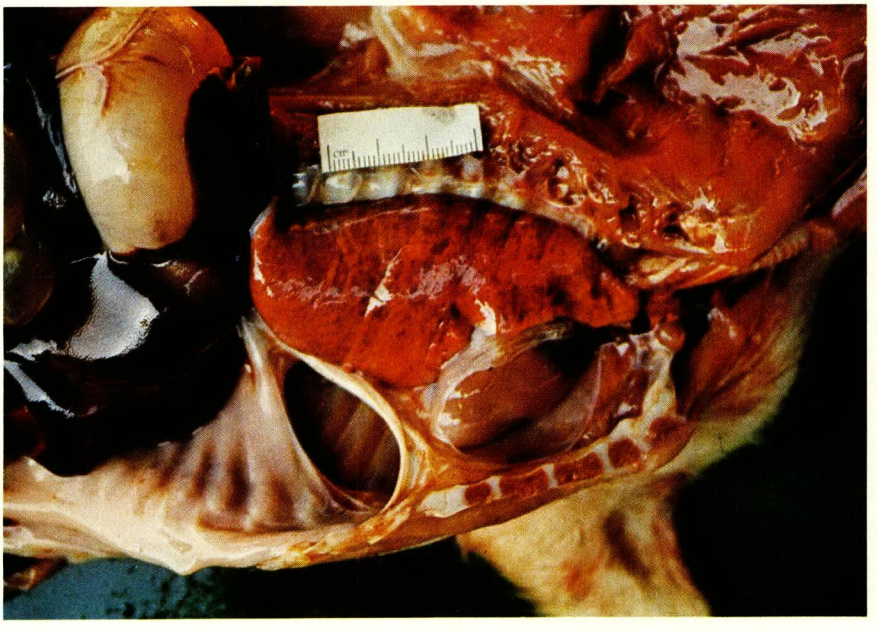

PLATE 90: CONGENITAL DIAPHRAGMATIC HERNIA

This day old piglet has a dorsoventral, three centimeter opening in the ventral portion of the diaphragm involving both the muscular periphery and tendinous center. The right edge is slightly thickened. The pericardial sac was opened at the time of necropsy. This itself was not a fatal lesion as the piglet died from septicemia. In other such cases, the abdominal viscera commonly pushes forward to become the hernial content and will physically impair heart and lung function. Liver lobes often go through, become static there and finally atrophy with time.

PLATE 91: CONGENITAL DIAPHRAGMATIC HERNIA

The pericardium has been cut open and is held caudally to show the herniated portion of liver projecting into the heart sac along with some edematous omentum. The heart has a thickened, opaque epicardium. While some excess connective tissue is around the hernial ring (not shown here) it is thought that it just represents a chronic stimulation of the fibrous tissue by diaphragm and heart action in moving the hernial content. When seen in newborn pigs with the thickened well healed hernial ring, one should consider it a congenital hernia, but when found in an older animal trauma must also be considered.

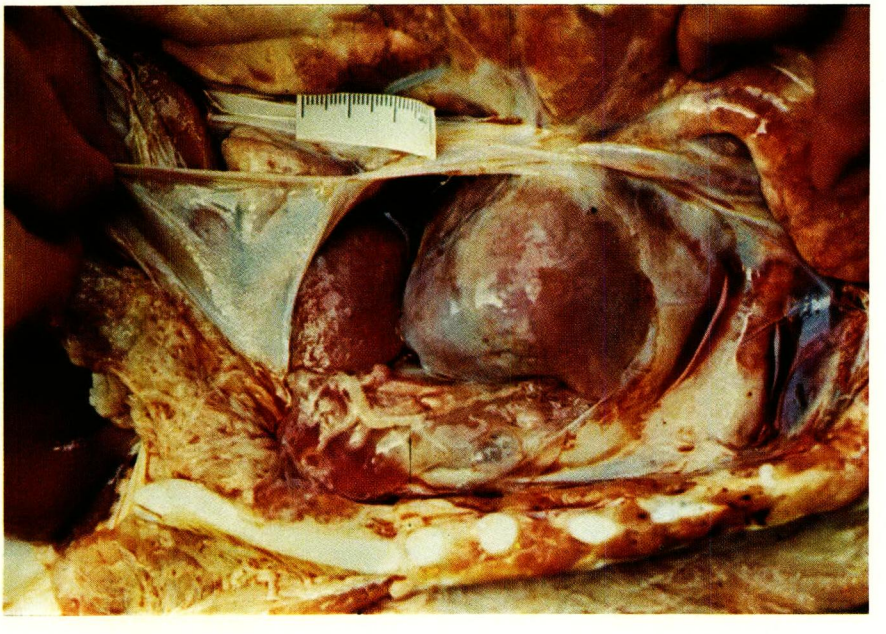

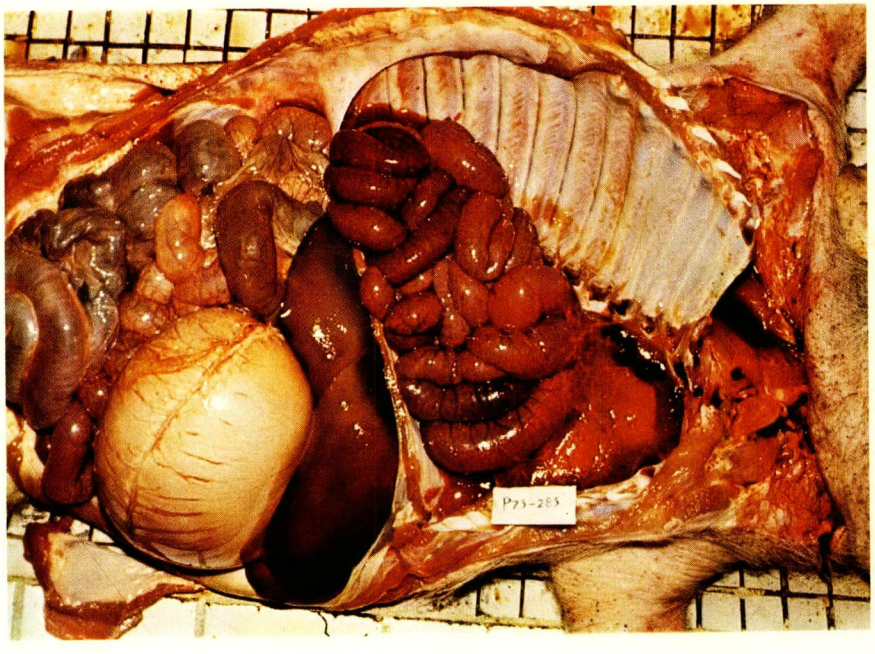

PLATE 92: DIAPHRAGMATIC HERNIA

A major portion of the intestinal tract has herniated through the diaphragm into the right pleura cavity. As its blood supply became compromized by constriction at the hernial ring, it caused the severe passive congestion seen here. The animal may have died by the mechanical interference with respiration or even absorption of toxins from the stagnated intestine. The two black areas on the diaphragmatic surface of the liver represent pseudomelanosis, a postmortem change of blood by hydrogen sulfide. It should be remembered that in cases of herniation, the intestine may slip back and forth through the ring for days, weeks, months or years before the right combination of gas and other contents prevent the bowel from moving freely back and forth. Congenital hernias are more common near the tendinous center of the diaphragm while acquired traumatic ones are in the periphery and usually have connective tissue scarring associated with them.

PLATE 93: FOREIGN BODY MYOSITIS

The dark, slightly elevated focus with the whitish debris around the bloody center is a recent intramuscular injection site with a penicillin compound. The elevated area near this focus with the broader than normal fascial bands is an area of prior intramuscular injection probably with the same compound. Such a lesion is iatrogenic (caused by the clinician) and can result in meat condemnation at time of slaughter.

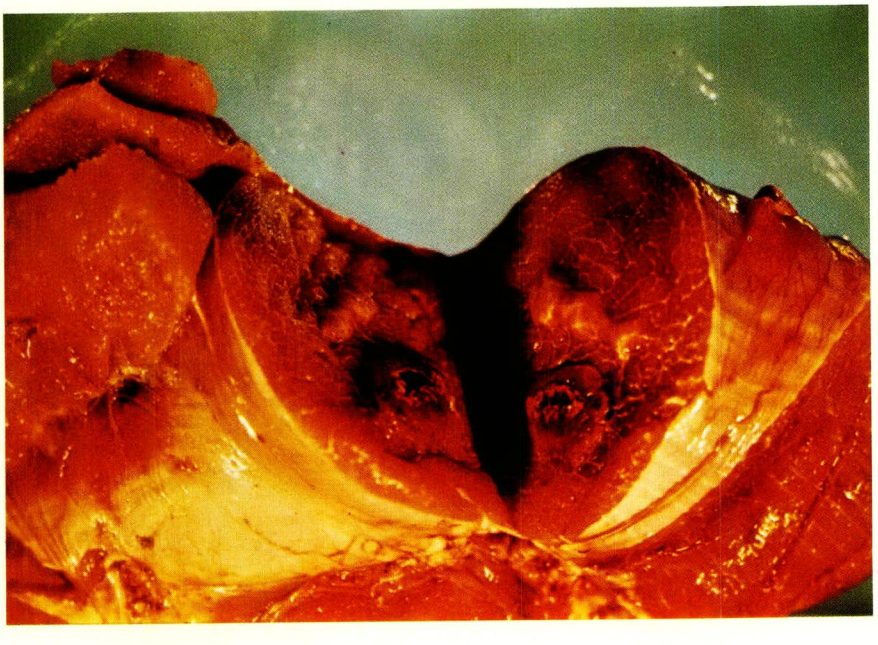



PLATE 94: INJECTION SITE TRAUMA (FOREIGN BODY MYOSITIS)

The area of hemorrhage and yellowish edematous reaction in this muscle is the result of an intramuscular injection in the course of treatment. A large number of different colored medicines and materials can be found in various areas which at first are difficult to explain as they appear "foreign" to the body. In such cases, the odor of the area should be checked as alcohol is often used as a diluent. Artefacts such as these are common in the neck region from iron injections and in any muscle areas used for antibiotic injections.

PLATE 95: MUSCLE HEMATOMA

The large pockets of blood within the muscle mass proper are hematomas from a probable Vit K deficiency.

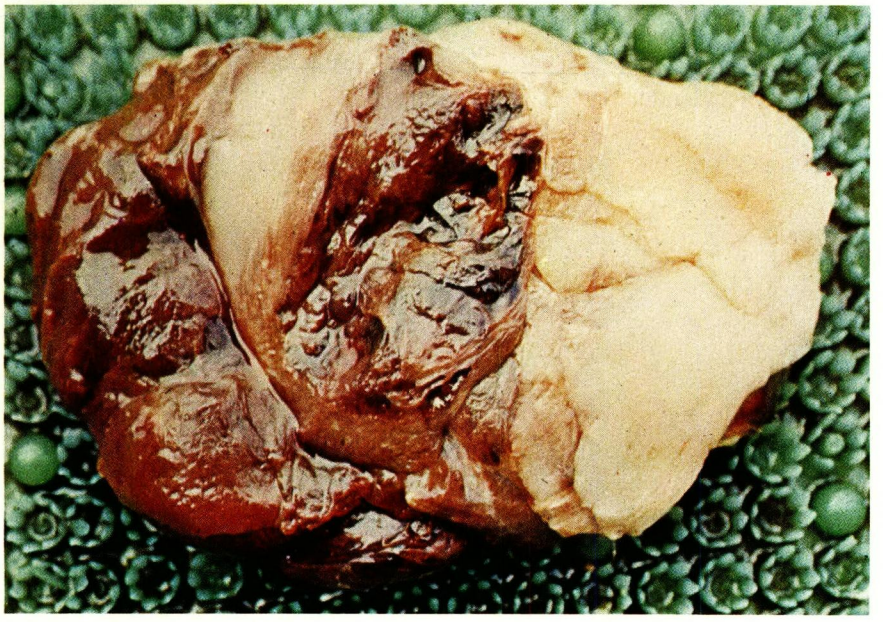

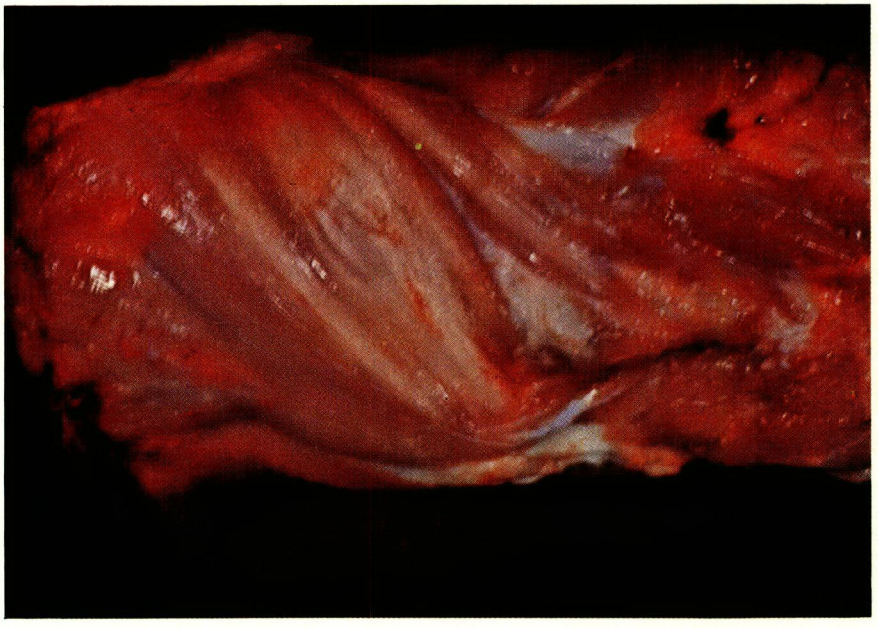

PLATE 96: NUTRITIONAL MUSCULAR DYSTROPHY

Two thirds of the muscle covering the atlas is distinctly pale and opaque. The affected fibers are delineated from the adjacent fibers. Histologically, classical Zenker's degeneration of the affected fibers is seen. In many animals with this Vit E/Se responsive disease, many body muscles and even the heart is affected. In some, especially those with limited muscle activity, only those muscles in constant use such as the muscles of deglutition in a "crate raised" veal calf, will be affected. Nursing animals may only show the lesion in muscles that hold the head in the nursing position.

PLATE 97: NUTRITIONAL MUSCULAR DYSTROPHY

The discrete, opaque white clump of muscle fibers of this young pig is an area of Zenker's degeneration. The histological picture would be one of swollen, hyalinized muscle fibers with a loss of cross striations. Some mineralization of the affected fibers may also be present. This is usually associated with a Vit E/Se responsive problem in the numerous species in which it is seen. The discrete nature is a necessary feature to differentiate this Zenker's degeneration from pale (anemic) muscle.



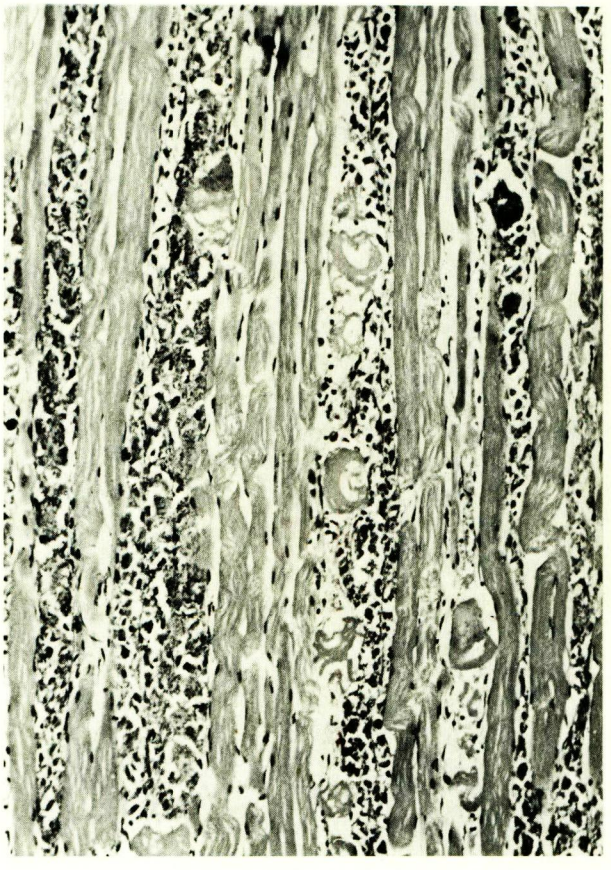

PLATE 98: ZENKER'S DEGENERATION

The pale, long fibers are essentially normal muscle cells, but in the round cell infiltration areas roundish fragments of degenerating fibers are scattered. These small pieces are often smooth, shiny (hyaline), swollen and without cross striations in H&E sections. The round cell infiltrations in some instances may include a surprising number of neutrophils. At other times many eosinophils may be mixed with the usual chronic inflammatory cell types of lymphocytes, monocytes and plasma cells. If the process continues long enough, the satellite cells (sarcolemmal nuclei) may proliferate. This is a characteristic lesion of such entities as nutritional muscular dystrophy (stiff lamb disease, white muscle disease) a Vit E/Se responsive disease in many species, azoturia (blackwater, Monday morning disease) in horses, porcine stress syndrome in pigs and almost any traumatic lesion of muscle.

PLATE 99: ZENKER'S DEGENERATION WITH MINERALIZATION

Most of the tissue here consists of striated muscle with the faint pink fibers (essentially normal) and the darker fibers in various stages of Zenker's degeneration with swelling, hyalinization and loss of cross striations. Several fibers show dark purplish centers of mineralization. Surprisingly, mineralization can be seen in such cases without the entire cell being visibly necrotic. Mineralization of any degenerate tissue occurs quickly in uremia.

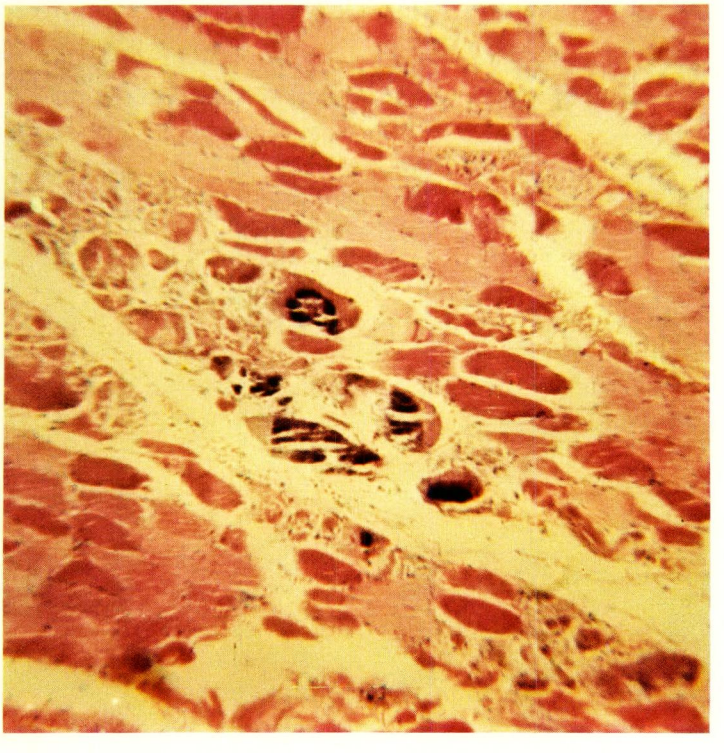



PLATE 100: PORCINE STRESS SYNDROME (PSS)

These muscles are pale, but the animal was not bled out naturally or otherwise. It had a high body temperature at death and its adrenal glands were smaller than normal. Scattered in the muscles, especially those of the limbs and loin, were areas of fascial edema pointed out by the arrows in this picture. This form of adrenal atrophy disease is easily recognized, but when the muscle lesions are not present, the diagnosis is more difficult to make. One should always suspect P S S when a pig dies suddenly with an extremely high temperature.

PLATE 101: PORCINE STRESS SYNDROME (PSS)

These major muscle masses of the hind limb, as well as most of the appendicular muscle masses, are pale and swollen with edema in the fascial planes. The overlying loose connective tissue is also often slightly edematous. The deeper muscle mass in this case is unaffected as is usual in this disease. The red, deeper muscle seen here helps differentiate this from anemic tissue in which all would be pale. This disease, porcine stress syndrome, is probably related to adrenal atrophy and function. Histologically, the affected muscle is undergoing acute Zenker's degeneration.



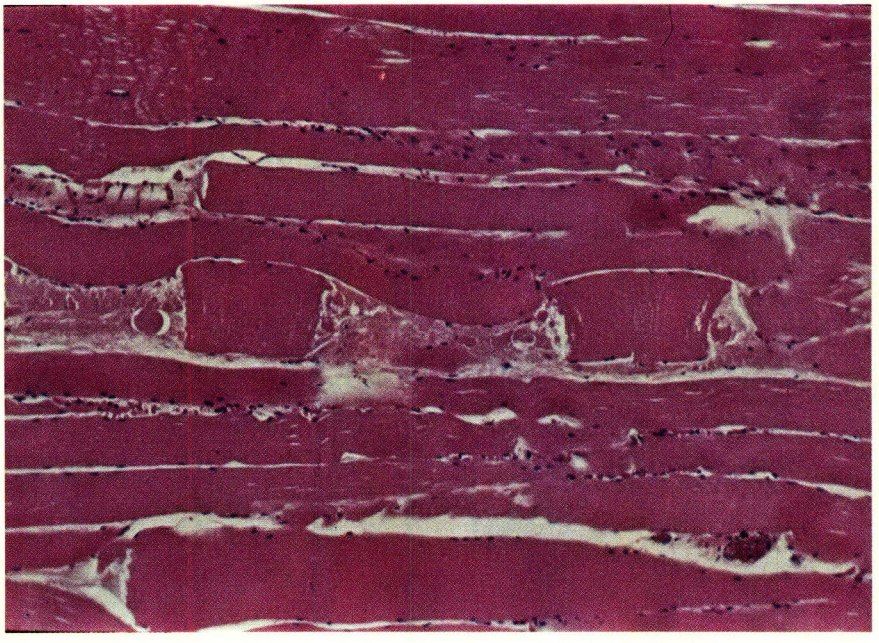

PLATE 102: ACUTE ZENKER'S DEGENERATION

The two relatively square, homogeneous pieces of muscle are portions of a muscle fiber that has undergone acute Zenker's degeneration, with hyalinization, swelling and loss of cross striations. Portions of this individual muscle cell (fiber) on each side of these blocks have undergone lysis. Parts of other cells also show various stages of degeneration in this case of porcine stress syndrome (PSS). No inflammatory cell invasion is seen, as the animal died too rapidly.

PLATE 103: GANGRENOUS MYOSITIS

The dark red to black discoloration of this area of hind limb muscle of a cow contains many bubbles of gas, much hemorrhage and a distinct odor of rancid milk products. In addition, these areas are usually dry appearing on their cut surface in comparison to the more shiny unaffected muscle. This is a case of blackleg caused by Clostridium chauvoei. The majority of these blackleg lesions are in the large muscle masses of the limbs, but they may be limited in any one case to a single focus in the heart or the crura of the diaphragm. Contaminated wounds may develop similar lesions, but should be considered wound gangrene even if the same organism is isolated.



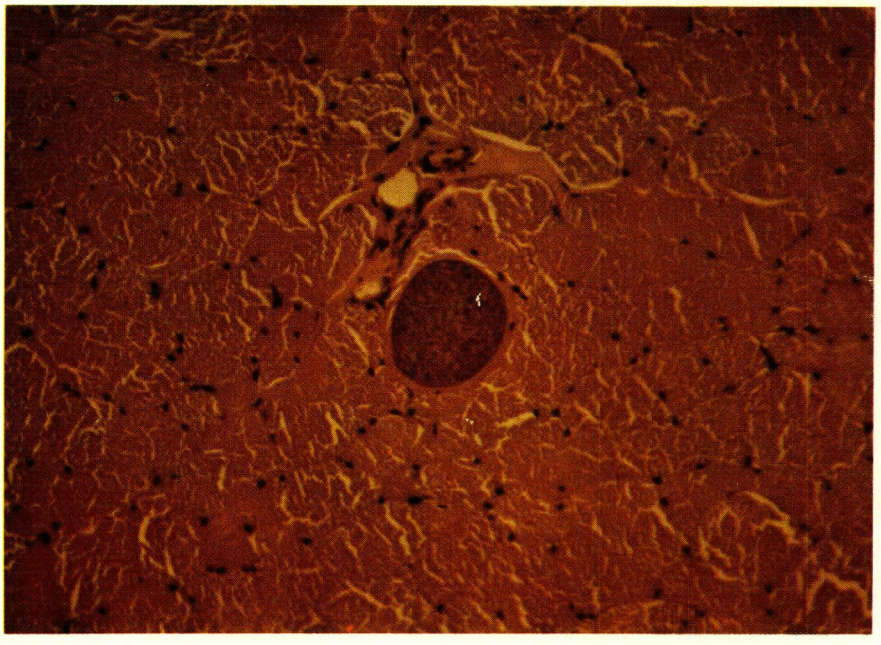

PLATE 104: SARCOSPORIDIOSIS

The single, thick walled cyst with many slightly elongated bodies in is a sacrcocyst. These are thought to be protozoa. They are found in most animals as an incidental finding for they usually ellicit no host response. With few exceptions as the duck, these are not visible grossly. Eosinophilic myositis of cattle has on occasion been considered to be caused by this organism, but there is no consensus on this relationship.

PLATE 105: TRICHINOSIS

The obligatory parasite is seen here within an individual muscle cell. Trichina spiralis has no free living stage as it lives mostly in muscle tissue. It is normally seen in "raw meat" eaters as carnivores and omnivores, including man. Only a minimal tissue reaction is seen with these usually. Intracellular parasites such as sarcocysts are also seen in muscle cells, but they have rather uniform, unicellular bodies and not a complex body as in this nematode.



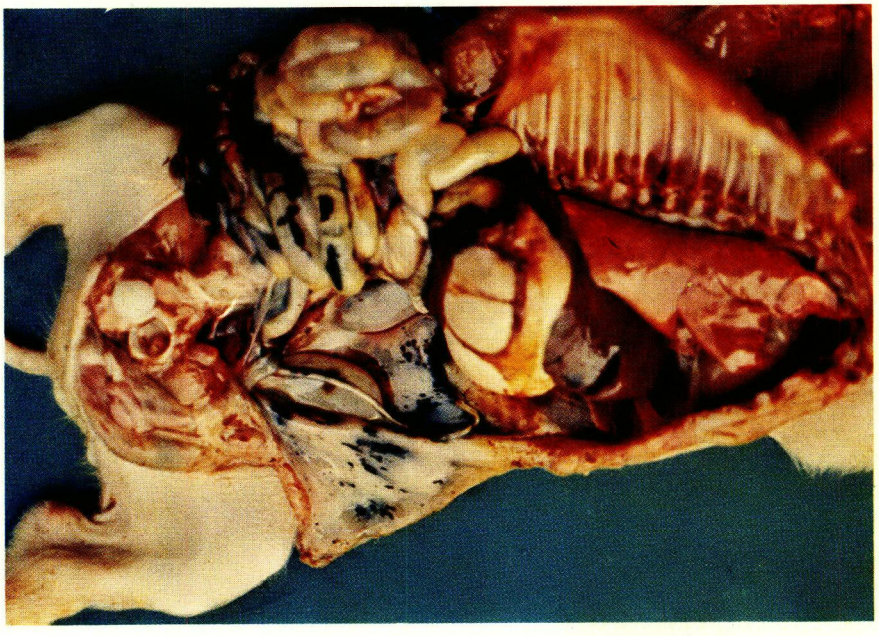

PLATE 106: PSEUDOMELANOSIS

This opened abdominal cavity shows numerous spots and patches of dark black pigment (pseudomelanosis) in and on the peritoneum. These are remnants of old hemorrhage from possible birth trauma with postmortem color change. Most cases of pseudomelanosis are associated with the more vascular organs such as the liver, kidney and gut, which are in contact with the bacterial laden bowel. The blood in these organs chemically react with the H_2S produced by the bacteria in the gut to produce the dark color.

PLATE 107: ASCITES (HYDROPERITONEUM)

The excessive clear fluid in the peritoneal cavity is ascitic fluid. The tightly bundled mass of intestine is a fairly constant feature of ascites. The ascitic fluid, usually accumulates as a result of failure of lymphatics to drain the excessive fluid from the abdominal cavity. The excessive fluid developed as a result of a nutmeg (chronic passive congestion) liver in which blood flow out of the liver and thus out of the bowel is greatly reduced. The initiating lesion in this pig was a cardiomyopathy that resulted from a Vit E/Se responsive disease problem.



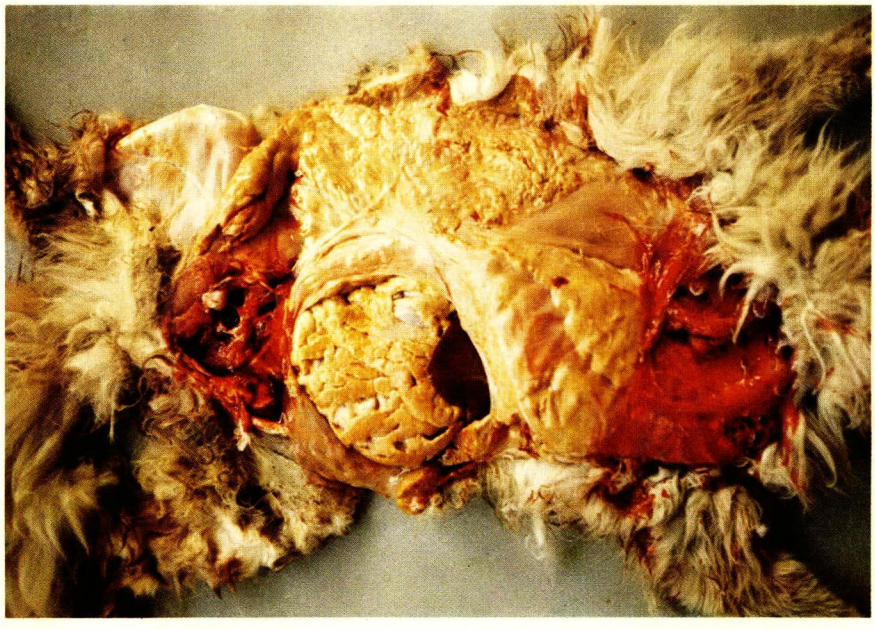

PLATE 108: STEATITIS (YELLOW FAT DISEASE)

The subcutaneous fat over most of the body and the omental and mesenteric fat is distinctly yellow and slightly firmer than normal (steatitis). Most cases have a definite fish odor. Of note is the fact that other fat depots, as around the kidney, heart and mediastinum may not be involved. Affected animals usually have a history of eating an almost exclusive fish or fish product diet. They may have an acid fast pigment, ceroid, in the affected adipose tissue. This is a Vit E/Se responsive disease. This lesion is common in cats and pigs.

PLATE 109: STEATITIS

Most of the large clear spaces are fat cells with the lipid taken out of them during slide processing. Many inflammatory cells and some amorphous debris in some spaces represent fat necrosis with inflammation.

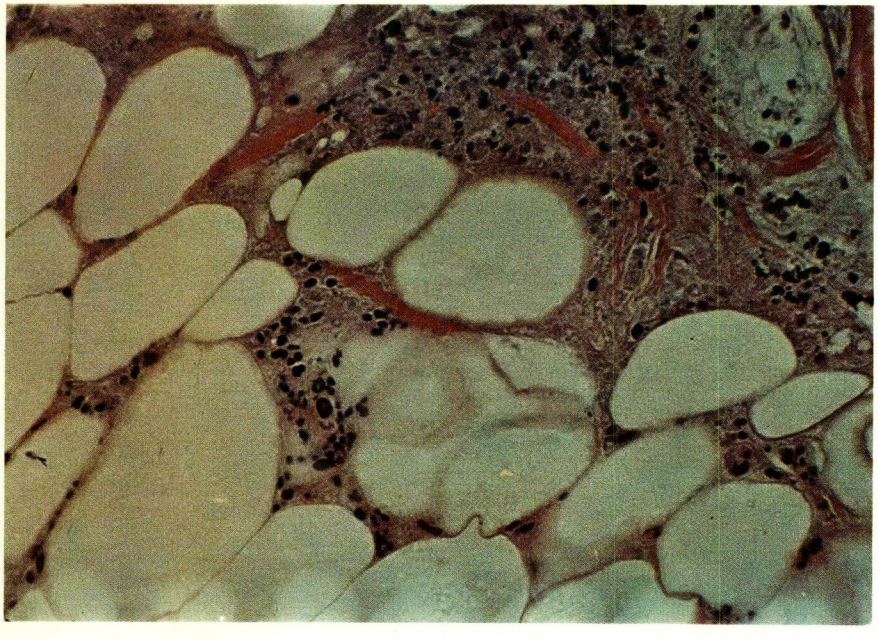

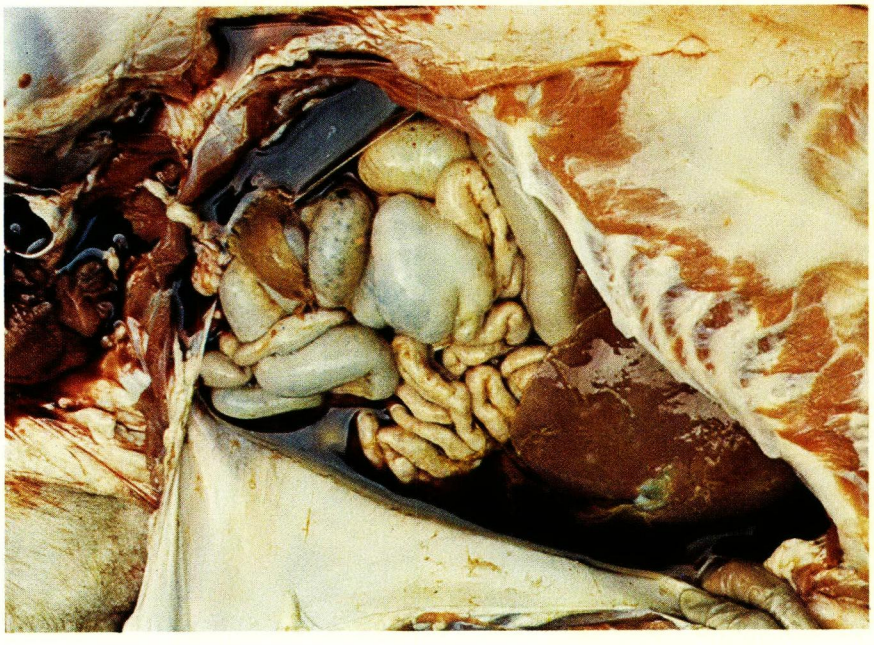

PLATE 110: ACUTE PERITONITIS

On opening the abdominal cavity, a greenish watery fluid with strands and sheets of fibrin escaped. The viscera, especially the intestine, has "bunched up" from the irritating peritoneal fluid which is gastric fluid and bile that has escaped from a perforated esophagogastric ulcer. While initially called a bile peritonitis, its source was not primarily a bile escape as it leaked out only secondarily through the gastric perforation. Bile can cause a very similar lesion in cases of bile duct rupture or perforation as in ascarid damage to the biliary system.

PLATE 111: FIBRINOUS PERITONITIS

Many strands and clumps of fibrin are scattered in the abdominal cavity. A castration wound is just visible between the hind legs. As this was the only source of infection and as it has a direct portal of entry via the inguinal canal, it is apropos to consider this the cause. GI perforations, umbilical infections and the like can all cause this type of lesion. The organisms which may be isolated vary greatly and depend on which one contaminated the wound. Without an accountable wound, one should suspect polyserositis caused by Hemophilus spp. (Glasser's disease).

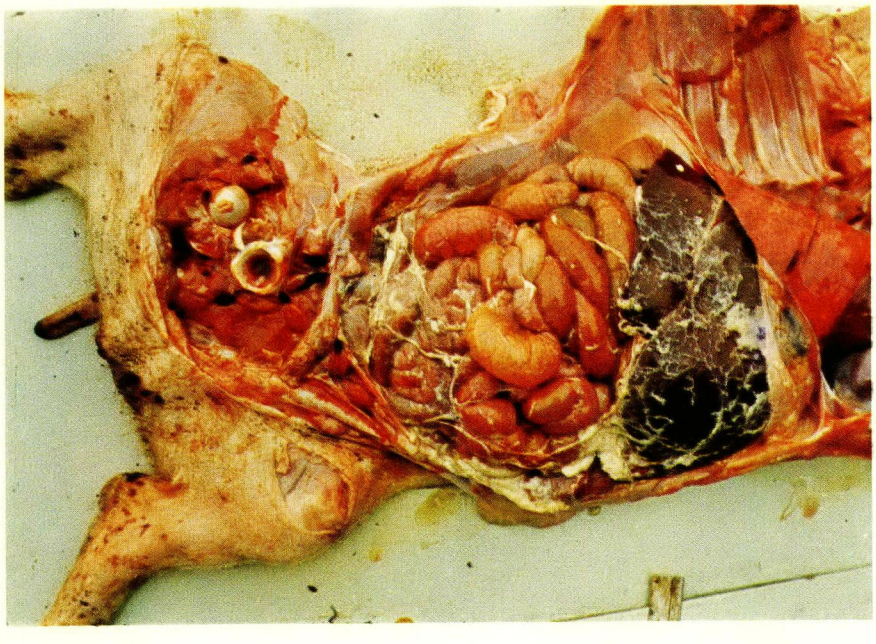



PLATE 112: CHRONIC PERITONITIS

The segment of bowel with the piece of attached mesentery has multiple tiny bits and strands of fibrous, not fibrinous, tissue attached to the serosa of both the bowel and, to a lesser extent, the mesentery. An umbilical infection was the original source of peritonitis which apparently partially healed itself, but with organization of the fibrin, connective tissue replaced it. Almost any type of abdominal serositis could result in this lesion providing the animal lived long enough.

PLATE 113: MESENTERIC BONE FORMATION (OSSIFICATION)

Scattered in several areas of the mesentery, with one area pointed out by arrows, are flat plates of bone. Their cause is not known, but it is thought that they may be the result of chronic inflammation. Most of these are incidental findings at necropsy.





PLATE 114: LIPOCERE

In this pig, the layer of fat seen is lined on one side by the peritoneum of the abdominal wall and on the other by the abdominal wall muscle. In the inner half of the fat layer, the fat has a pale opaque appearance, lipocere (adipocere), while the outer fat is normal. This is a change of fat to a firmer, waxy nature and it is a postmortem change. In cattle and sheep, another change occurs in fat depots terminally in the form of 1-2 mm. foci of opaque, white fat with crystals of soap seen histologically.

PLATE 115: HEMANGIOSARCOMA

The multiple, 1-3 mm. red masses scattered in this dog's peritoneum are metastatic foci of a malignant blood vessel neoplasm. The primary tumor was a hemangiosarcoma in the spleen. At first glance, one could consider these petechial hemorrhages. Its benign counterpart, the hemangioma, is common in the skin.



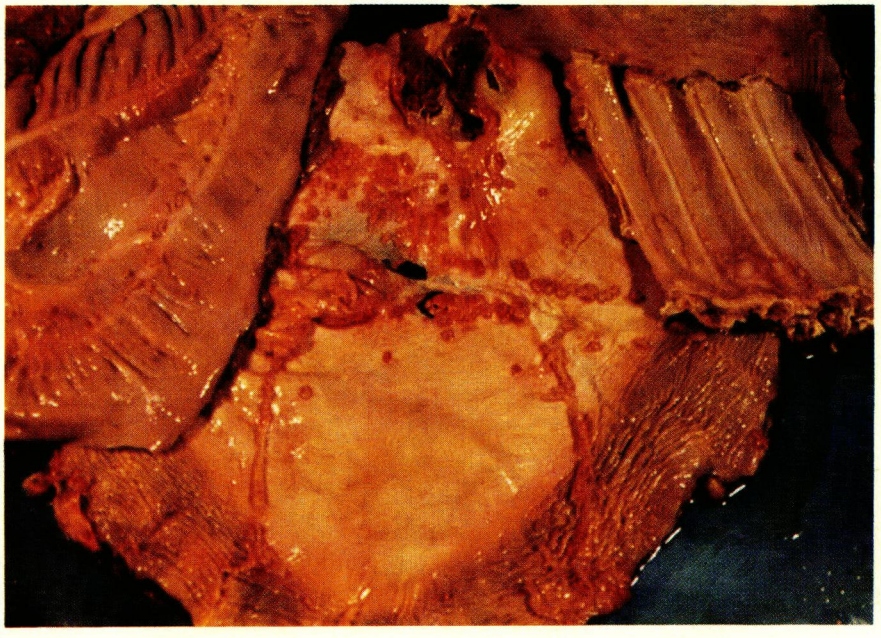

PLATE 115A: MESOTHELIOMA

The multiple small masses attached to the costal pleura, serosa of the colon and especially concentrated on the peritoneal serosa of the diaphragm are mesothelial tumors originating from the serosa itself. When first observed, these masses should make one consider the various granulomatous diseases that make similar lesions, such as tuberculosis. One should also consider that these were implantation sites of such tumors as the granulosa cell tumor, bile duct and pancreatic duct tumors which often rupture and subsequently implant.

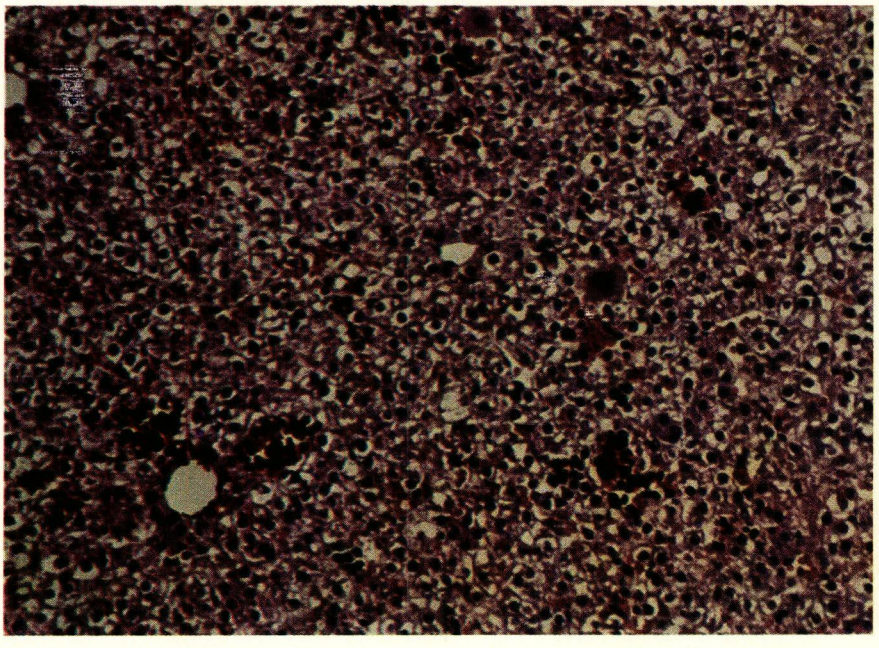

PLATE 116: EXTRAMEDULLARY HEMATOPOIESIS

A clear lumen of a central vein is in the approximate center of this picture. Scattered around the lobule are several clumps of round cells mixed with red blood cells. These are foci of extramedullary hematopoiesis. The one large cell with three clumped nuclei and much cytoplasma is a megakaryocyte. The liver cord cells of this newborn pig are vacuolated now, as the glycogen in them at the time the piglet died was dissolved out in slide preparation. Some hematopoiesis is to be expected in baby pigs as the liver in utero is a blood forming organ. Later in life the blood formation is taken over by the bone marrow and if seen in an older animal's liver, it would probably represent a compensatory mechanism for blood loss.

PLATE 116A: GALLBLADDER EDEMA

The slightly opaque, watery fluid surrounding the gallbladder is edema in this pig that died from hemophilus pneumonia. It is a nonspecific lesion and is seen in many animals under a variety of conditions. The well marked lobular pattern is normal for pigs. The blackened surface on one part of this section is pseudomelanosis, the result of the chemical reaction of bacterial H_2S in the adjacent bowel on the blood in the liver. In dogs with the proper history and other lesions, gallbladder edema is helpful in making a diagnosis of infectious canine hepatitis, but it is also seen in cases of distemper, toxoplasmosis, normal euthanasia, congestive heart failure and others.





PLATE 117: POSTMORTEM AUTOLYSIS (DECOMPOSITION, ROT)

The flabby appearance and the splotchy areas of dark parenchyma, where blood is more concentrated or at least has not drained from the liver, are classical findings of autolysis. On a cut section many gas bubbles are to be seen. In some cases, the bubbles are on the liver surface itself just under the capsule. Any type of intestinal organisms may be isolated on culture because they came here via the portal circulation after death or terminally.

PLATE 118: POSTMORTEM AUTOLYSIS

Accumulations of gas bubbles can be seen on the surface and throughout the liver (foamy liver) in decomposed animals. The amount of gas formation varies with the time, temperature and the number of bacteria migrating via the portal circulation from the gut at death or immediately after death. Histologically, many bacterial rods may be seen along with the gas bubbles but no host cellular response will be evident. In a few cases where the host's bowel integrity is lost a few hours before death, focal necrosis with early cellular response may be found.





PLATE 119: HERNIATED PARENCHYMA

The two small nodules projecting into the caudal vena cava as it leaves the liver are bits of parenchyma that have partially herniated through the thin walled vena cava. This is a congenital anomaly and not significant. They are still covered by endothelium.

PLATE 120: HERNIATED LIVER LOBES

The two pale liver lobes had gone through a hernial ring in the diaphragm into the pericardial cavity. Partial strangulation by adhesions and connective tissue maturation and contraction at the hernial ring has caused atrophy and a relative fibrosis of these lobes from the passive congestion induced. As the pig was young and grew rapidly, the liver became more compressed and strangulated in its restricted location.





PLATE 121: HEPATOMEGALY

While both livers are of almost equal size, the uniformly tan liver is from a 26 lb. piglet, and the mottled liver is from a 9 lb. piglet. The difference is that the 9 lb. piglet's liver is markedly but uniformly enlarged. This was the result of chronic passive congestion from a constrictive pericarditis that prevented the heart from filling properly. Hepatomegaly is initially recognized when the abdominal cavity is first opened and the liver is found extending much farther caudally than normal and there is no pleural cavity enlargement to account for it. In older animals a diffuse neoplastic involvement should also be considered.

PLATE 122: ANOXIC CHANGE AND CHRONIC PASSIVE CONGESTION

The liver with the pale discrete dots of central portions of lobules is from a pig that died from a bleeding gastric ulcer. The centrally located cord cells have undergone slight fatty change and the entire liver is pale from the blood loss. The other liver is firmer than normal and the normal liver lobule architecture is clearly outlined on the surface view. In the cut surface view, the brownish areas are connecting areas of central cord cells and central veins with passive congestion. The pale areas are the radiating portal areas helping to give the "nutmeg" appearance. A relatively rare persistent foramen ovale caused this case of chronic passive congestion.





PLATE 123: CHRONIC PASSIVE CONGESTION (CPC, NUTMEG LIVER)

The characteristic light and dark areas of a nutmeg liver are well shown here. The pale areas are the portal areas of the lobules with the adjacent anoxic cord cells. Some of the latter are undergoing fatty change. The dark areas are the central veins and adjacent sinusoids filled with the hypoxic static blood. The pale portal areas show their branching (arborization) pattern well in scattered areas. Surprisingly, while most cases involve the total liver, there are some acute cases with only scattered areas affected and vice versa, with only a few areas not affected. This may suggest an unequal blood flow (laminar?) or else some areas may be more or less resistent to anoxia. Any obstruction to blood flow out of the liver can cause this lesion if extensive enough or of long enough duration. Heart anomalies are commonly at fault.

PLATE 124: CHRONIC PASSIVE CONGESTION (CPC, NUTMEG LIVER)

The portal areas and peripheral zone of these lobules are essentially normal. The central and midzonal cord cells have almost been completely replaced by blood filled, dilated sinusoids. There are a few chronic inflammatory cell (round cell) foci at the junction between the normal peripheral zone and the atrophic more central areas. Several dark brownish pigment areas of acid hematin (formalinized blood pigment) are scattered in the congested areas. In some cases of CPC, the central veins themselves may not be significantly dilated, and even the immediate cord cells adjacent to the vein may be present and normal, while in other cases, as in this one, they are absent.

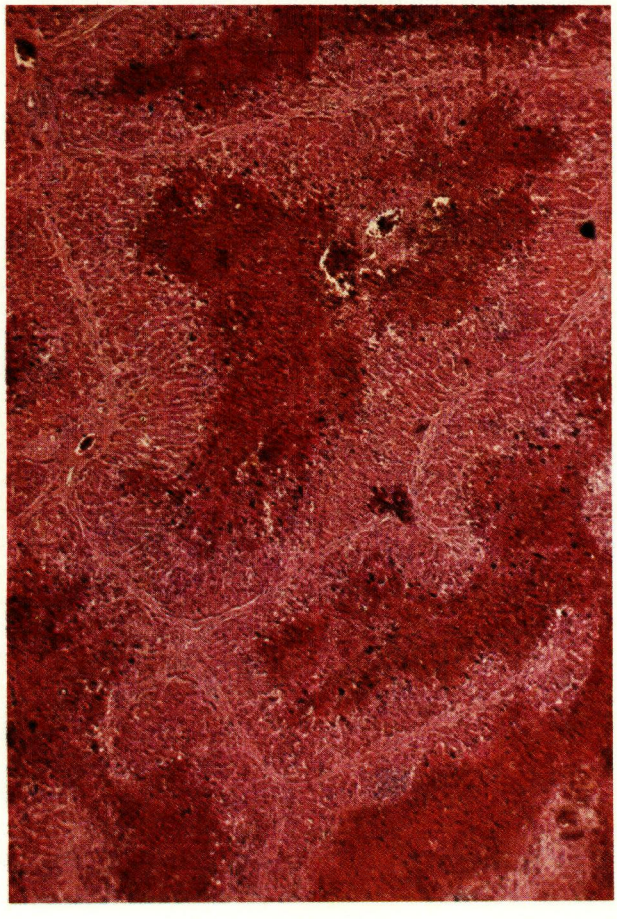

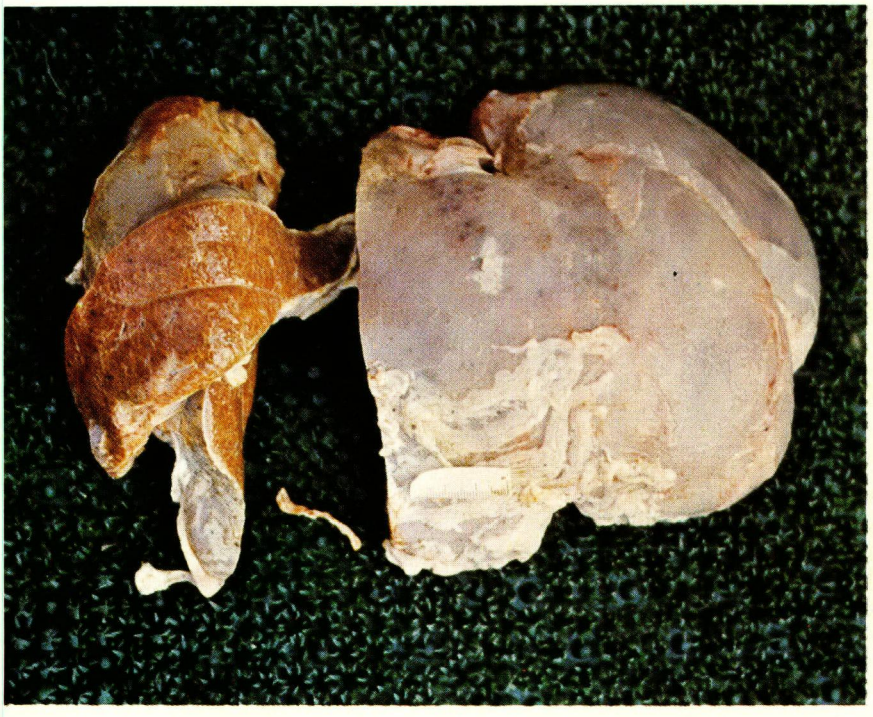

PLATE 125: CARDIAC CIRRHOSIS

The diffuse lesion in this pig's liver is one of chronic passive congestion which has been present long enough to have resulted in a diffuse fibrosis of all the lobules, cirrhosis. This cirrhosis was the result of a heart lesion and is called cardiac cirrhosis, which is to differentiate it from other types of cirrhoses such as that caused by a chronic cholangitis, biliary cirrhosis.

PLATE 126: CARDIAC CIRRHOSIS

This section of pig liver shows a single lobule in the center and parts of several other lobules around it. All have the prominent portal connective tissue normal in pigs, but in addition, connective tissue is increased about the central vein and throughout the lobule proper connecting the central vein to the portal areas. Almost any chronic heart problem that slows liver outflow of blood, such as an anomaly with left heart blood shunted to the right can cause this. Vegetative endocarditis and chronic lung disease which increases peripheral resistance to right heart outflow may also cause this lesion.

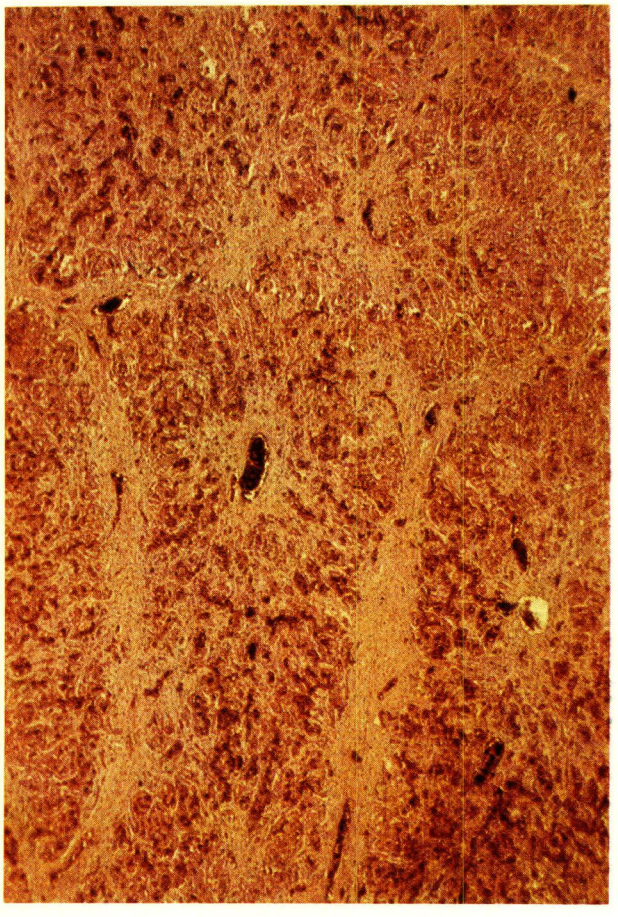



PLATE 127: BILIARY CIRRHOSIS

This cat's liver is firm and markedly rounded as a result of a chronic inflammatory process in the intrahepatic bile ducts (chronic cholangitis) with a marked connective tissue proliferation in these areas (biliary cirrhosis). The cause was not ascertained. No regenerative nodules are to be seen grossly or microscopically as this was a chronic process and at no one time was the "threshold of regeneration" reached to stimulate the regenerative process. This threshold is probably about 15-20%.

PLATE 128: LIVER ATROPHY

The liver shown here is about 1/2 to 2/3 normal size for this captive jaguar. The liver is soft and flabby. Histologically, the lesion is one of less liver cord cells than normal which has made the liver atrophic. Its cause is unknown, but it is a rather common lesion of captured, caged, large, wild felidae.

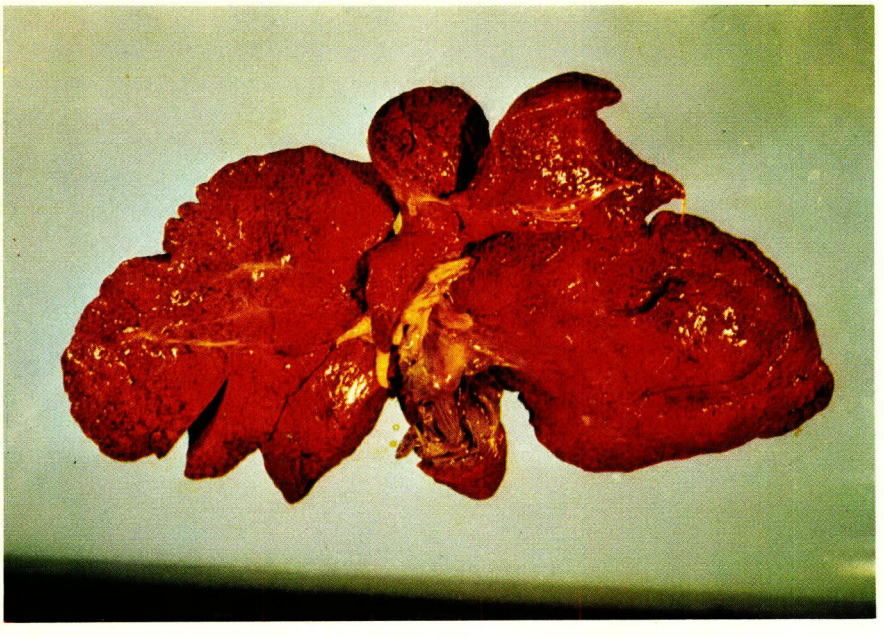

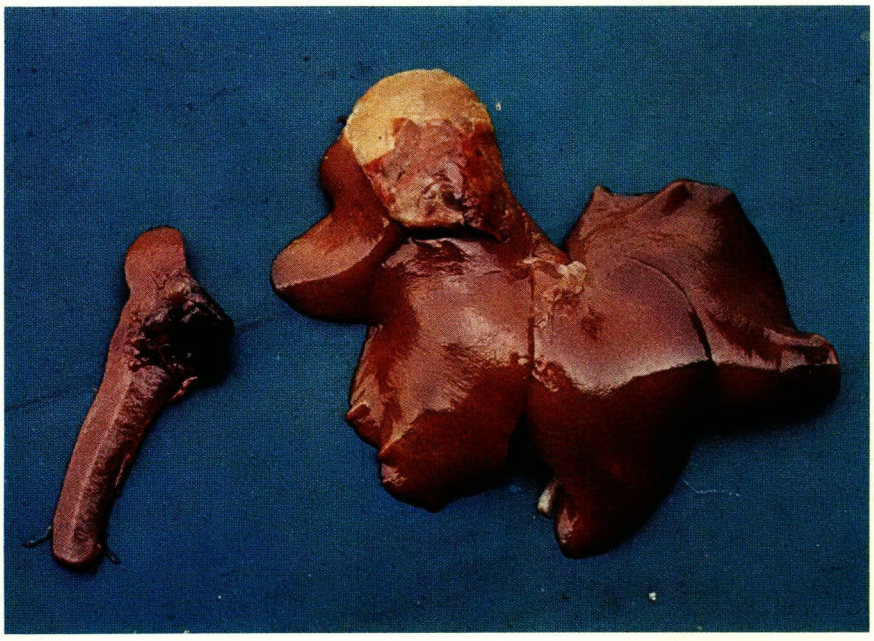

PLATE 129: TRAUMATIC INFARCTION

The white tip of this liver lobe is necrotic liver tissue separated from the normal liver by a distinct line with some fibrin on the surface near the junction. This piglet was stepped on by the sow. Blood vessels were damaged by the trauma, and necrosis to the area supplied by the vessels resulted. The spleen also shows a traumatic hematoma from the same injury.

PLATE 130: HEPATIC INFARCTION

The pale area is the completely necrotic area of liver with a separating zone of inflammatory cells directly adjacent to it. Another area of edema, fibrin and hemorrhage is outside this zone but adjacent to the relatively normal liver. Fibrin and inflammatory cells are on the surface of the normal area of liver. This piglet was stepped on by the sow and resultant vascular damage to this area of the liver caused the infarct. In calves, infarcts are often seen in cases of C. hemolyticum infections and some pasteurella infections.

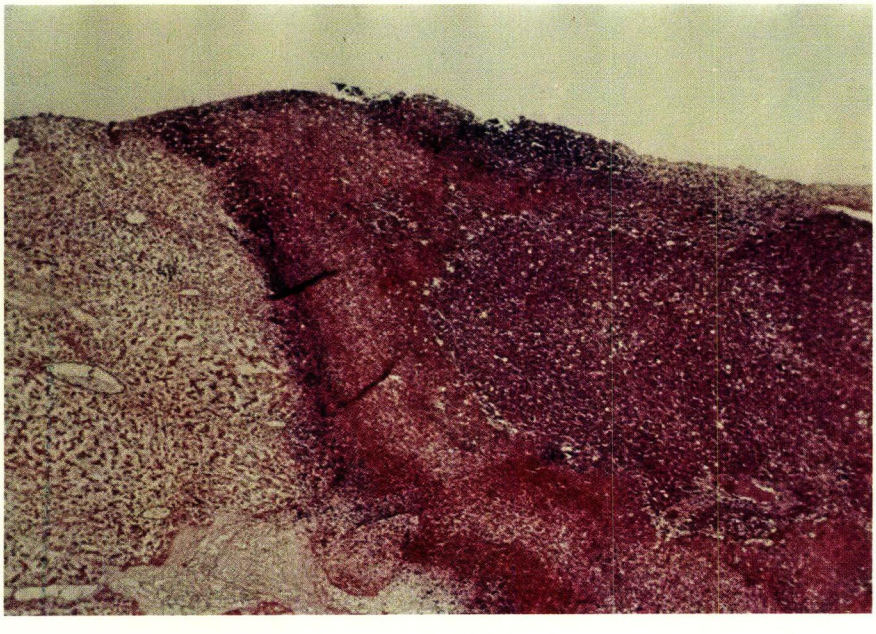

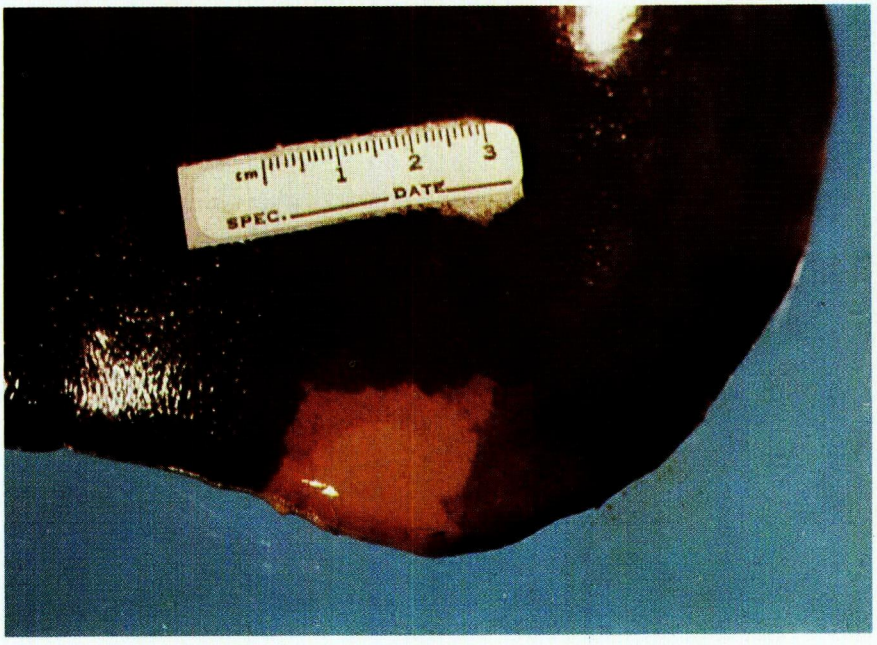

PLATE 131: TENSION LIPIDOSIS

Along the border of this liver is noted a very discrete, rectangular focus of pale fatty liver. On the very edge of this lesion a tag of connective tissue is present. This lesion can be found anywhere on the liver surface. The connective tissue tag attached to some other tissue exerts tension on this area of liver compromising its blood supply with fatty change resulting locally. It is a common lesion in cattle and horses but without much significance.

PLATE 132: MULTIFOCAL AND LOCALLY EXTENSIVE HEMORRHAGIC NECROSIS (HEPATOSIS DIETETICA, HD)



Although experimental cases of HD, four of these livers show the typical hemorrhagic necrosis that may be seen in this disease. The distinctly reddish areas in the "no wheat", "no peas" and "no alfalfa" livers are the lobules or parts of lobules that are affected with necrosis. The lighter areas of these livers are normal. The pale areas of the "no oats" liver are also essentially normal, but the remaining wrinkled and collapsed areas represent a more chronic stage in which the hemorrhage and cellular debris have been cleaned up. The "no barley" liver shows a few areas of capsular fibrosis, the so called "milk spots" associated with parasite migrations. This disease, hepatosis dietetica, is a Vit E/Se responsive disease.



PLATE 133: MULTIFOCAL HEMORRHAGIC NECROSIS (HEPATOSIS DIETETICA)

These distinct red foci are areas of hemorrhagic necrosis which affect whole lobules or parts of lobules, often wedge shaped in this Vit E/Se responsive disease. Its pathogenesis is not known but a vascular phenomenon may be suspected.

PLATE 134: FOCAL HEMORRHAGIC NECROSIS (HEPATOSIS DIETETICA)

The two centrally located lobules are essentially normal. The surrounding lobules show various degrees of hemorrhagic necrosis with almost complete loss of cord cells. The well marked connective tissue capsule about the lobules is a normal part of the pig's liver. This is a Vit E/Se responsive disease.

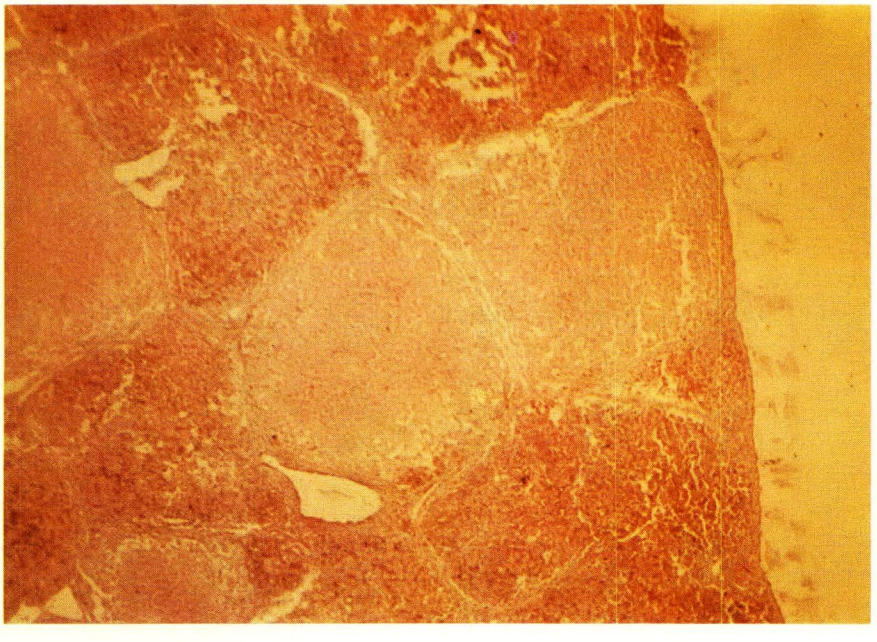

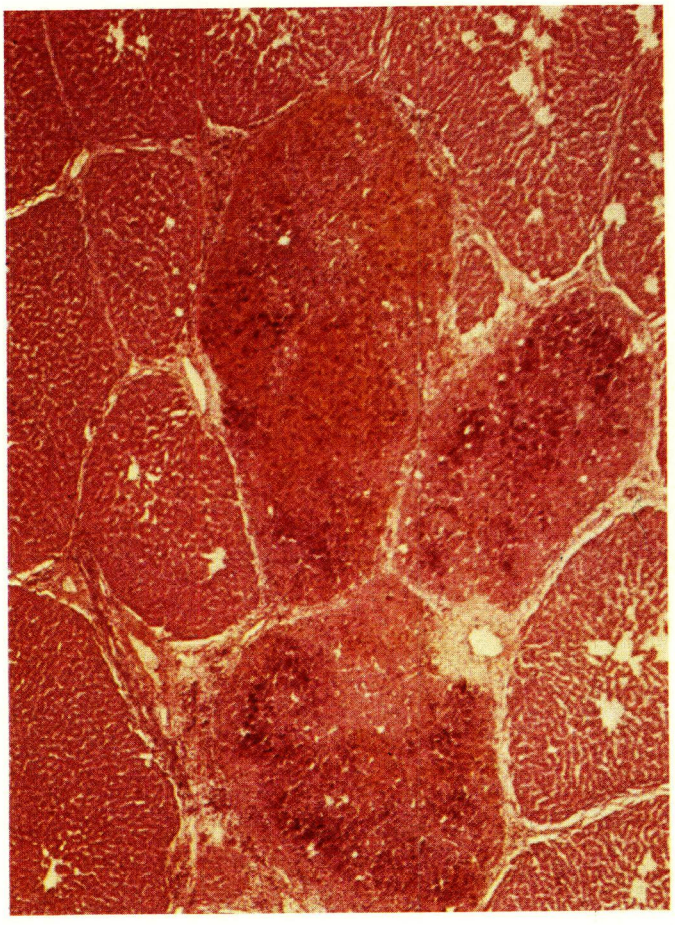

PLATE 135: FOCAL HEMORRHAGIC NECROSIS (HEPATOSIS DIETETICA)

Three lobules are undergoing various degrees of degeneration with hemorrhage and early mineralization. This is a Vit E/Se responsive disease.

PLATE 136: FATTY LIVER (FATTY CHANGE)

With this lesion, the liver is swollen to varying degrees, has a yellowish appearance and is more fragile than normal on palpation. Many toxins both exogenous and endogenous can cause this. It is commonly seen in metabolic diseases of various kinds as with pregnancy, diabetes and acute starvation in a fat animal. In a starved animal, there often is no fat to mobilize in order to get a fatty liver. Three rib impressions are seen on the surface of the right lateral lobe. This lesion is to be differentiated from the pale liver seen in animals that are bled out. In anemic animals, a combination of some fatty change and lack of blood may be present to make the pale, slightly fatty liver. This was a case of aflatoxicoxis.

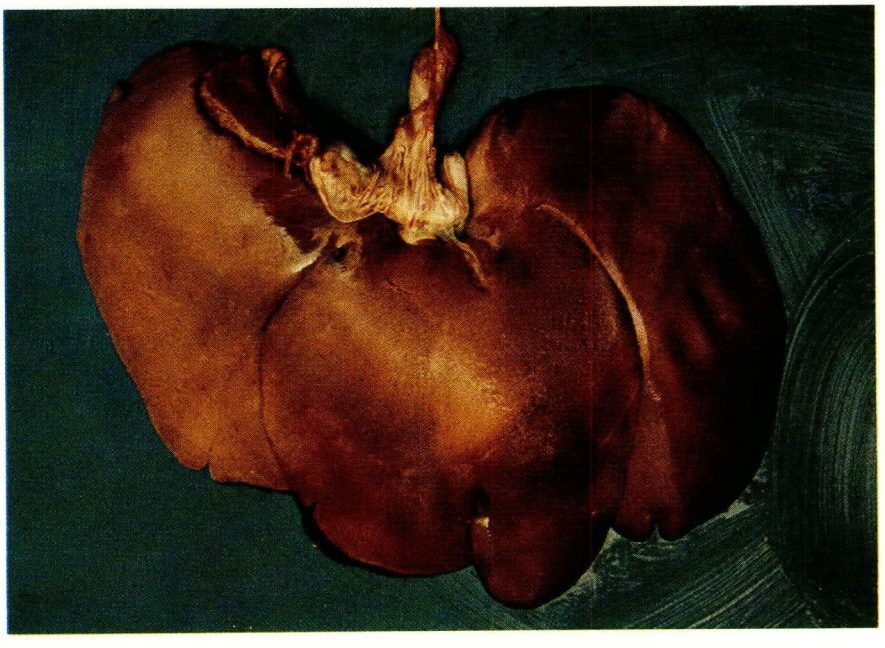

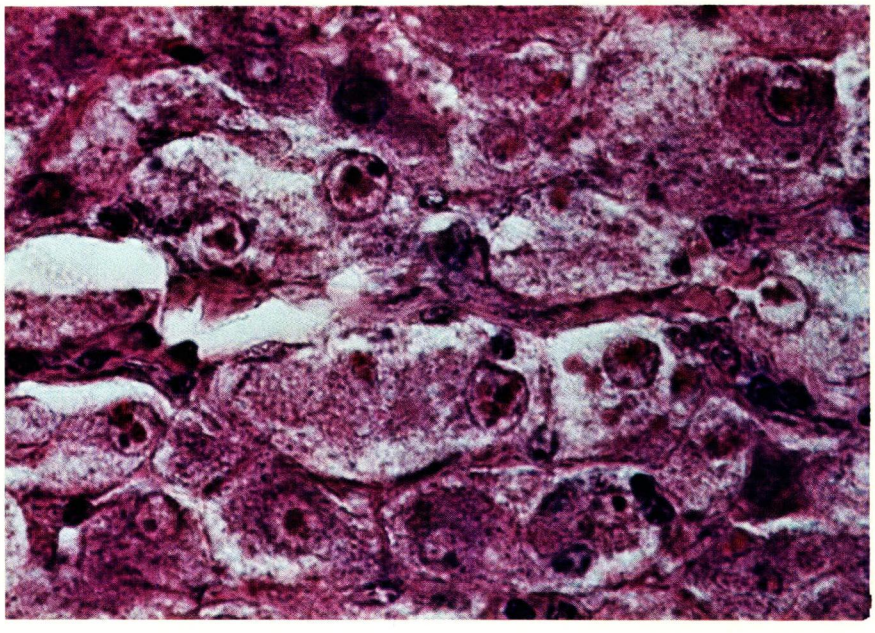

PLATE 137: ACID FAST LEAD POISONING INCLUSIONS

These intranuclear red inclusions are of various sizes and shapes. There is also some margination of chromatin which in H & E sections can be quite suggestive of lead poisoning. Actually other heavy metals such as bismuth etc., can make these also. The cord cells themselves are somewhat swollen as in "cloudy swelling" but this may be an artefact.

PLATE 138: AMYLOIDOSIS

Separating almost every liver cord cell from its sinusoid is a very distinct, pale pink, homogeneous zone of amyloid (similar to starch) in this pig. Most consider amyloidosis an immune problem and when associated with a known chronic infection it is called secondary amyloidosis. When there is no known infectious process in the body it is referred to as primary amyloidosis. Certain well described stress factors, such as crowded housing conditions in ducks, can cause generalized amyloidosis.

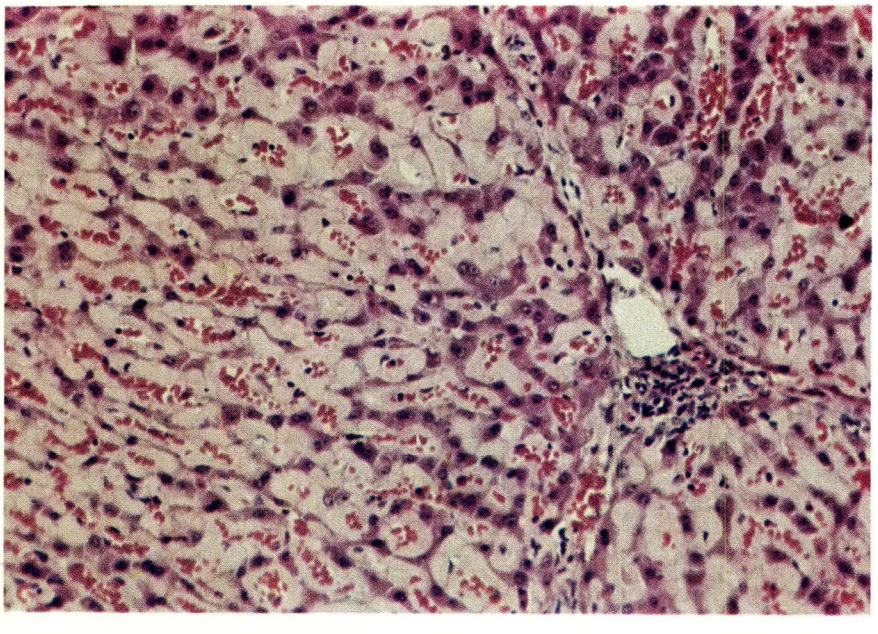

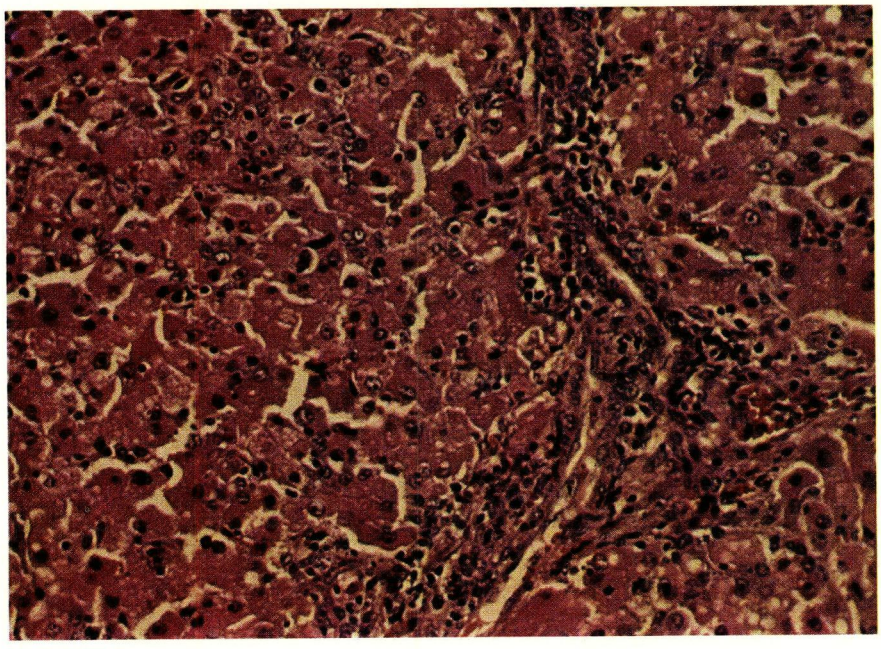

PLATE 139: BILE DUCT PROLIFERATION

Ordinarily one sees a single bile duct or maybe two in a section of this size in the liver. There are several longitudinally cut bile ducts recognized by their cuboidal cell lining. A few round cells are scattered about the triads and sinusoids. In addition, several cord cells appear darker and more pleomorphic than normal suggesting regeneration. This is a case of experimental aflatoxicosis, and its initial lesion is bile duct proliferation in most species. Bile duct proliferation can also be seen in cases of starvation and other diseases so it is not diagnostic by itself.

PLATE 140: HEPATIC CIRRHOSIS AND BILE DUCT PROLIFERATION

The pink cells are the essentially normal, original central cord cells. They will undergo fatty degeneration in time for this process is progressing centrally from the periphery of the lobule. A few chronic inflammatory cells are near some central veins. The midzonal cells show marked fatty degeneration and the peripheral cells have been replaced by proliferating bile ducts and connective tissue. As connective tissue proliferation is affecting each and every lobule in the same relative location in the lobule, in this case the triad, it is cirrhosis and not just indiscriminate fibrosis. This is from a chronic case of aflatoxicosis in a dog.

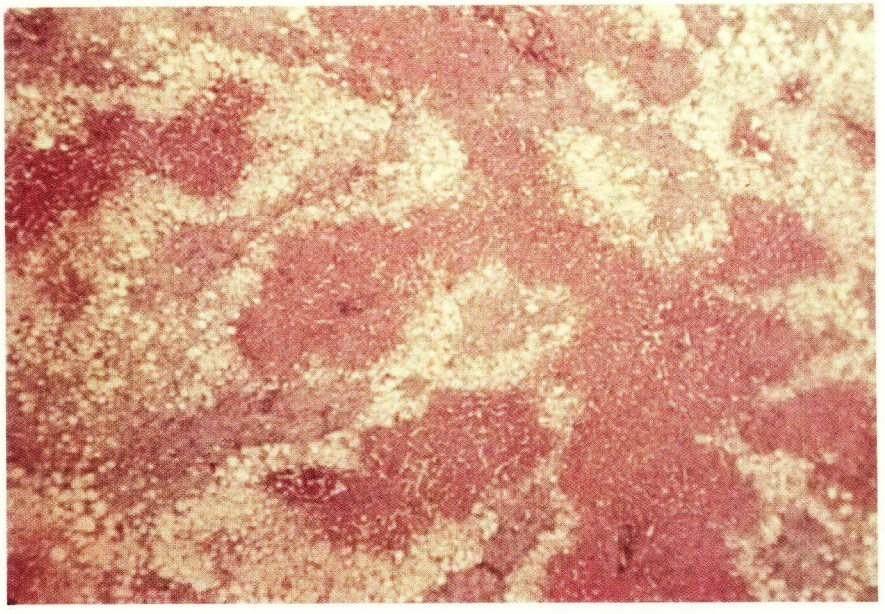

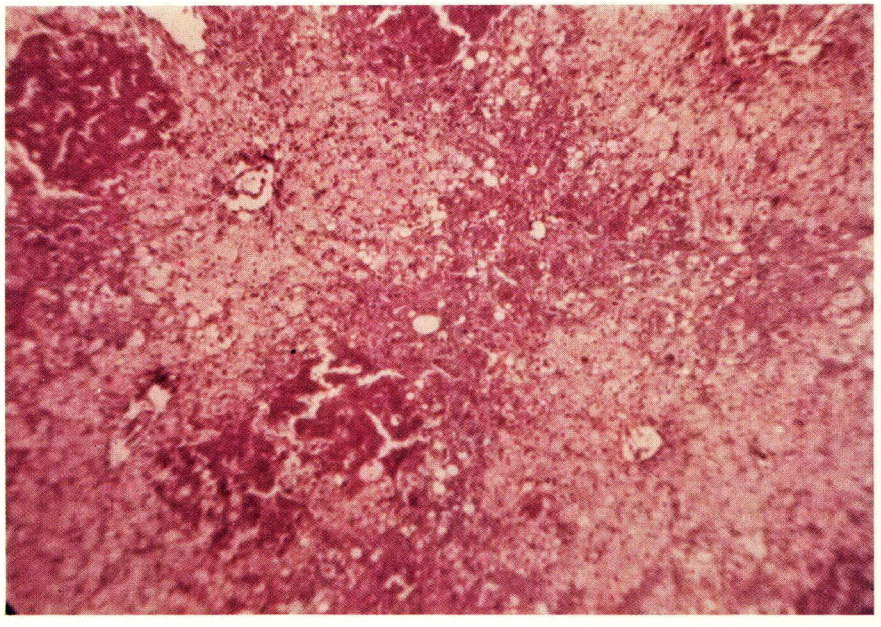

PLATE 141: NODULAR REGENERATION AND BILE DUCT PROLIFERATION

The several dark foci of hepatic cord cells are regenerating nodules of liver located in the area of the triads. The more bluish cells, in finger like projections from the peripheral areas of the lobules, are proliferating bile ducts. The central vein and midzonal areas have only fatty degenerating cord cells remaining. This is a case of chronic aflatoxicosis in a dog. This is to be differentiated from the so called "nodular hyperplasia" which, in reality, probably represents benign neoplasia as it occurs mostly in older animals. In most cases of so called "nodular hyperplasia", there is no evidence of liver disease in the animal and thus no need for compensation is known. In this case pictured here, the need is apparent and the regenerating nodules are truly compensatory.

PLATE 142: NODULAR REGENERATION

The multiple nodules of various dark colors and sizes in this dog's liver represent nodules of regeneration. The lighter brown areas are the original liver tissue that has been damaged. The agent involved is not known. It is apparent that the threshold for regeneration which stimulated the regeneration had been reached. In man, it has been estimated that about 18% of the liver has to be damaged in a short period of time to stimulate regeneration. About 15-20% is necessary in the rat. This condition of nodular regeneration must be differentiated from the mistakenly called nodular hyperplasia seen in old dogs. So called nodular hyperplasia is probably benign neoplasia. It is almost always found in aged animals without prior damage to the organ in which it is found and it occurs in other organs as well. For this reason, it should not be considered a compensatory hyperplasia. Nodular regeneration on the other hand is truly compensatory and found only in organs with evidence of prior damage.



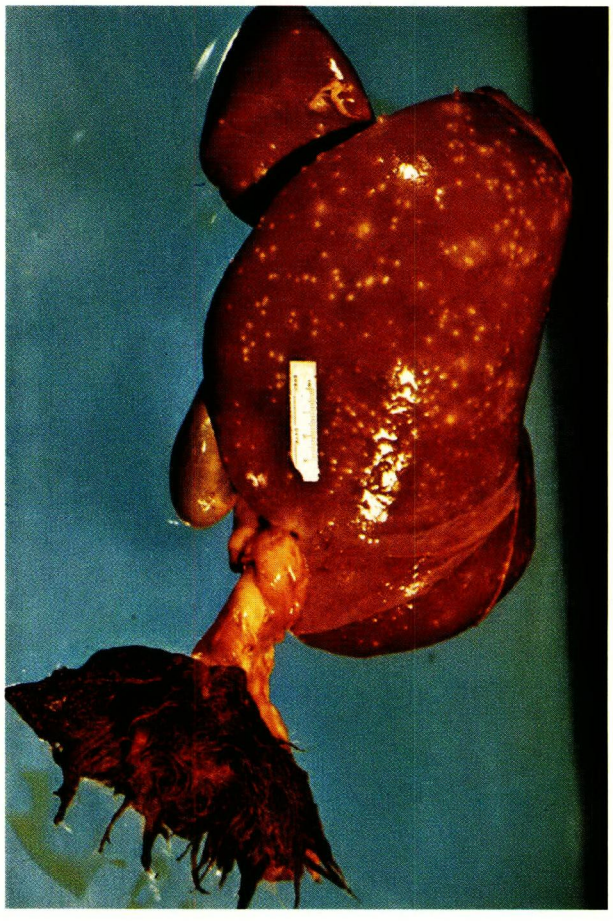

PLATE 143: METASTATIC (EMBOLIC) ABSCESSATION

The liver is showered with a great number of relatively uniform, 2-3 mm. abscesses which have come from the greatly thickened, pus filled umbilical vein. The vein is still attached to the patch of skin which is also swollen with an abscess pocket in its midst (not clearly visible).

PLATE 144: MULTIFOCAL NECROSIS

Within individual lobules for the most part, one can see pale irregular foci with a slightly reddish periphery blending into the normal parenchyma. This is a diffuse lesion, but certainly not every lobule is affected. Focal necrosis such as this may be caused by many organisms, but Salmonella spp. was isolated in this case. Toxoplasma gondii should also be considered. The normally well outlined liver lobules of the pig are clearly shown here. Focal necrosis may not be seen grossly in all cases.

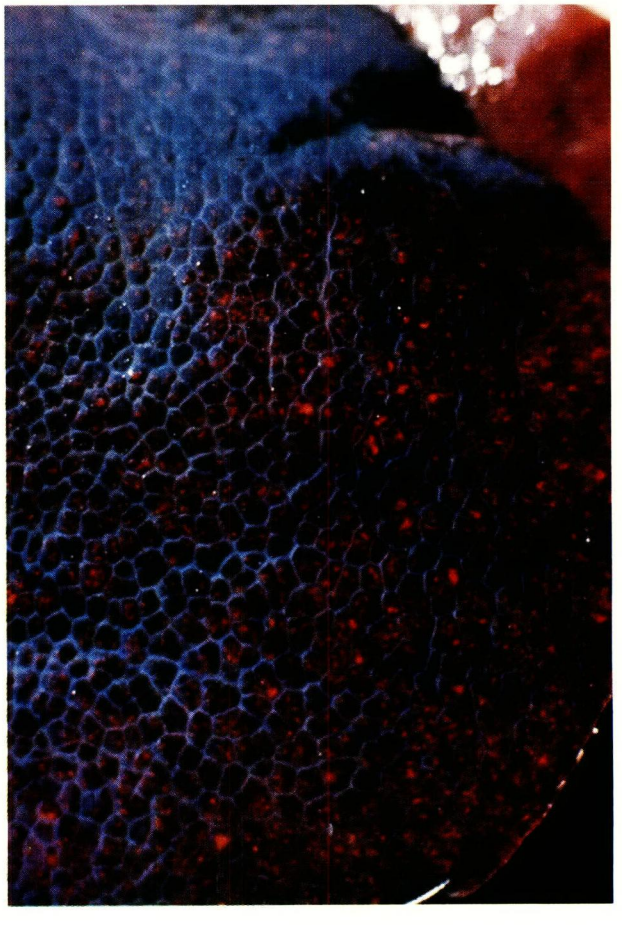

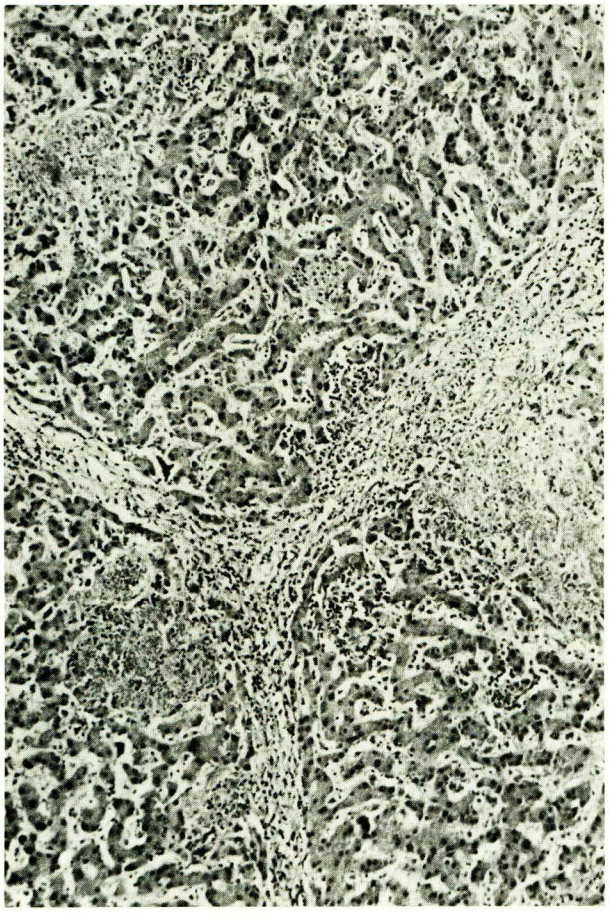

PLATE 145: FOCAL NECROSIS

Both along the septa and scattered in the sinusoids are many small round cells mostly lymphocytes, monocytes and plasma cells. Also scattered are several foci of a more granular appearance with loss of cellular detail to the cord cells and a few round cells, mostly neutrophils, associated with them. These are the areas of focal necrosis and with higher power, one may find the organism in and about these as well as scattered in the parenchyma and stroma. Many organisms can cause such a lesion but Toxoplasma spp. was found in this case. In toxoplasmosis, the lesion is often more necrotic than cellular as is seen in some other infections such as histoplasmosis.

PLATE 146: FOCAL NECROSIS

This is a discrete focus of inflammatory cells, mostly neutrophils. They can be found scattered anywhere in the liver. This type of lesion is not definitive, but can be seen in many infections. Shigella spp. was isolated from this case. When one sees this lesion initially, one should examine the entire section or sections to find evidence of multicellular organisms as migrating parasites could make such a lesion. If none is found then an intensive search should be made in and around the lesion for protozoa. Inclusion bodies of a virus disease should be looked for next and finally the lesion must be examined for bacteria. Special stains may be necessary for differentiation and diagnosis.

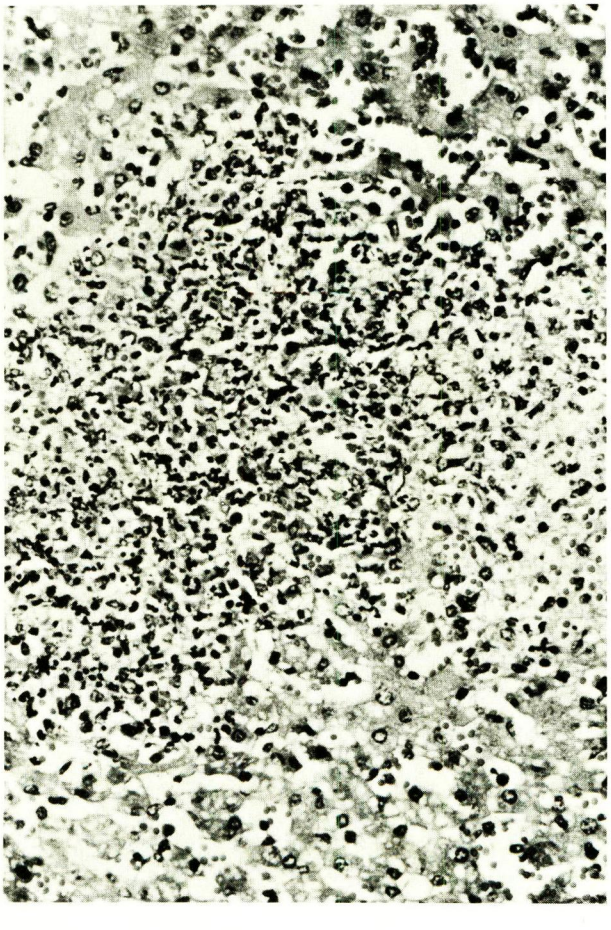

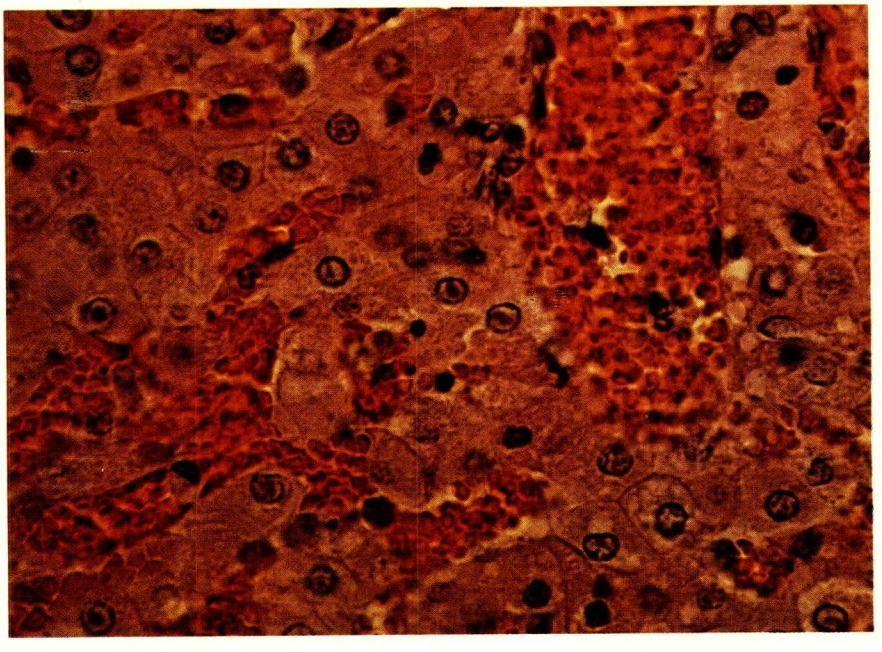

PLATE 147: INTRANUCLEAR INCLUSION BODIES

Scattered in many of the nuclei of the hepatic cord cells are dark red to purple distinct bodies. A margination of the chromatin is seen in these nuclei also. These bodies are the inclusion bodies of equine viral rhinopneumonitis in the liver of an aborted foal. Several virus diseases cause similar inclusions in the many animal species. It should be noted that all the inclusions are not of the same size or shape in the cord cells pictured above.

PLATE 148: PARASITIC CYSTS

The large number of cystic structures scattered in these pictured organs are the intermediate stage cysts of a tapeworm. In this case, they are the intermediate cysts of Echinococcus granulosa. Other cysts may have a relatively similar appearance. Inside these specific cysts may be thousands of viable scolices, while most other types of tapeworm cysts have only one or a few viable "daughter cysts". The dog is the definitive host of this parasite, while the intermediate hosts having this type of cyst are cattle, sheep or pigs. A similar relationship is seen with the other tapeworm species.



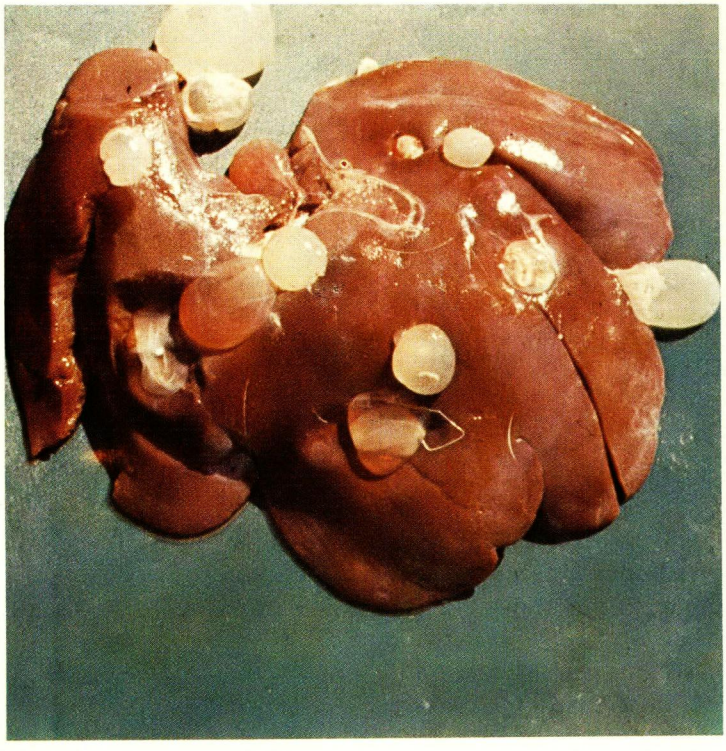

PLATE 149: PARASITIC CYSTS

The pale white, usually translucent cysts are attached to the liver capsule having formed just under or in it. Most of these are soft and filled with a clear fluid. The fluid may be cloudy if the parasite is dead. Attached at one area on its inner wall is a small tag of opaque white tissue, the inverted scolex. This one was identified as Cysticercus spp., but there are other intermediate forms of tapeworm cysts that can also be found in the mesentery and peritoneum. In general, most are found near the hilar regions of the major organs. It should be noted that these are mostly pedunculated while hydatid cysts are embedded in their host tissue.

PLATE 150: ASCARID SCARS (MILK SPOTS)

The pale white to greyish foci scattered on the liver are areas of capsular and subcapsular fibrosis caused usually by migrating ascarid (Ascaris lumbricoides) larvae in the pig. These fibrotic lesions may be seen with less facility throughout the liver. A few may have a reddish to yellow core from debris and blood accumulation. Until recently these were considered to be caused by ascarids only. Other parasites are now known to cause them. Histologically, one may look at many of these spots before a section of parasite is found. The number of lesions may vary from one or two foci to moderate cases like this one, or to massive involvement making the entire capasule whitish.



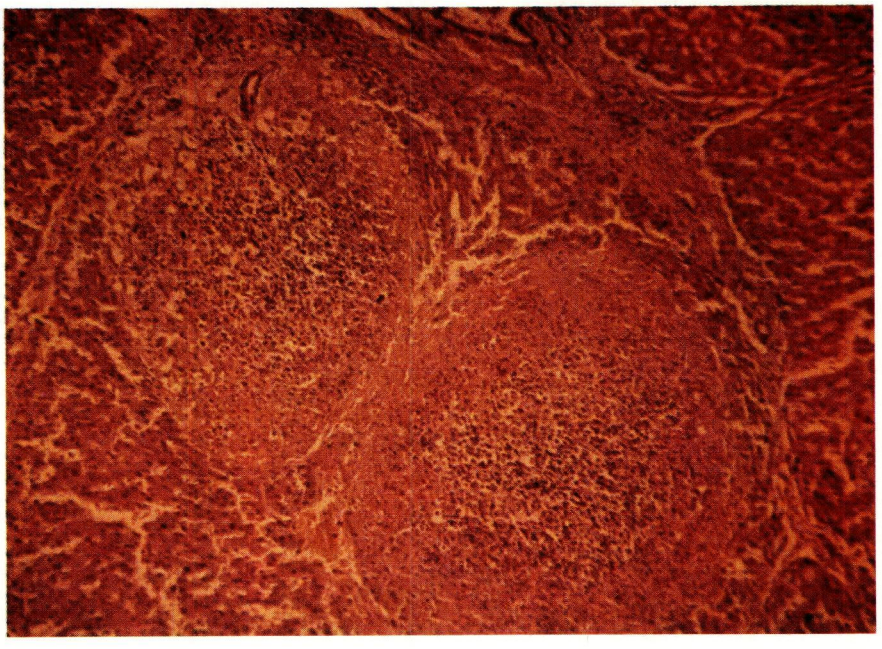

PLATE 151: PARASITIC GRANULOMAS

These two discrete foci, with many inflammatory cells centrally and early connective tissue production at the periphery, are typical of a parasite migration path of subacute duration. They would be less discrete if younger and more discrete and walled off if chronic. While ascarids commonly do this, other parasites can as well. One may have to examine many of these lesions to find the parasite itself.

PLATE 152: CHRONIC CHOLANGITIS

The several large pale streaks seen on the cut surface of this pig's liver represent the biliary areas that are affected with chronic cholangitis as a result of a fluke infection. The parasite, Clonorchis sinensis, was identified from this liver. Normally, one does not see the biliary tracts this easily.

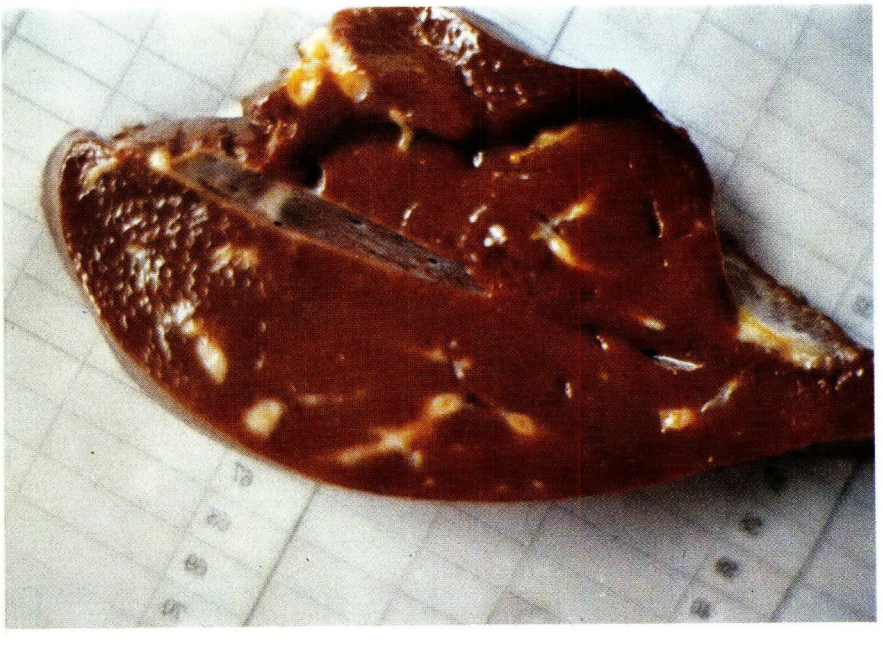

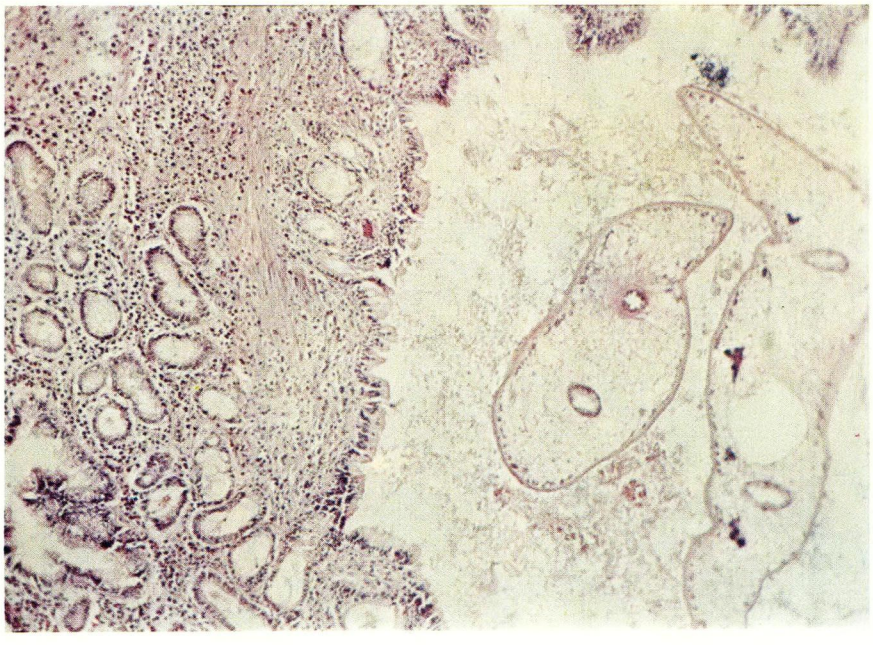

PLATE 153: PARASITIC CHOLANGITIS

Two sections of the fluke Opisthorchis sinensis (Clonorchis sinensis) are seen in this bile duct. The surface epithelium is normal, but many small round cells (chronic inflammatory cells) are seen scattered in the mucosa proper. Locally extensive biliary fibrosis may result from this type infection.

PLATE 154: METASTATIC ADENOCARCINOMA

The multiple, uniform nodules in this dog's liver are foci of a pancreatic duct carcinoma that spread by way of the portal circulation to the liver (metastases). The indented central portions are thought to be the result of degeneration of the oldest portion of the metastatic nodule with subsequent absorption and shrinkage. The still viable neoplastic cells are forming the pale tissue collar around the central depression. Such a uniform distribution of metastatic neoplasm is not common. It is often difficult to differentiate some of the tumors that originate from the same embryological anlagen such as the bile duct and pancreatic duct neoplasms.

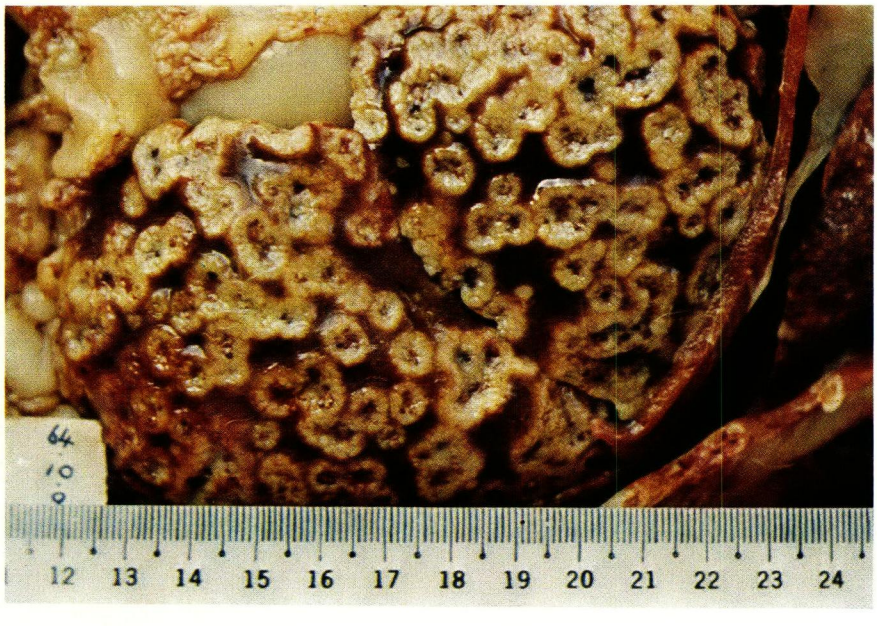

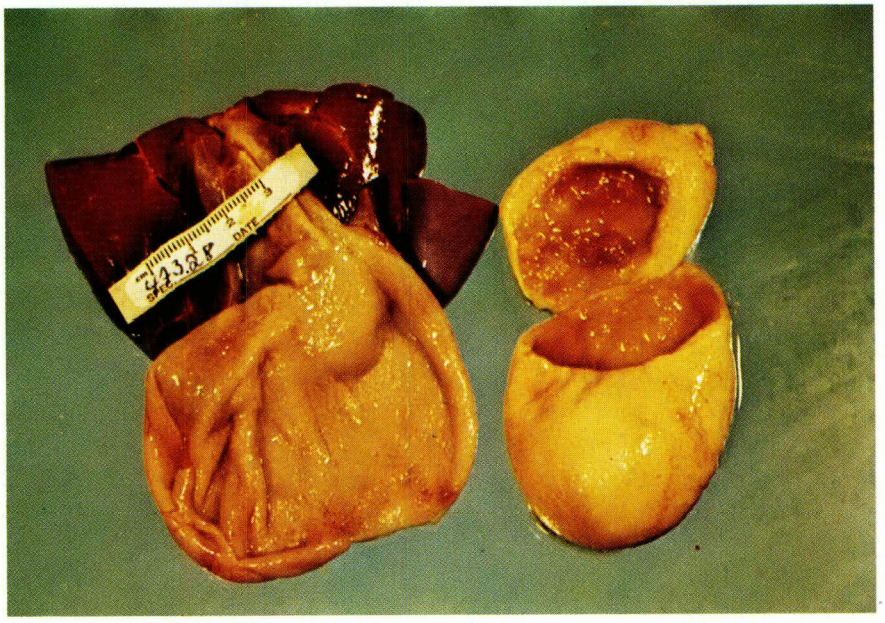

PLATE 155: FIBRINOUS CAST OF GALLBLADDER

This calf's gallbladder has been opened and a yellow, fibrinous replica easily peeled out of it. On culture, Salmonella spp. was isolated. In all cases seen like this, Salmonella has been isolated. Other lesions may or may not be present. The gallbladder itself, other than being slightly thicker, is not remarkably abnormal. This can be considered one of the few pathognomonic lesions known.

PLATE 156: CYSTIC HYPERPLASIA OF THE GALLBLADDER

The multiple, large, dark and smaller, lighter cysts on the surface of this gallbladder are a common form of hyperplasia in the dog. The dark color of some cysts is due to their content of inspissated and bile stained secretion while the lighter ones are apparently younger and less stained with bile. They are almost never of any clinical importance. The cause is unknown.

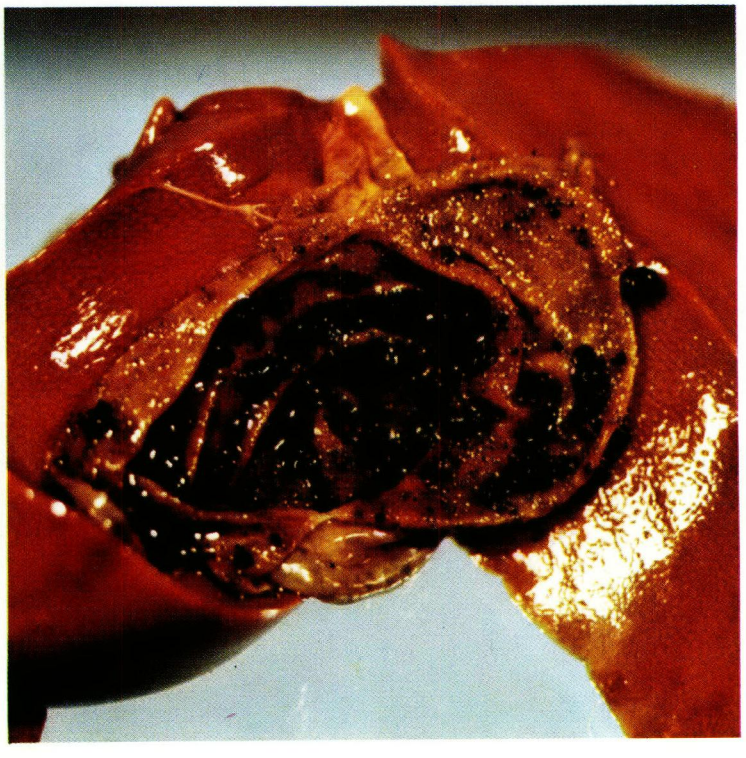



PLATE 157: PANCREATIC HYPOPLASIA

The duodenum with the entire pancreas is attached to this dog's mesentery, but the pancreas is greatly reduced in size from normal. There is no fibrosis or contraction of the mesentery or other tissues. This shows that the pancreas had probably never grown to normal size and thus this lesion represents true hypoplasia. Histologically, the ducts were considered almost normal, but the acinar structures had failed to develop. This is considered to be a genetic problem.

PLATE 158: PANCREATIC HEMORRHAGE

The blood infiltrating around the various lobules of this pancreas are hemorrhages. This lesion is a common terminal one in many species and usually is not diagnostic. If a slight amount of edema and fibrin are also present, one should consider the possibility of acute necrotic pancreatitis. This case was from a pig with a suspected Vit K deficiency.



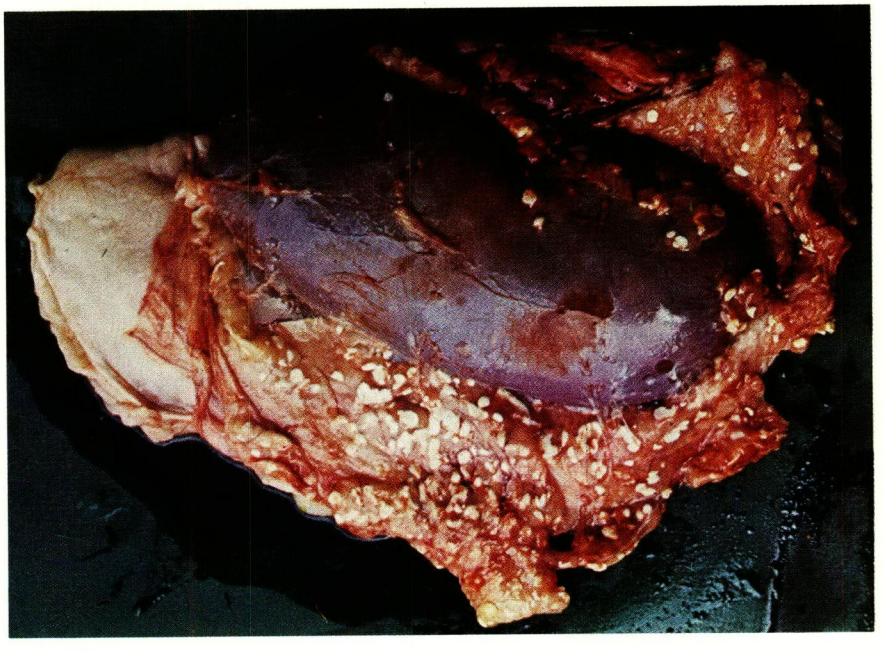

PLATE 159: FAT NECROSIS

The discrete, pale, firm foci scattered about this kidney are areas of fat necrosis. It was found about both kidneys in this pig. There are several forms of fat necrosis with well established causes. Traumatic fat necrosis is found associated with the area traumatized. Pancreatic fat necrosis has its primary lesion in the pancreas allowing pancreatic juice to escape and enzymatically cause fat necrosis locally. In cattle and sheep, numerous 1-3 mm. foci of terminal soap formation in depot fat is thought to be related to nutrition and is a common postmortem finding. No answer is forthcoming for this pig which died with hemophilus pneumonia, but its high temperature from the pneumonia may have played a role.

PLATE 160: PANCREATIC FAT NECROSIS

A portion of normal pancreas is present with an area of almost normal adipose tissue separated by a zone of necrotic fat recognized by its amorphous, finely granular appearance. A proliferation of some fibroblasts is seen at the edge of the necrotic fat.

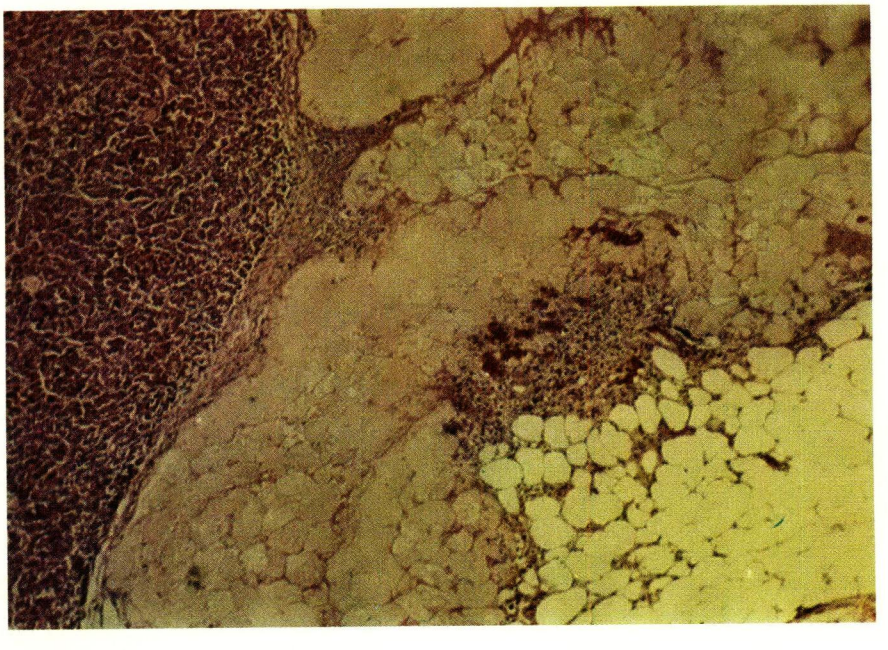

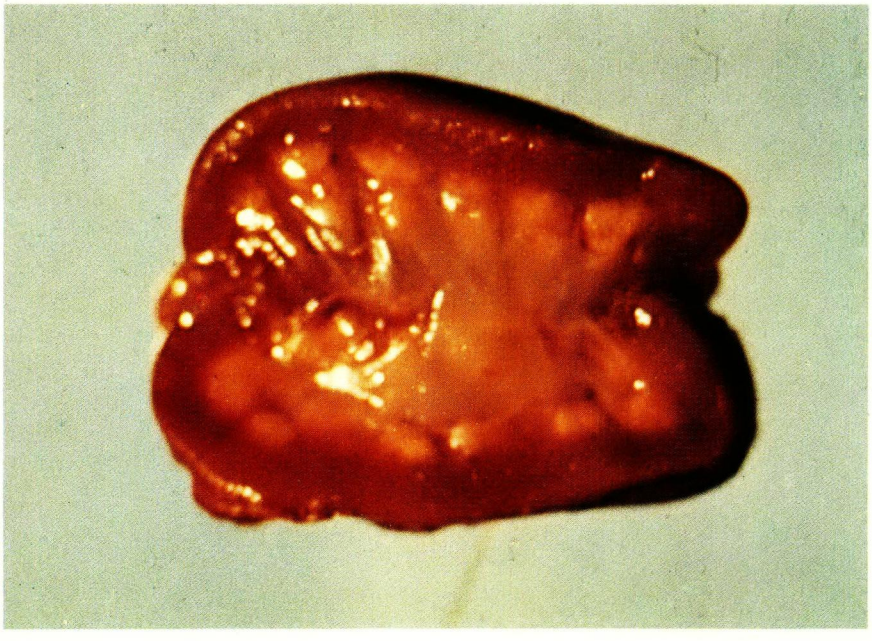

PLATE 161: DEHYDRATION SALTS

The discrete pale zone in the medullary substance of each pyramid is formed by urinary salts not being flushed out. These are water soluble and indicate that the animal has not been drinking enough fluids or was losing fluids as from diarrhea just before it died. Being water soluble, they will not be seen in tissue sections as they will also be washed out in processing. In some cases, these salts are limited more to the papillae proper, and in others they are located in a distinct layer at the C-M junction. These are to be differentiated from other chemicals such as sulpha drugs, which cause a degeneration (nephrosis) with swelling of the tissues in the area involved.

PLATE 162: SEROUS ATROPHY OF FAT

In the hilar area of this kidney, the nerves and vessels which are usually buried in fat are easily seen in a clear, gelatinous material (serous atrophy of fat). The fat has been utilized in this chronically starved animal and replaced by a serous type material.





PLATE 163: PSEUDOMELANOSIS

This black discoloration on one kidney was also on the other kidney which was turned over for the picture to show the contrast. This is called pseudomelanosis and it is the result of the blood being acted upon by hydrogen sulfide from adjacent bacterial laden tissue, in this case the bowel. The more vascular organs are the ones most likely to show this artefact, such as the kidney, adrenals, liver, spleen and bowel proper. It can occur within minutes of death, but usually it takes longer.

PLATE 164: CONGESTION ARTEFACT

The distinct vermiform (wormlike) appearance of this kidney surface is the result of postmortem intestinal pressure on the kidney forcing blood out of some areas and not others. This can be seen in any tissue or organ where such pressures can be exerted.

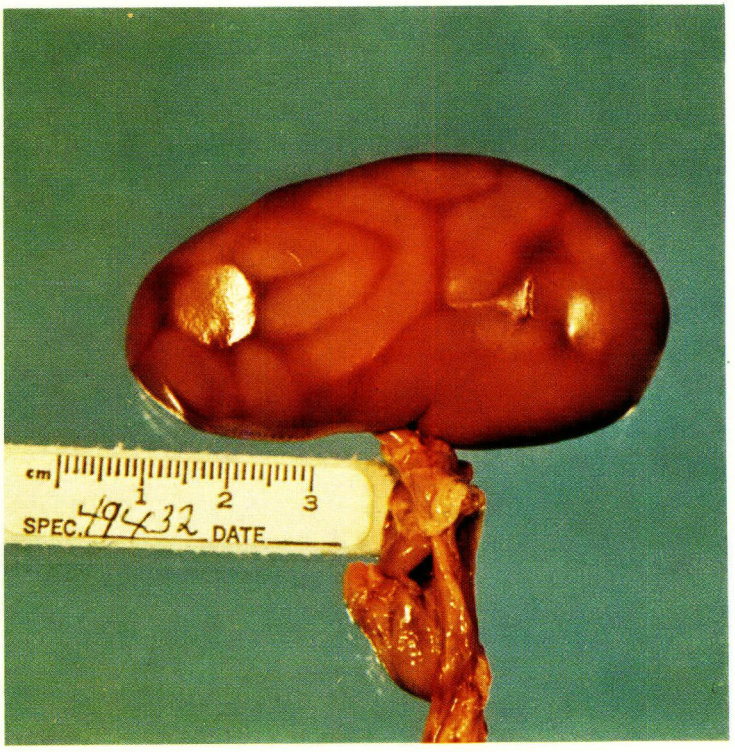

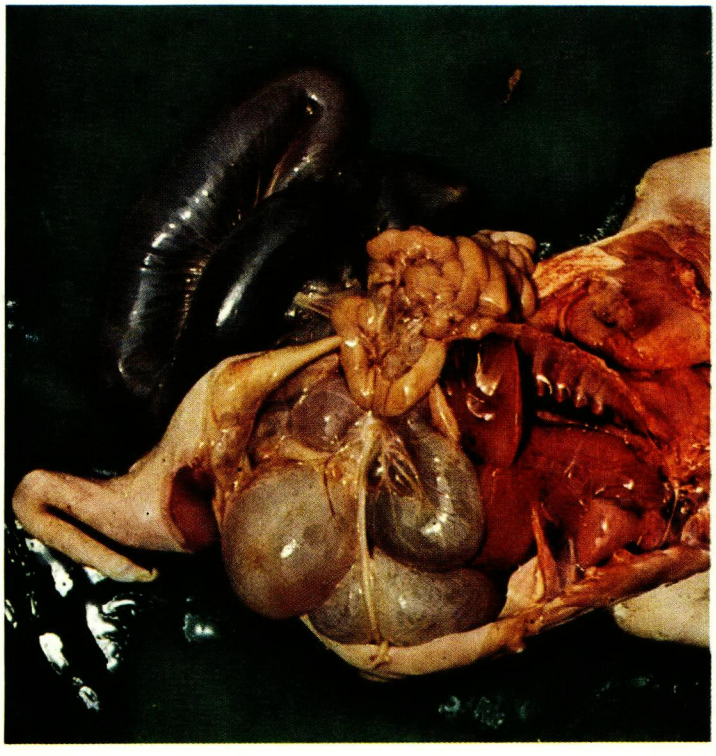

PLATE 165: PERSISTENT URACHUS

This anomalous fetal body shows a malformed caudal half with the abdomen opened for necropsy. A full bladder is nearest to the malformed limb and pelvis. Slightly cranial to the bladder is another cystic mass also filled with urine, the persistent urachus. A fibrous strand, the remnant of one umbilical artery is lying across its caudal third and a dilated loop of colon is lying on it dorsally. The coils of colon are all dilated abnormally as a result of a segmental gut defect not shown in the picture. The lack of one hind limb is an example of amelia while peromelia is the term to describe the failure of the distal portions of the limb to develop.

PLATE 166: RENAL APLASIA

In one of the two piglets pictured, both kidneys are entirely absent (aplasia). This is to be differentiated from hypoplasia in which they are present but have failed to grow normally. This rather common anomaly is often associated with other anomalies such as those of the genitalia or vertebrae.



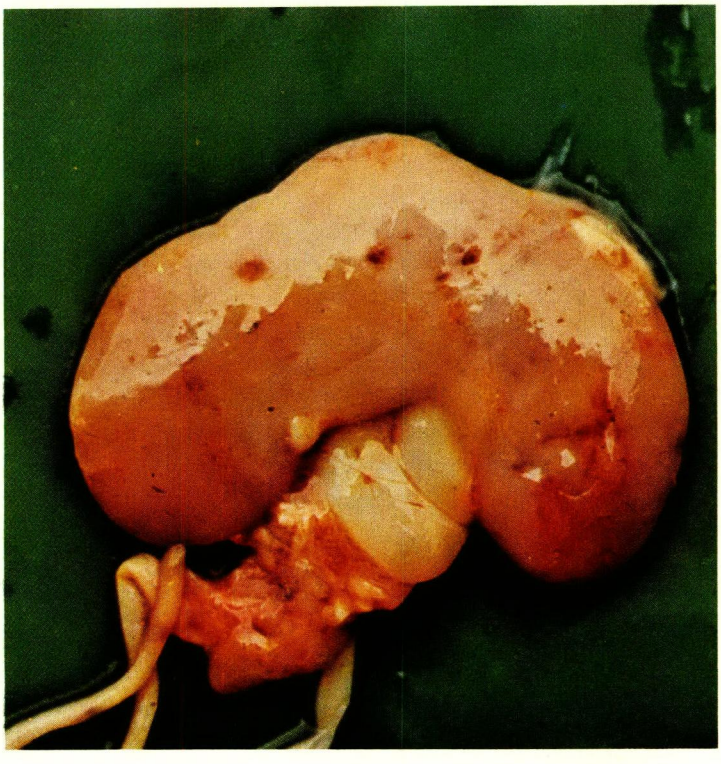

PLATE 167: HORSESHOE KIDNEY

The partially curved, single, enlarged kidney in this piglet is an anomaly apparently due to failure of the individual renal anlagen to separate. A partially coiled, dilated ureter is seen at its hilus. Most of these are compatible with life if other problems are not present.

PLATE 168: UNILATERAL POLYCYSTIC KIDNEY

One kidney is normal as are both ureters, but the other kidney is about twice normal size because of the many cystic spaces in the parenchyma. This congenital anomaly is usually bilateral and is most common in cats and swine. Surprisingly, animals may live a normal lifespan with polycystic kidneys, but most die young or soon after birth when the mother's placental filter is not present anymore. The effect on the host is related to the size and number of cysts present and the functional state of the remaining nephrons.





PLATE 169: UNILATERAL HYDROURETER

The extremely dilated ureter has of necessity caused an elongation of its length leading to its marked tortuous appearance. The other ureter is smaller but also slightly dilated and tortuous. There is some hydronephrosis in the kidney with the larger ureter as seen by the bulge of the renal pelvis at its hilus. The cause of this was an anomalous segmental defect at the distal end of the markedly enlarged ureter.

PLATE 170: HYDRONEPHROSIS AND HYDROURETER

This bilateral lesion is made evident by the markedly dilated renal pelvis and calyces in the opened kidney and the dilated ureters. Both kidneys were soft and fluctuated slightly on palpation before opening. Most cases have a visible, morphological obstructive lesion to outflow somewhere in the urinary tract, often at the entrance to the bladder or in the urethra. There are some cases, especially in pigs, in which only a functional stenosis is found at the distal end of the ureters as in this case, or in only one ureter if the lesion is unilateral. No cause is known for this functional obstruction.

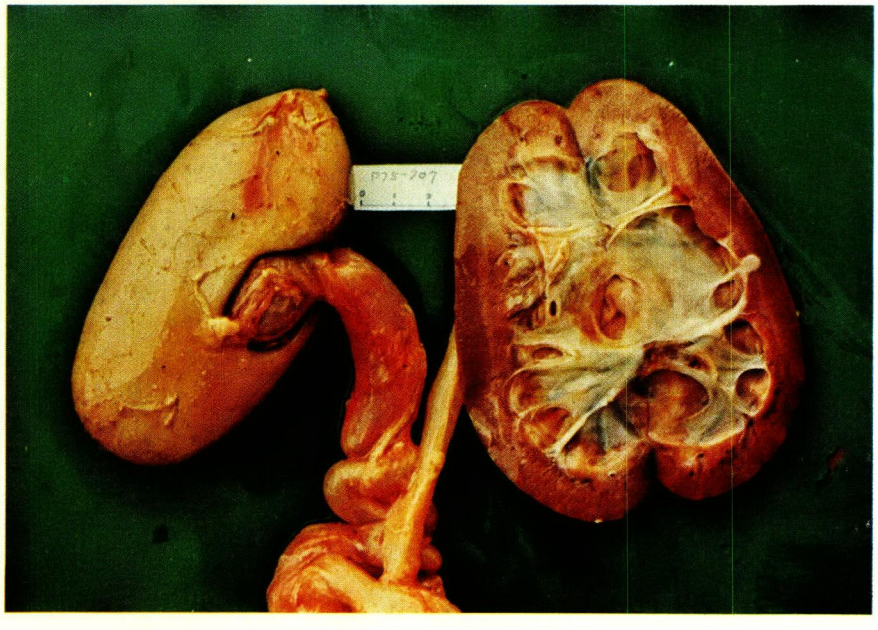



PLATE 171: CORTICOMEDULLARY (CM) JUNCTION HEMORRHAGE

The dark red areas of hemorrhage are seen at the junction between the cortex and medulla of most of the pyramids. This is the result of an acute urinary obstructive lesion farther down the urinary tract with retrograde pressure increase causing the lesion. This pig had urethral calculi blocking the urethra. A solitary renal cyst is present in one pole just under the cortex and is an incidental lesion, most probably congenital.

PLATE 172: RENAL HEMATOMA

The large renal mass of blood shown in one kidney and a smaller one in the other kidney are hematomas. The other half of one kidney shows a massive subcapsular hematoma. The urinary bladder has a mixed urine and blood clot in its lumen as a result of the hematuria in this suspected Vit K deficient piglet. It is of interest in this natural case that renal lesions were prominent findings. Other defects in the blood clotting mechanism of animals may have similar lesions.





PLATE 173: RENAL PELVIS HEMORRHAGE

As was seen in the gross, this histopathological picture shows the marked congestion and hemorrhage under the pelvic epithelium. Again it should be stated it is a common lesion with septicemias in general, although this came from a case of hog cholera.

PLATE 174: PETECHIATION OF THE KIDNEY

While this is a severe case, there are many cases in which only one or two pin point spots of hemorrhage (petechiae) may be seen. They are quite common in several systemic diseases including hog cholera, but by themselves they are not diagnostic. Kidneys with this many petechiae are often referred to as "turkey egg kidneys".





PLATE 175: RENAL CONGESTION

This young piglet had a heart anomaly which caused these dark red, passively congested kidneys.

PLATE 176: TERMINAL INFARCTS

The several discrete, irregular red areas seen on the surface of these pale kidneys extend down to the corticomedullary zone. They have a very slight reddish zone around some of them. Histologically, very early degenerate changes of the tubules in these areas may be seen. Congestion of the area with a very few neutrophiles at the periphery may be seen especially if the animal lives a few hours. These are quite common in many species as the cow, horse and dog and often, but not always, are associated with I.V. therapy. Many are associated with severe toxemias as from endometritis, as in this pig, and they may represent disseminated intravascular coagulation (DIC) sequelae.



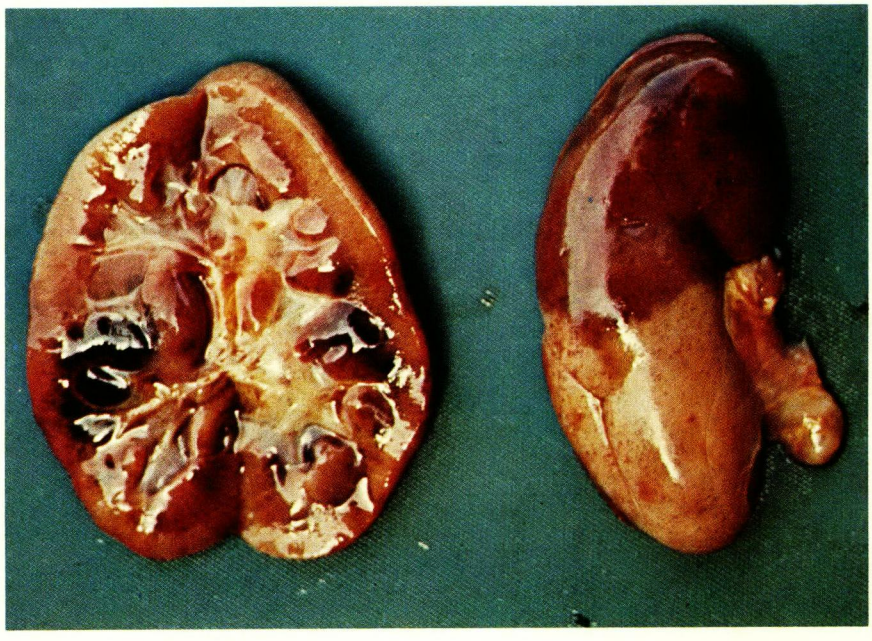

PLATE 177: INFARCTION

The red areas in the opened kidney and the entire half of the unopened kidney are areas of acute hemorrhagic infarction which were caused by emboli from a vegetative endocarditis in this piglet.

PLATE 178: POLAR INFARCTS

At both poles of each kidney in this dog, there are discrete, wide, coneshaped areas of hemorrhage that extend from the pelvic surface to the cortical surface. The hemorrhage is more apparent in the medullary area. Infarcts of such a bilateral and extensive nature, even if limited to one pole should make one consider a neurogenic cause as from a spinal cord lesion with or without subsequent bladder malfunction to cause urinary back pressure. Vertebral fractures in most species and prolapsed intervertebral discs in dogs are often in the history of such cases.





PLATE 179: RENAL CORTICAL NECROSIS

The medulla is essentially normal. The corticomedullary junction area is red with congestion and hemorrhage which extends out along vessels into the cortex as finger like projections. The major portion of cortex is dull and pale, and histologically, the majority of cells are dead or degenerating with well marked thrombi in several large veins at the border of the infarct. It is difficult to establish if these thrombi are cause or effect. A generalized skin erythema with capillary damage was also present in the ventral areas of this pig's body. The cause is unknown.

PLATE 180: RENAL INFARCTION

The fainter, relatively bloodless area is the area of dead renal tissue (infarct), and the remaining tissue is the congested and hemorrhagic border. A small vessel has a fibrin thrombus filling the lumen. The thrombus could be the cause by vascular obstruction or it could also be an effect of stasis in the area of infarction. A diagnosis of disseminated intravascular coagulation (DIC) cannot be ruled out.

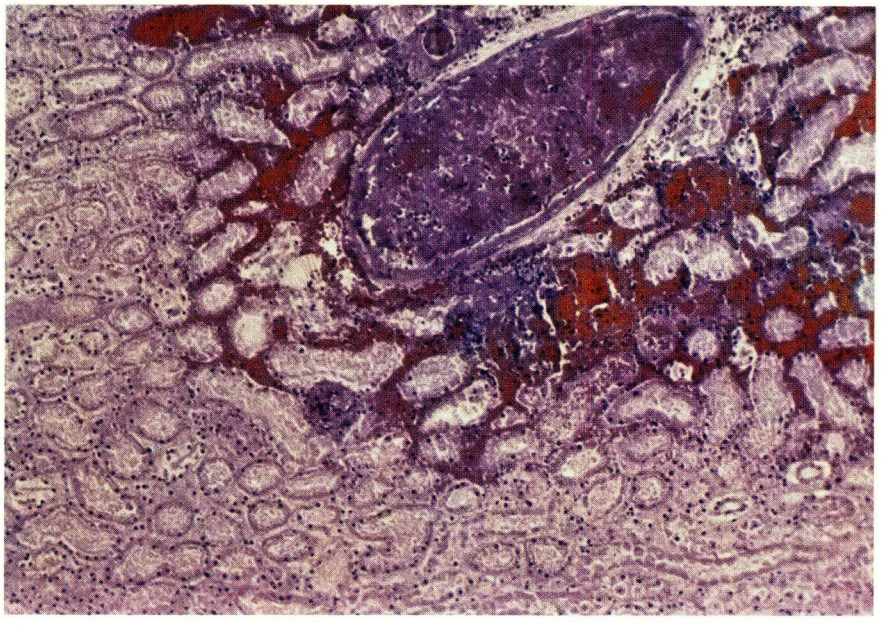

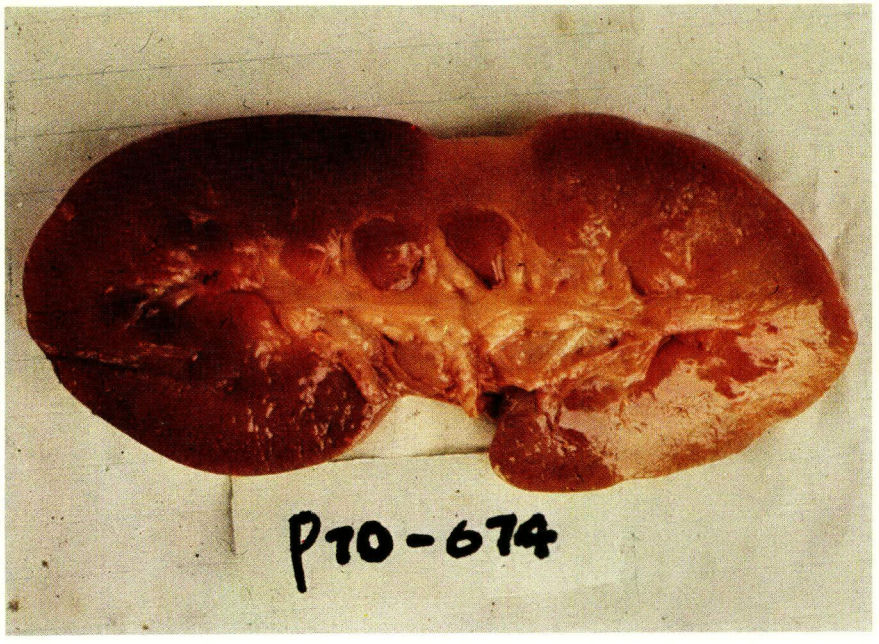

PLATE 181: HEALED INFARCTION

The depressed, straight surfaced lesion on a square area of cortex is the result of a vascular obstruction with subsequent degeneration and final shrinkage. This chronic infarct has no evidence of an acute reaction such as hemorrhage, congestion or edema. The larger square opening is the normal hilar area of the kidney. Emboli from a left sided vegetative endocarditis is a possible cause while many are without a known cause (idiopathic).

PLATE 182: HEALING INFARCTION

This area could represent any area of healing in the kidney and not just an infarct. The increase in the number of cells lining the tubules demonstrate tubular regeneration. The increase of interstitial tissue is mostly connective tissue being either absolute fibrosis, an increase of recently formed connective tissue, or relative fibrosis, the result of coalesced preexisting connective tissue. The scattered round cells suggest prior inflammation. One glomerulus is almost normal but the other is shrunken (atrophic) with a relative, not absolute, dilatation of Bowman's capsule.

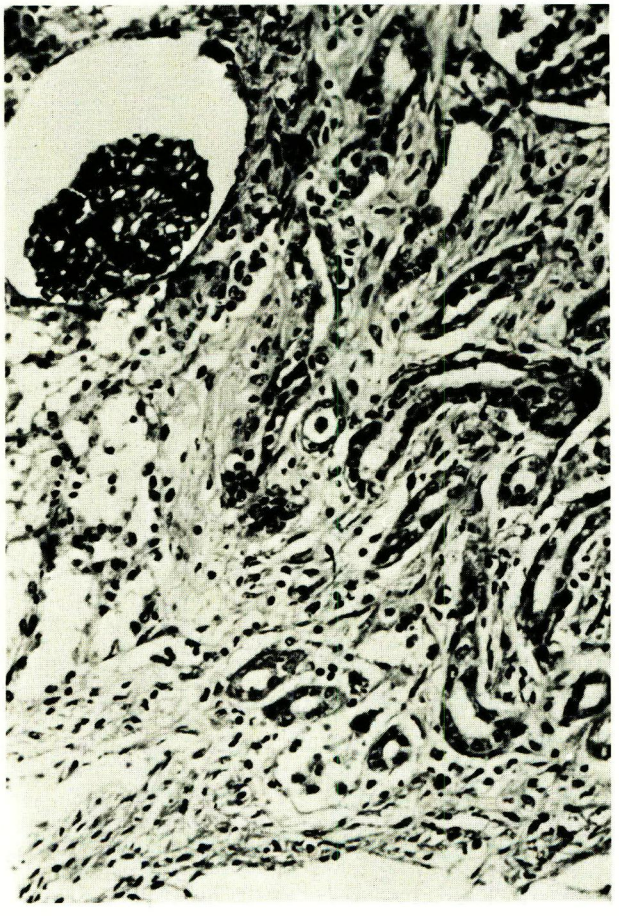



PLATE 183: GLOMERULONEPHROSIS

In this form of nephrosis, the kidney is swollen, pale and has indistinct cortical striations. It is usually difficult to tell the type of nephrosis from the gross. This kidney lesion is a severe case as the marked bulging character of its cut surface suggests. Many toxic agents, both biological and chemical, as well as some physiological factors such as shock may cause nephrosis. In lower nephron nephrosis from shock the major bulging is nearer the medullary area more than in the cortex.

PLATE 184: EARLY GLOMERULONEPHROSIS

The slight thickening of several vascular loops in this glomerular tuft, along with some apparent endothelial proliferation as demonstrated by the increased cellularity and even a mitotic figure, suggest that this is an early mild lesion. The small clumps of round cells may just represent blood stagnation in the glomerulus.

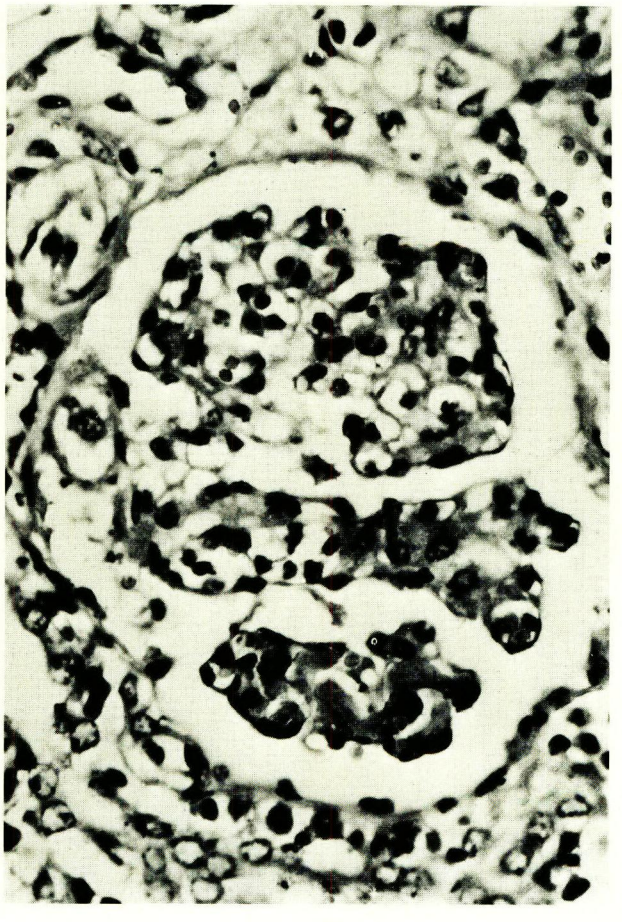



PLATE 185: NEPHROSIS

This kidney is larger, paler and firmer than normal. It lacks the usually well defined cortical striations seen in normal kidneys of most animal species. The capsule peeled off easily. The swollen character is best seen when the kidney is longitudinally bisected. The cortex tends to bulge more from the cut surface than the medulla in cortical and glomerular types of nephrosis. In medullary types of nephrosis, such as in lower nephron nephrosis, the medulla or even the corticomedullary area may bulge more than the cortex. This noninflammatory disease (nephrosis) of the kidney is to be differentiated from its inflammatory (nephritis) counterpart. Hemorrhage, purulent debris and focal inflammatory cell invasion, grossly and microscopically, would all tend to suggest "itis" rather than "osis". This pig died from lead poisoning.

PLATE 186: ACUTE TOXIC NEPHROSIS

One glomerulus is markedly congested and the other has been almost completely replaced by a pink, homogeneous, hyaline material (protein) and a few cells. Several tubules are dilated with the same pink material and have almost completely lost their epithelial lining. Several tubules have their more normal basophilic lining epithelial cells present with their nuclei still intact. These latter tubules are still viable while the other tubular lining cells are dead or dying. This acute toxic nephrosis was caused by mercury poisoning.

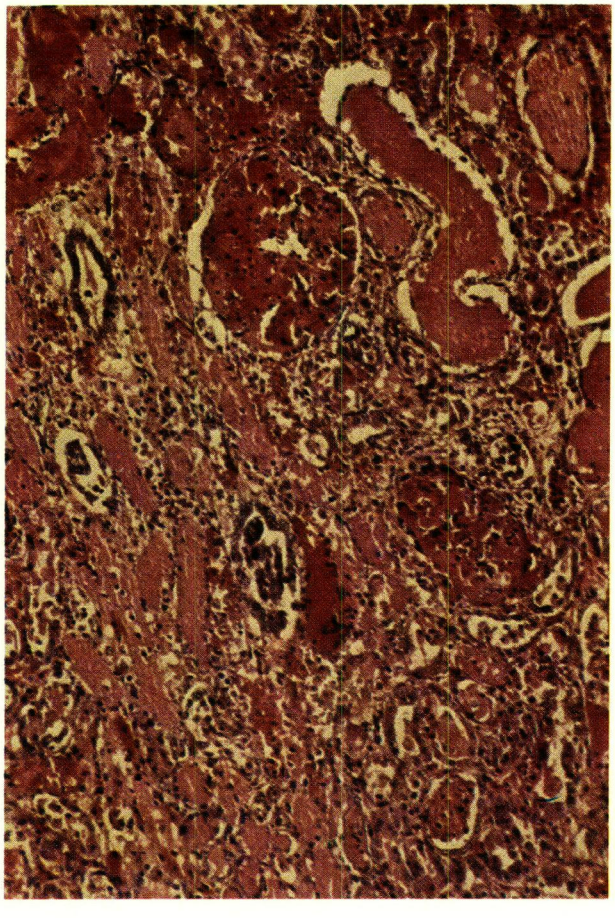

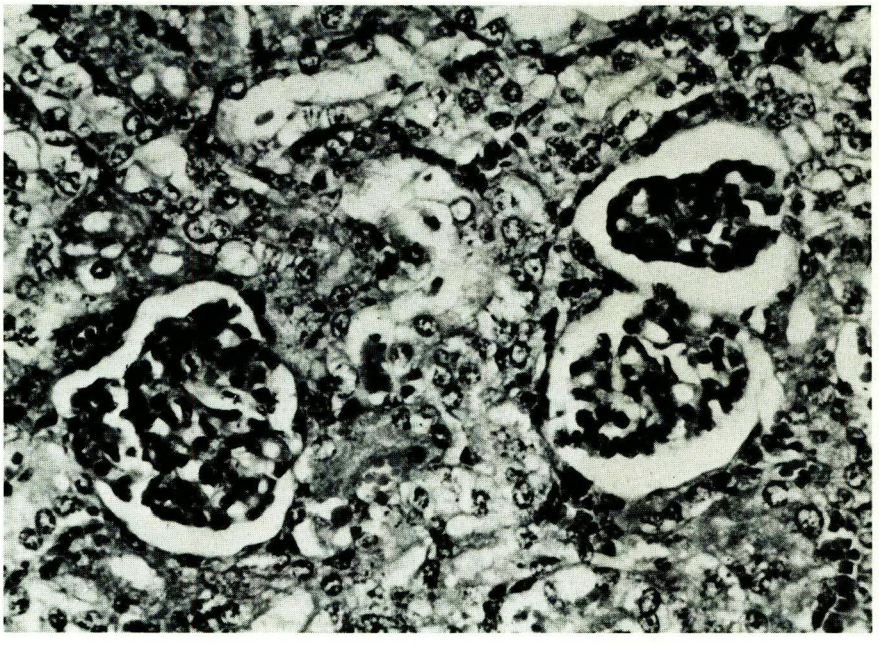

PLATE 187: SUBACUTE NEPHROSIS

The enlarged tubular epithelial cells, with their enlarged vesicular nuclei, making many of their lumens almost indistinguishable, and minimal inflammatory cell response demonstrates well this process of nephrosis, a non-inflammatory degeneration of the kidney. The pile up of cells lining the tubules also indicate this to be evidence of tubular regeneration. The glomeruli are slightly hypercellular with a mild degree of basement membrane thickening. Some cellular prolife ration of Bowman's capsule can be seen. Toxic agents both chemical and biological can cause this reaction.

PLATE 188: ACID FAST INTRANUCLEAR INCLUSION BODIES

These intranuclear bodies can be suspected in regular hematoxylin and eosin (H & E) sections by the slight margination of chromatin and odd shaped or enlarged nucleoli like structures in the renal tubule epithelium. They are best demonstrated as seen here, with acid fast (AF) stains. Lead (Pb) is a common cause of these as in this poisoning case, but other heavy metal elements can also elicite them. They can also be found in liver cord cells, vascular endothelium in the brain, and even in osteoclasts.

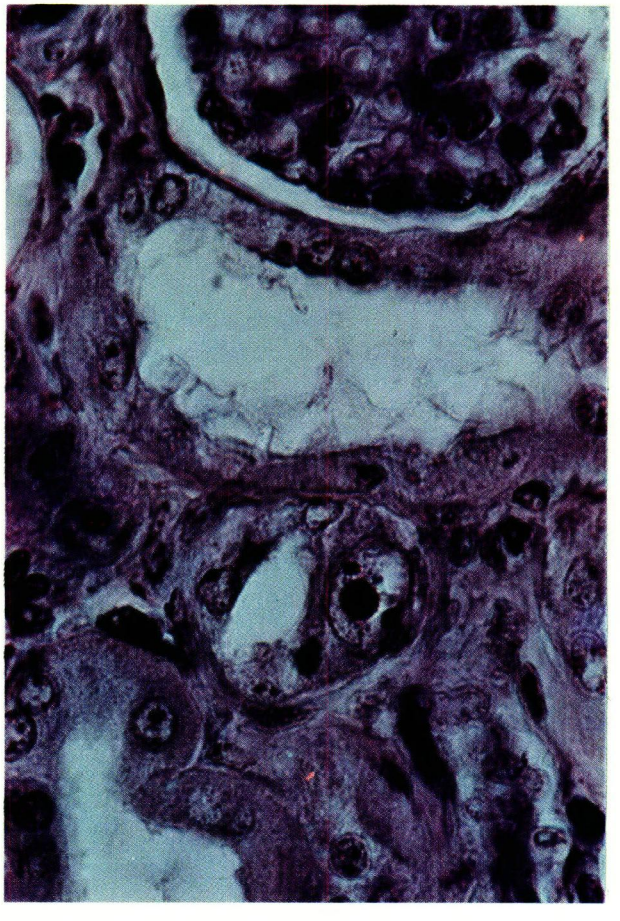

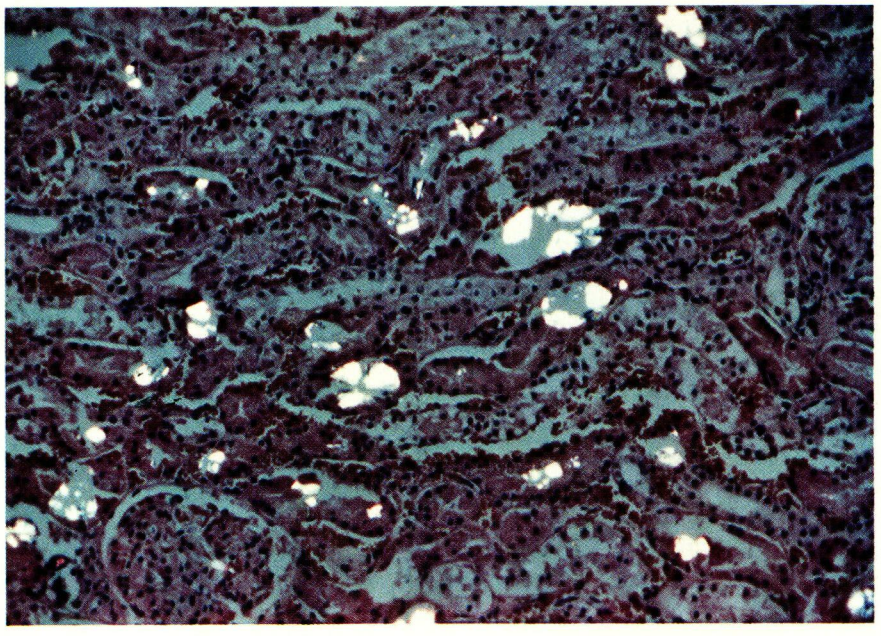

PLATE 189: OXALATE CRYSTALS

These white structures in the renal tubules are oxalate crystals which can and do obstruct and damage the tubules causing a nephrosis. It is surprising and well demonstrated here that animals can die, as this one did, with minimal lesions other than the crystals and apparent tubule blockage. These crystals can also be found in the vessels of the brain in poisoning cases. Oxalate containing plants and chemicals containing ethylene glycol such as antifreeze compounds are common sources of animal poisonings.

PLATE 190: BASEMENT MEMBRANE MINERALIZATION

These large dark clumps associated with the basement membrane of the renal tubules are clumps of a mineral, most likely calcium. Without prior damage to the area, they can be considered an example of metastatic mineralization as from uremia or toxic hypervitaminosis D. While this is in the kidney, it does not a priori dictate that it is a lesion of uremia, unless there is evidence for enough renal damage with other lesions to cause the uremia. A kidney with only this for a lesion suggests the cause may be a toxic level of Vit D.

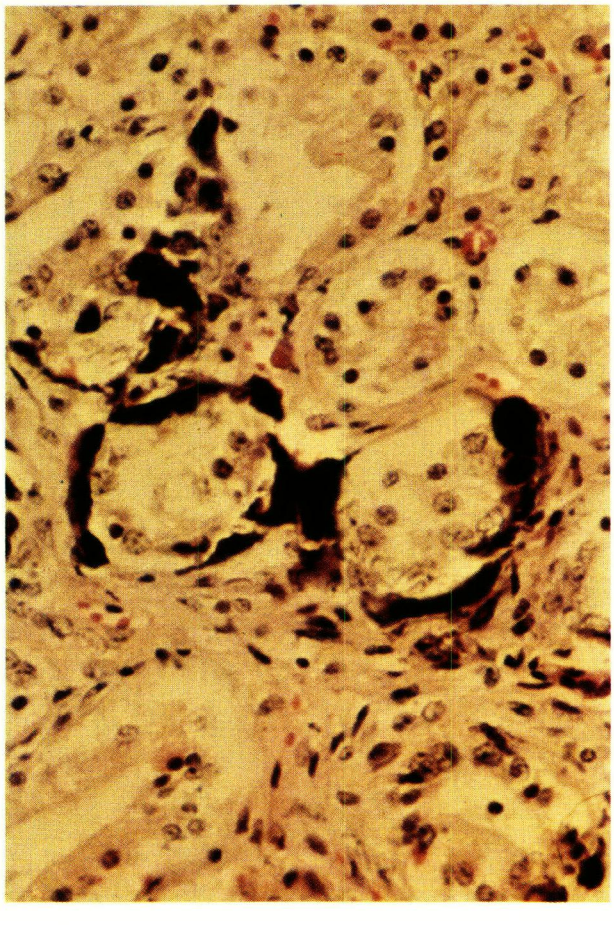



PLATE 191: GLOMERULAR AMYLOIDOSIS

The entire kidney was enlarged, pale and firm as with most nephroses. The cortex bulged from the cut surface when bisected. Aqueous iodine was put on the middle portion of the section in this picture and the numerous amyloid (starchlike) filled glomeruli showed up as tiny pin point brown spots. This is a case of "primary amyloidosis" as no chronic infectious process was present in the animal to make it a case of "secondary amyloidosis". Only a slight majority of cases show this positive iodine test.

PLATE 192: GLOMERULAR AMYLOIDOSIS

The homogeneous hyaline material in the glomerulus consists of amyloid (starchlike) deposits in the vascular tufts. Elsewhere in the kidney and other organs as the thyroid and intestines, it is seen in basement membranes of vessels and epithelial structures. When there is a known preexisting chronic infection associated with it, it is called "secondary amyloidosis" to differentiate it from "primary amyloidosis" in which no predisposing infection is present.



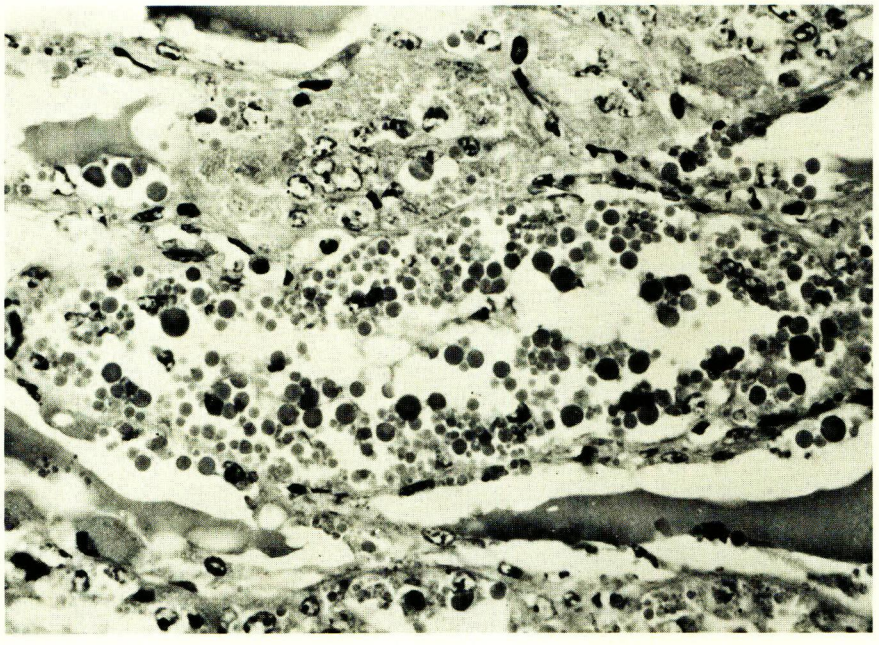

PLATE 193: RENAL TUBULE HYALINE DROPLETS

This is one of many types of casts found in renal tubules. This type is commonly seen in cases of amyloidosis and probably represents an altered filtration product. Other types of casts include oxalate and sulfa drug crystals, clumps of neutrophils, tubular epithelial casts, etc..

PLATE 194: HEMOGLOBINEMIC NEPHROSIS

The kidney is dark brown and the fat is slightly yellow (icteric) as a result of hemolysis in this cow. The renal lobulation is normal. The liver is fatty. Histologically, an acute noninflammatory degeneration (nephrosis) of the kidney is present as a result of the toxic effect of hemoglobin. The urine is dark if seen early in the disease, but later the urine may be unstained and the kidneys will still be dark. This lesion may be seen in cases of postparturient hemoglobinuria, as in this example, and in chronic copper poisoning in sheep.



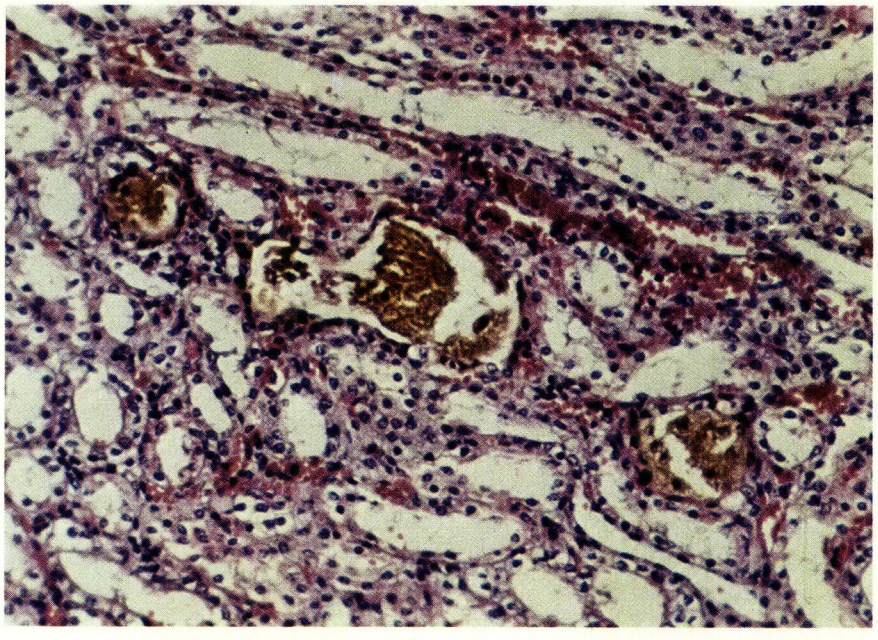

PLATE 195: RENAL BILE CASTS

Several renal tubules are dilated with brownish coarsely granular debris. The animal was icteric from severe liver disease and malfunction which led to the bile retention and subsequent urinary excretion of bile. With time the bile, which is a renal toxin, would cause "bile nephrosis" and renal failure. This is difficult to differentiate from hemoglobin or myoglobin, both of which are renal toxins and can cause "hemoglobinemic nephrosis" and "myoglobinemic nephrosis" respectively.

PLATE 196: BILATERAL PYELONEPHRITIS, HYDRONEPHROSIS AND HYDROURETER

Both kidneys are almost completely destroyed by the pressure of hydronephrosis and pyelonephritis. The ureters are markedly dilated and were filled with lumpy clumps of pus and debris. Only the darker areas of renal parenchyma are near normal and are what kept the animal alive this long as the pale areas are chronically affected and even fibrosed. Sometimes a hydronephrosis may be primary and subsequently gets infected, but the reverse is more likely to occur.





PLATE 197: PYELONEPHRITIS

The several dark red areas scattered in this kidney are minor calyces filled with bloody purulent debris which could be easily washed from these spaces leaving an irregular eroded calyx wall. Streptococci were cultured from this case. The lesion could not be seen from the renal surface nor was a lesion present in the bladder or ureters. Hematuria was present.

PLATE 198: PYELONEPHRITIS

The several scattered, slightly elevated areas are the areas of purulent inflammation extending into the cortex from the renal pelvis and dilated ureter. Very tiny, yellowish foci can be seen within these swollen areas. These all appear to be of the same age. Many different organisms may be isolated from such cases. A specific organism commonly seen in cattle is C. renale.



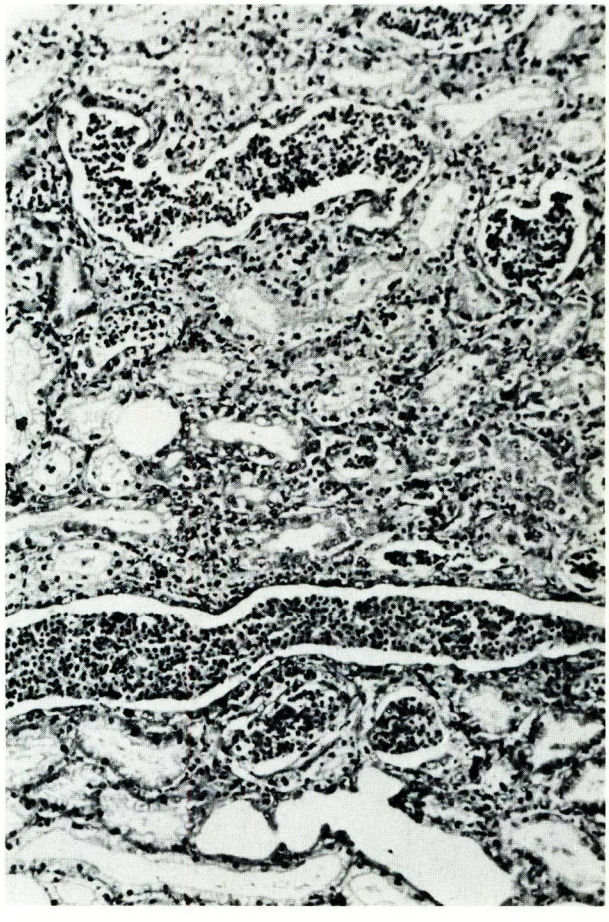

PLATE 199: SUPPURATIVE NEPHRITIS

This shows a marked number of neutrophils in tubules. The few glomeruli present are essentially normal. This is a case of "ascending pyelonephritis" as the infection was initially in the bladder from where it "ascended" up the ureter to the kidney. Out of context, such a lesion might also be seen near an abscess that had embolized to here from a vegetative endocarditis. It would be a "descending pyelonephritis" if it spread to the renal pelvis. There are some who consider that pyelonephritis in cattle caused by C. renale is ascending, while others consider it a descending infection.

PLATE 200: EMBOLIC ABSCESSATION

These discrete cellular foci were grossly visible mostly in the renal cortex, as small yellowish spots, some of which had a reddened periphery. These are made up of masses of inflammatory cells, mostly neutrophils, and some have bacterial colony clumps in their centers. Many of these foci are within glomeruli proper. This can be termed a "bacterial nephritis" as distinguished from a nephrosis. This is a characteristic finding in shigellosis of foals, and Shigella equirulis (Actinobacillus equirulis) was cultured from this foal's kidney. In other species an embolic shower from a left heart vegetative endocarditis can be expected to cause this.

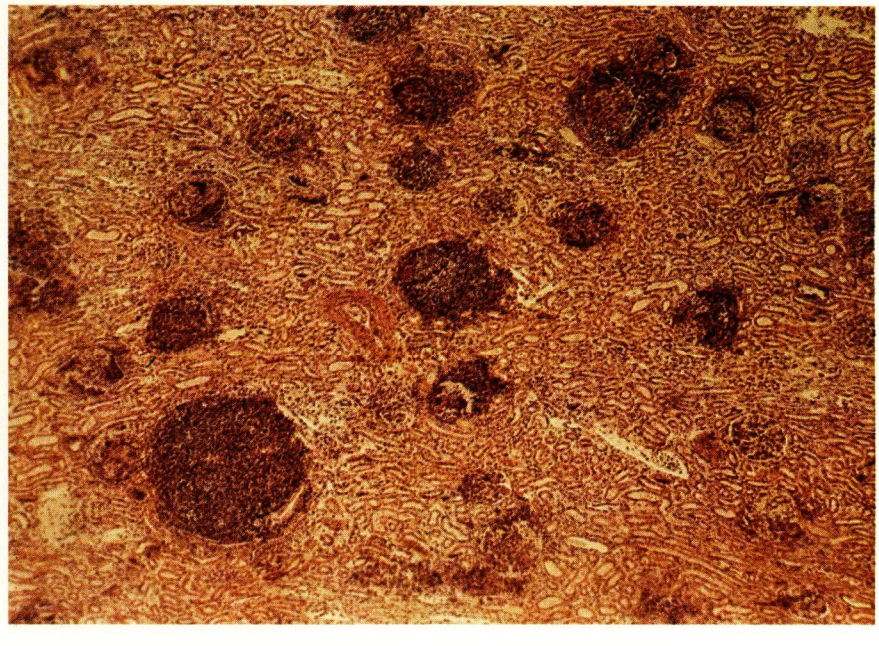

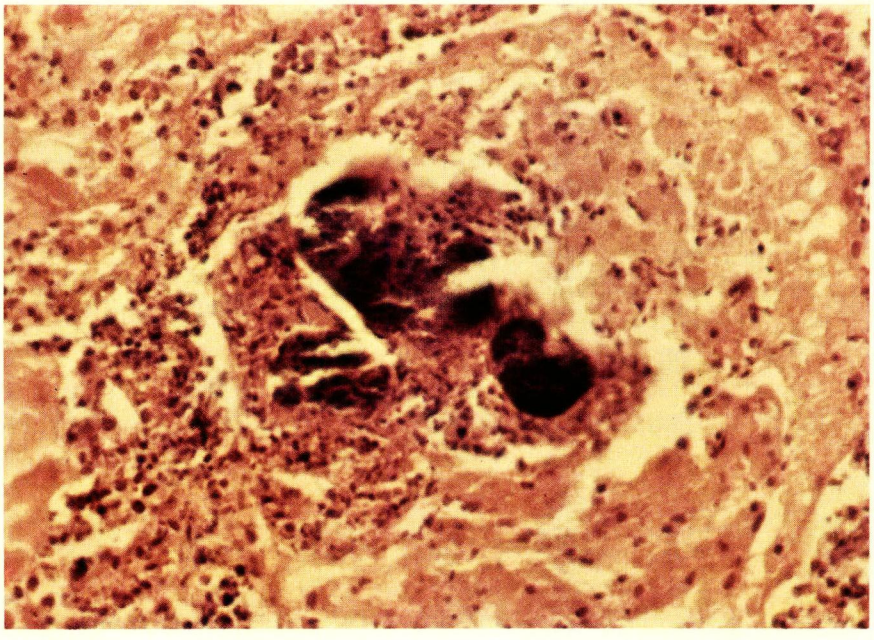

PLATE 201: EMBOLIC ABSCESSATION

This glomerulus has been completely obliterated by leucocytes, purulent debris and several dense clumps of bacteria. Such a lesion may be associated with many different bacteria. They may be caused by a bacteremia or an embolic shower.

PLATE 202: LEPTOSPIRA SPP.

This silver stained section of a dog's kidney shows numerous black clumps and scattered individual spirochete organisms, Leptospira spp..

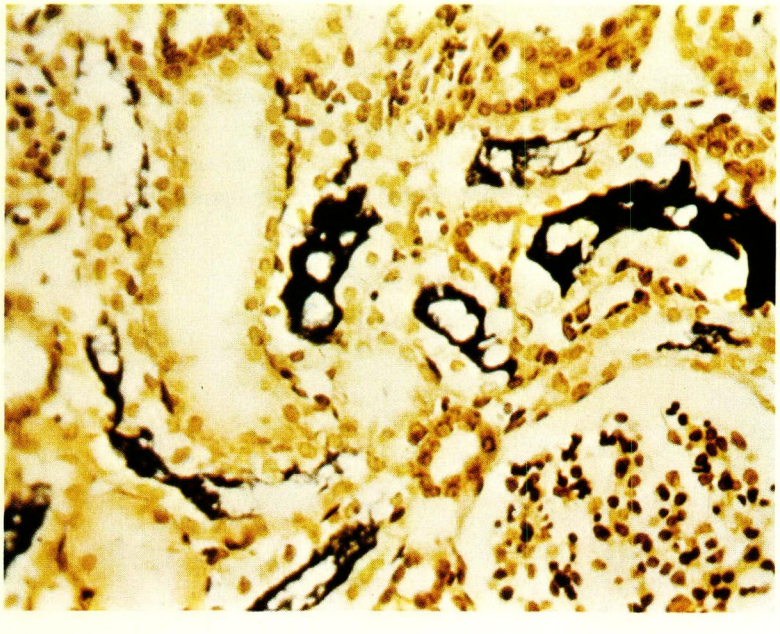

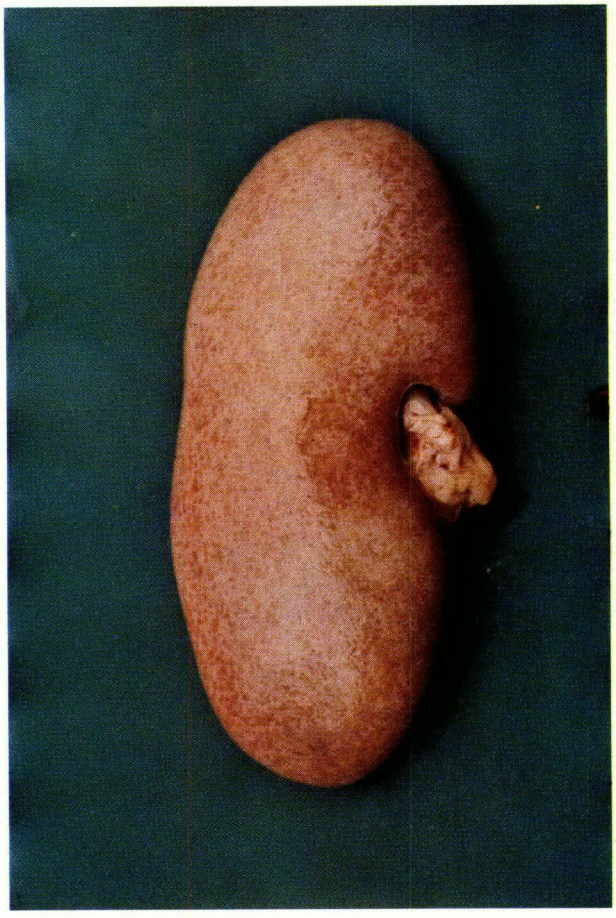

PLATE 203: CHRONIC INTERSTITIAL NEPHRITIS

This diffuse lesion makes the kidney larger, firmer and paler than normal. A definite increase of pale tissue is in the cortex, mostly in a radiating pattern. There is less of a white, interstitial thickening in the more acute cases and more in the longer standing cases even to the degree that the streaks extend into the medullary areas. The actual cause is not known, but in several species Leptospira spp. are strongly suspected.

PLATE 204: CHRONIC INTERSTITIAL NEPHRITIS

This cut section shows the limitation of the pale interstitial reaction to the cortex, at least grossly, with the renal pyramids spared. It is a diffuse lesion and its cause is unknown in most cases. In several species, Leptospira spp. is suspected.

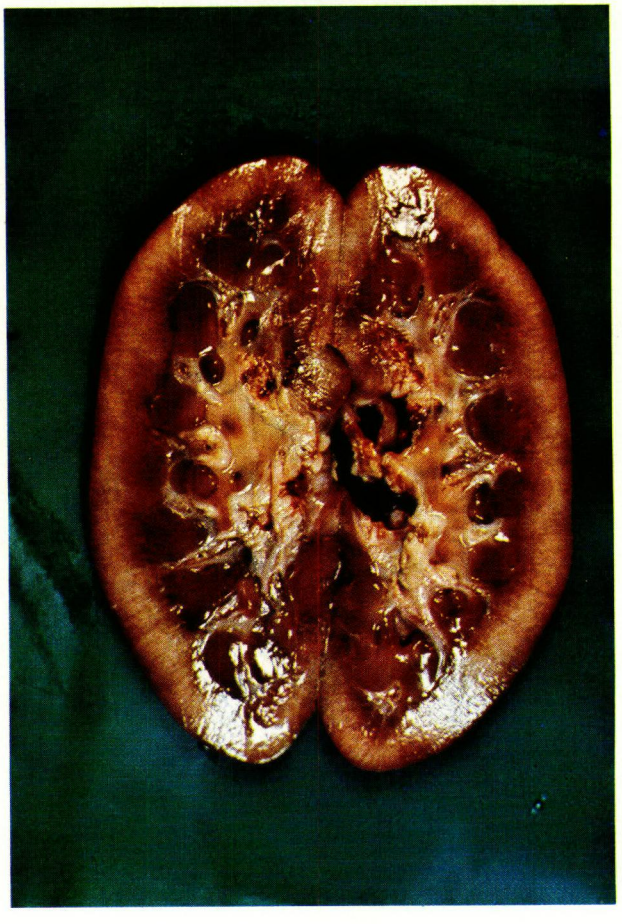



PLATE 205: INTERSTITIAL NEPHRITIS

The inflammatory cell invasion of the interstitium gives it this name. Whether it is focal or diffuse cannot be ascertained by a single histological photograph. In this photo, the tubules have been separated by a mixed round cell invasion but are otherwise normal as is the glomerulus. The lesion may be diffuse or focal depending on the cause, and one must evaluate this aspect grossly.

PLATE 206: NEPHROSCLEROSIS

The increase of stromal connective tissue, the decrease in number of tubules, the shrunken glomeruli and the scattered foci of inflammatory cells all suggest a chronic resolving disease process. It may be focal, diffuse or even locally extensive. The term nephrosclerosis means "hardening of the kidney", but it does not necessarily give the cause or pathogenesis. When one does not know the cause or pathogenesis of such a lesion when it affects the whole kidney, it can be called an "endstage kidney". If this lesion was associated with only one depressed area of a kidney, it could represent an old infarct or healed focus of pyelonephritis. There are many other possible explanations for such a lesion histologically.

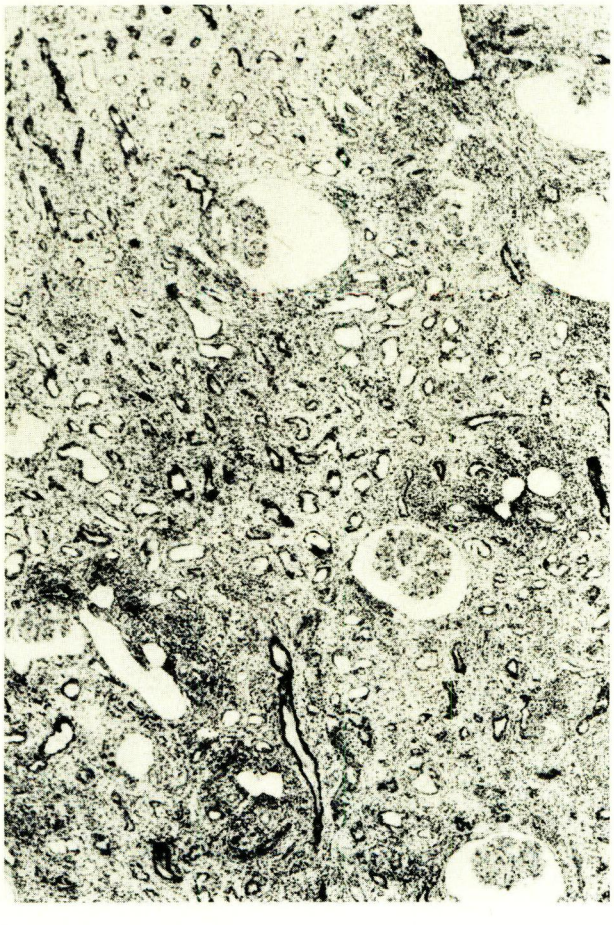

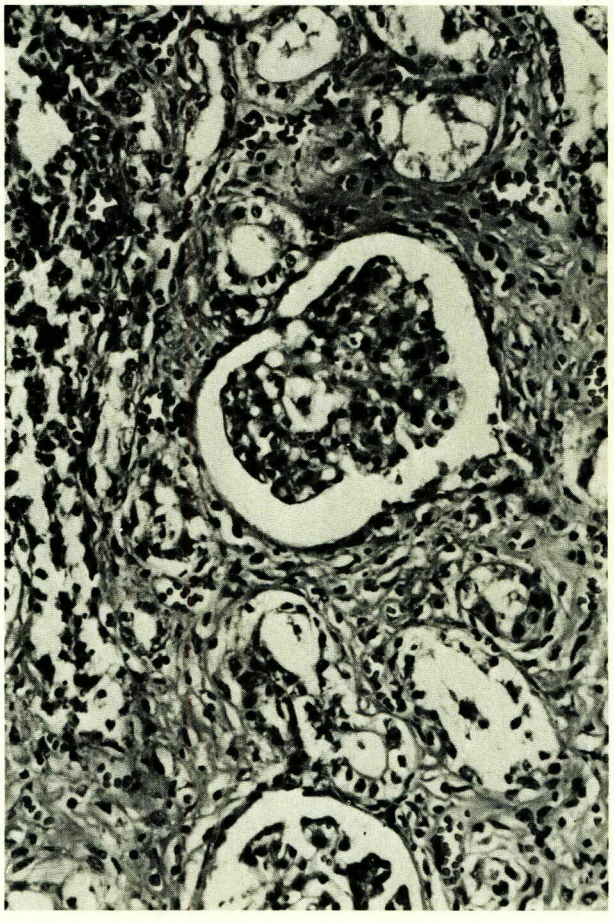

PLATE 207: CHRONIC INTERSTITIAL NEPHRITIS

The chronicity is shown by the apparent increase of interstitial connective tissue physically separating the tubules and glomeruli without marked damage to either glomeurli or tubules. A few chronic inflammatory cells are scattered in the stroma. This could be the result of many diseases or lesions of the kidney, but out of context we are unable to give a definitive diagnosis. It should be stressed again as with most lesions, the gross lesion should be evaluated along with the histological findings to make a proper pathological diagnosis.

PLATE 208: GRANULOMATOUS NEPHRITIS

The actual agent in this case was a mold, Mucor spp. but any one of a number of granulomatous agents could have done this. The lesion is mainly the yellowish areas surrounded by the large pale zones with the remaining portions of both kidneys essentially normal except for the soft wrinkled appearance caused by autolysis. This lesion histologically was in association with blood vessels both in the medulla and cortex as from an embolic shower.





PLATE 209: PARASITE (ASCARID) SCARS

The numerous pale white foci and several depressed foci are the result of larval roundworm migrations through the kidneys. The depressed foci are of longer duration with connective tissue maturation and shrinkage causing the depressions. This type of lesion may be found in most other tissues, but they are more commonly seen in the liver and kidneys of most species. Other parasites may make somewhat similar lesions in their tissue migration paths. It is often difficult to find a parasite on histological examination of these lesions unless many lesions are examined. In line with younger animals having more parasites, these lesions are more common in young animals. The depressed lesion should be differentiated from the normal capsular blood vessels entering the cortex which are often considered, erroneously, to be adhesions. A truly adherent capsule (adherent capsulitis) is a rare lesion in all species. The pulling away of the renal cortex when the capsule is removed during the necropsy is usually a fault in the prosector's technique.

PLATE 210: KIDNEY WORMS

Several worms, Stephanurus dentatus, are present on the opened pelvis of this pig's kidney. The periureteral tissue is thickened with a chronic granulomatous response to the larval migration of these parasites.



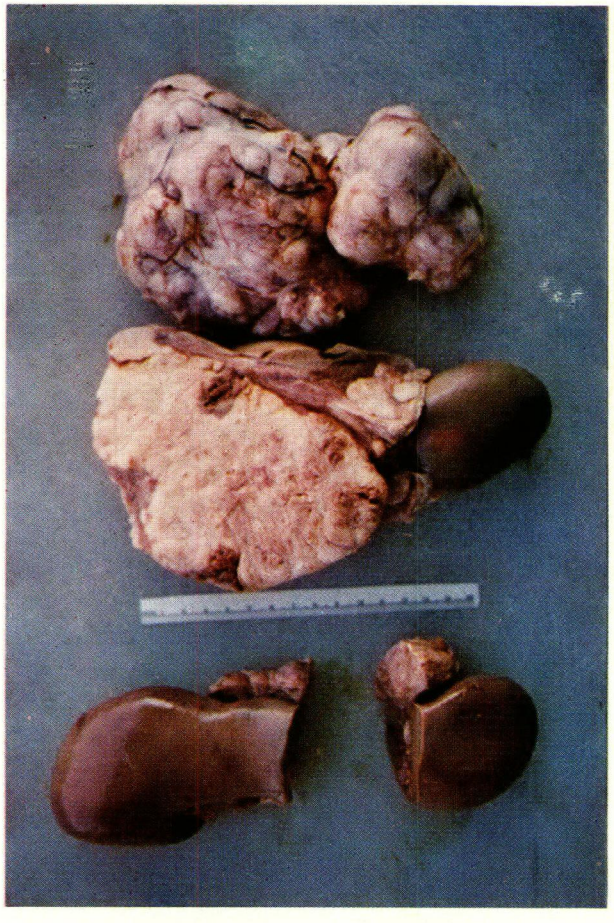

PLATE 211: EMBRYONAL NEPHROMA

This neoplasm in a two year old pig shows the large, firm, pale multilobulated mass in the anterior pole of one kidney and a smaller mass at the hilus of the other kidnev. The tumor had metastasized widely to the lung. This is the most common tumor of the pig and is more common in pigs than other domestic animal species. Wilms's tumor and nephroblastoma are commonly used names in human medicine for this neoplasm.

PLATE 212: EMBRYONAL NEPHROMA

This highly malignant tumor of the kidney, usually of the young, shows numerous abortive epithelial lined tubules and various amounts of mesenchyme. This had massively showered the lung in this two year old pig.

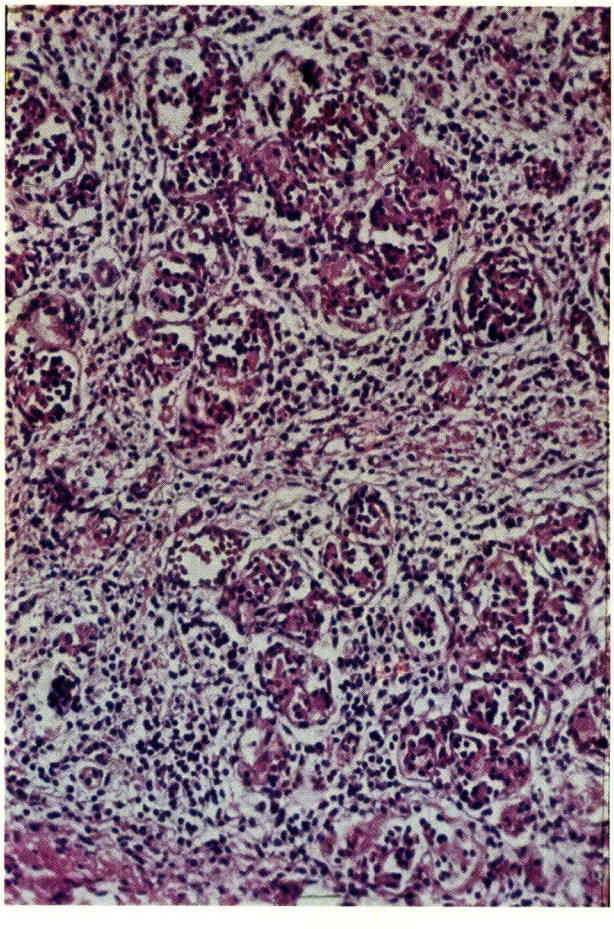

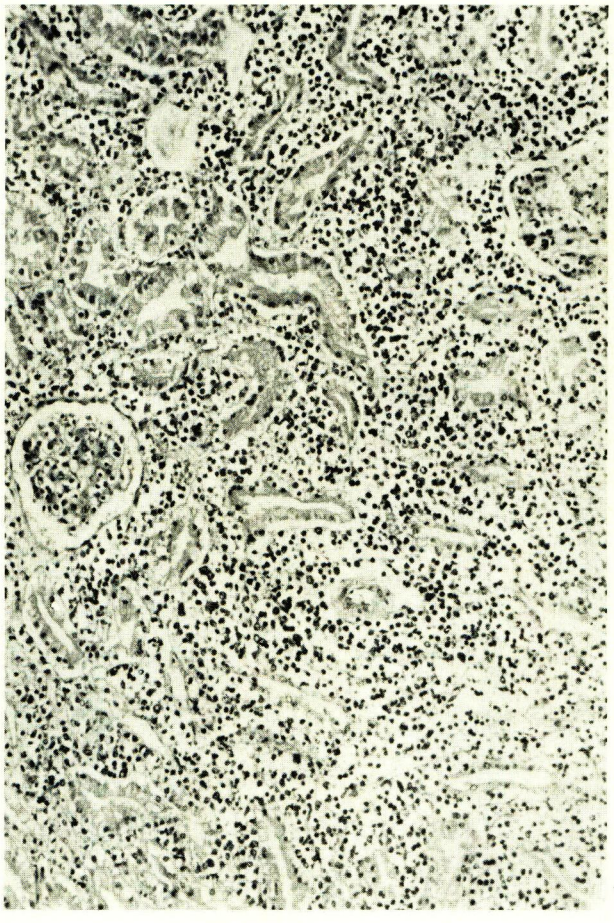

PLATE 213: LYMPHOMATOSIS

The large numbers of round cells seen here and diffusely scattered throughout the kidney are neoplastic lymphocytes. Grossly, the kidney was swollen and pale. In some cases, the cortex can be streaked with pale stria or studded with various sized, solid nodules of neoplastic lymphoid cells. Out of context, a single histological field may not be differentiated from a chronic focal inflammatory process, especially if the neoplastic cells are of the mature lymphocytic type and not the more immature lymphoblastic forms. This disease has a tendency in many species to mimic other diseases.

PLATE 214: TUMOR EMBOLISM

The glomerulus has been completely invaded by this metastatic nodule of a squamous cell carcinoma from its primary site in the skin. Only one or two original glomerular tufts can be recognized with the majority of slightly darker cells being the metastatic epithelial cells. Several of the tumor cells have small irregular nuclei suggesting mitotic figures. There are no epithelial pearls in this focus which is a diagnostic feature of this tumor, but this may be explained by the fact that it is a younger aged mass than the primary site. This does not always hold true for in some tumors the daughter foci may show more mature features than the primary mass.

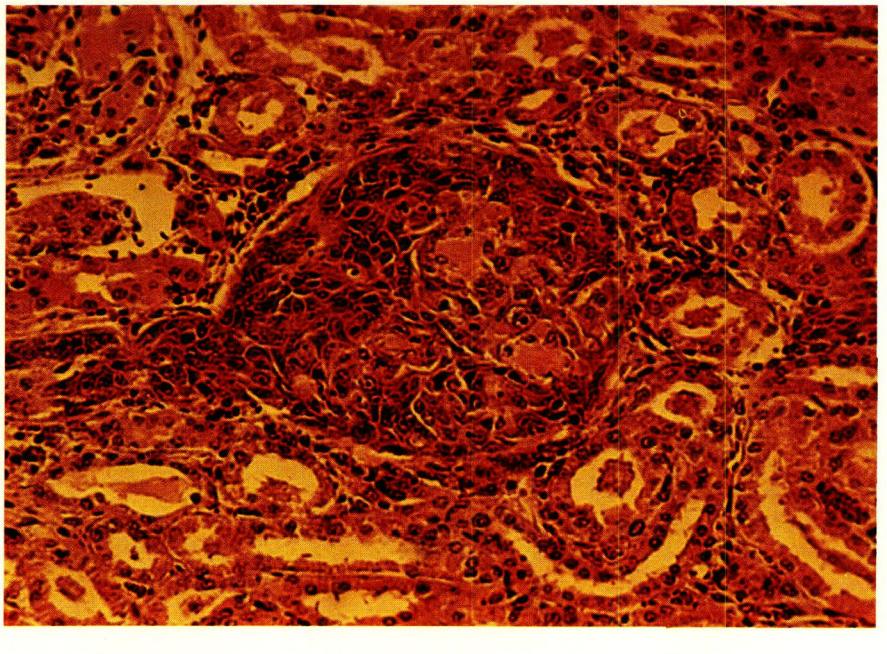



PLATE 215: PETECHIAE

Multiple pin point red spots are present in the bladder mucosa of this weanling pig that died of a severe septicemia with fibrinous polyserositis. Petechiae in general are very common in many septicemias, both bacterial and viral, as well as in traumatic and toxic deaths, thus their significance has to be evaluated carefully.

PLATE 216: HEMORRHAGIC CYSTITIS

The severe reddening of the bladder wall, in addition to the bloody exudate in the lumen, makes this a hemorrhagic lesion and not just congestion. C. pyogenes was isolated but its causal role is not understood. An acute obstruction could have predisposed the bladder to an infection, but this was not found at necropsy.

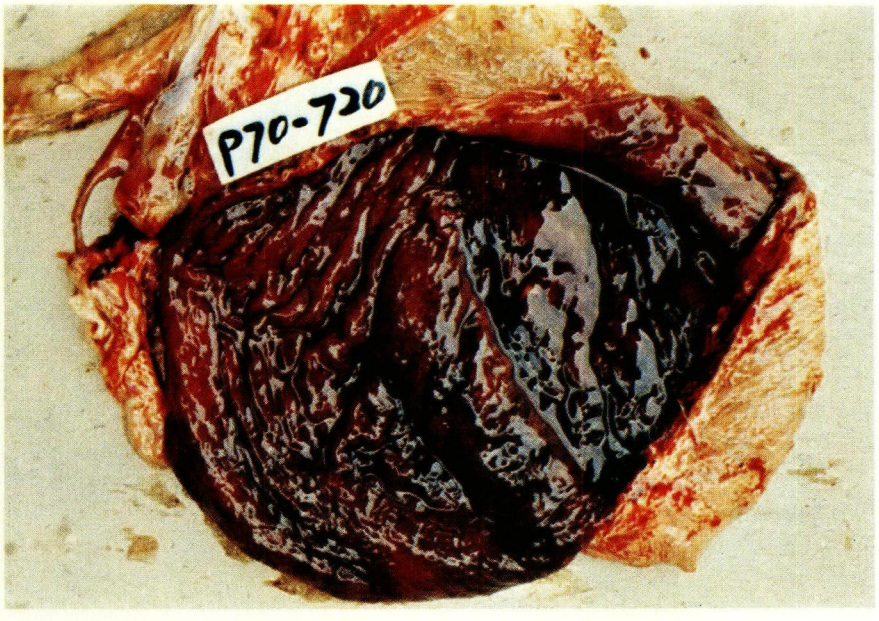

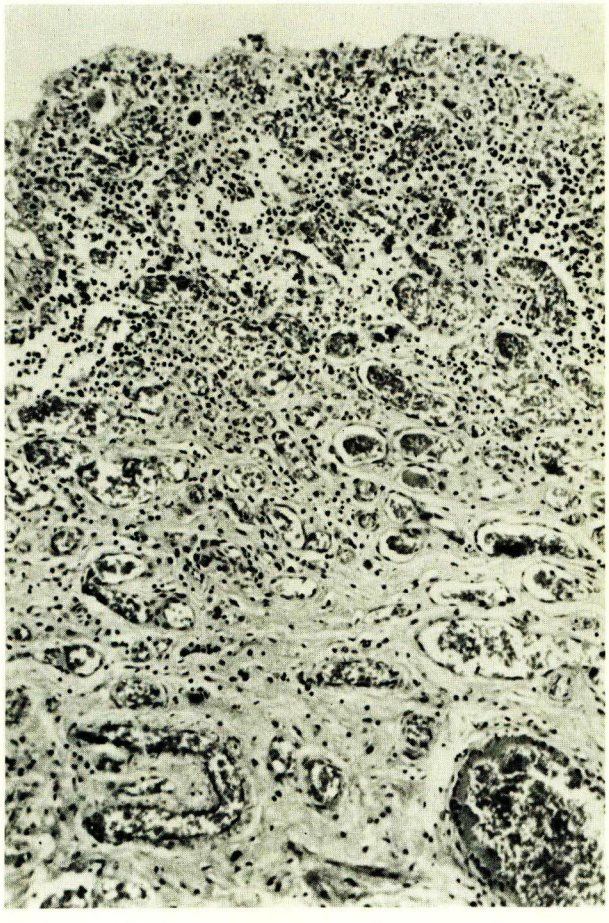

PLATE 217: HEMORRHAGIC CYSTITIS

The bladder submucosa is swollen with dilated capillaries and extravasated blood (hemorrhage) is spread under the area of desquamated mucosa. Inflammatory cells are in the superficial submucosa. A less extensive and less severe lesion may be seen in some bladders almost as a terminal lesion in cases where some urinary straining may have been present terminally.

PLATE 218: NECROTIC CYSTITIS

The greenish, irregular covering of the bladder mucosa represents a subacute necrotizing cystitis with the remaining areas of mucosa markedly congested. Such a lesion is often seen with an obstructive lesion of the urethra. A slight dilatation of the ureter (hydroureter) and the kidney (hydronephrosis) is also seen here.



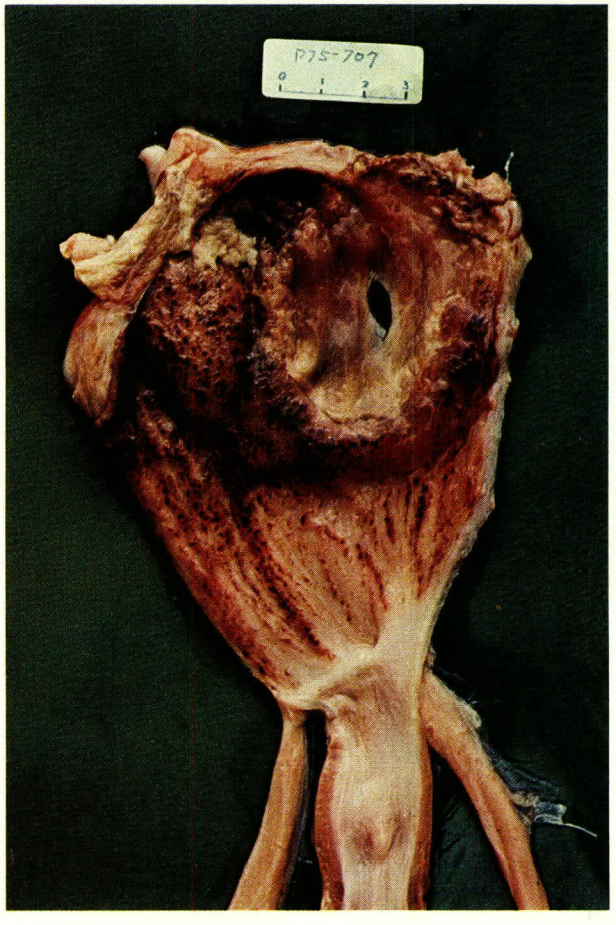

PLATE 219: RUPTURED BLADDER

Most of the mucosa is congested with several areas of apparent hemorrhage adjacent to the rounded crater with a perforation at its base. The linear petechiaè nearer the trigone can be seen commonly in pigs that have some tendency to strain at urination. In this case of obstruction, the perforation is in a commonly found position, that of the fundus. A common cause of functional bladder obstruction in any animal is a spinal cord compression or even a prolapsed intervertebral disc. It should be noted that even without a gross lesion in mucosal continuity of the urinary tract, urine may "leak" into the surrounding tissues and abdominal cavity enough to suggest a ruptured bladder clinically.

PLATE 220: RUPTURED BLADDER

The markedly congested fundic portion is roughly delineated from the greenish grey, necrotic area in the trigone with a perforation completely through the wall. This is from a piglet that was apparently stepped on when it had a full bladder. This perforation is to be differentiated from those that spontaneously rupture, usually in the fundic region. The urethral mucosa under the highlight is apparently congested, but this is normal as it is erectile tissue and has an extraordinary number of vessels in it.

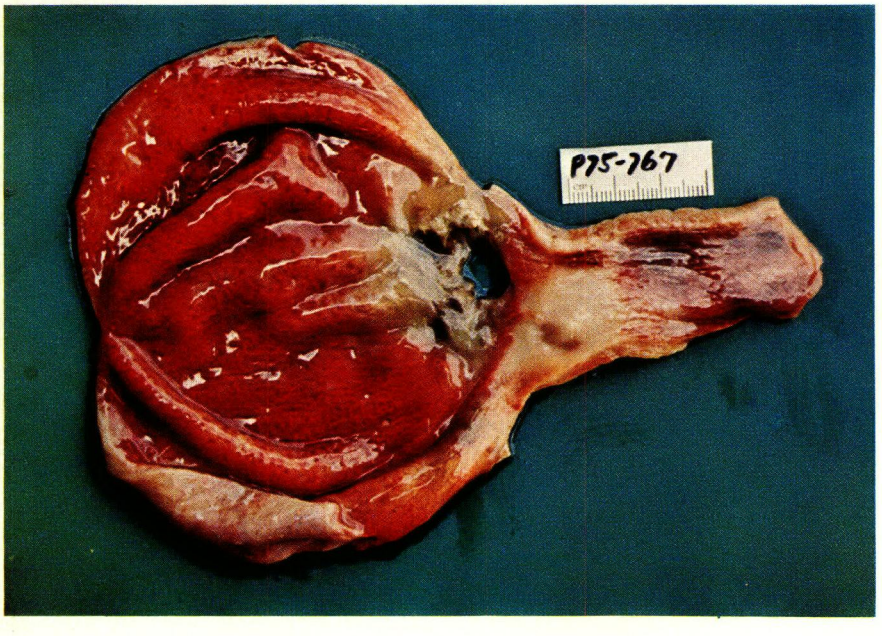

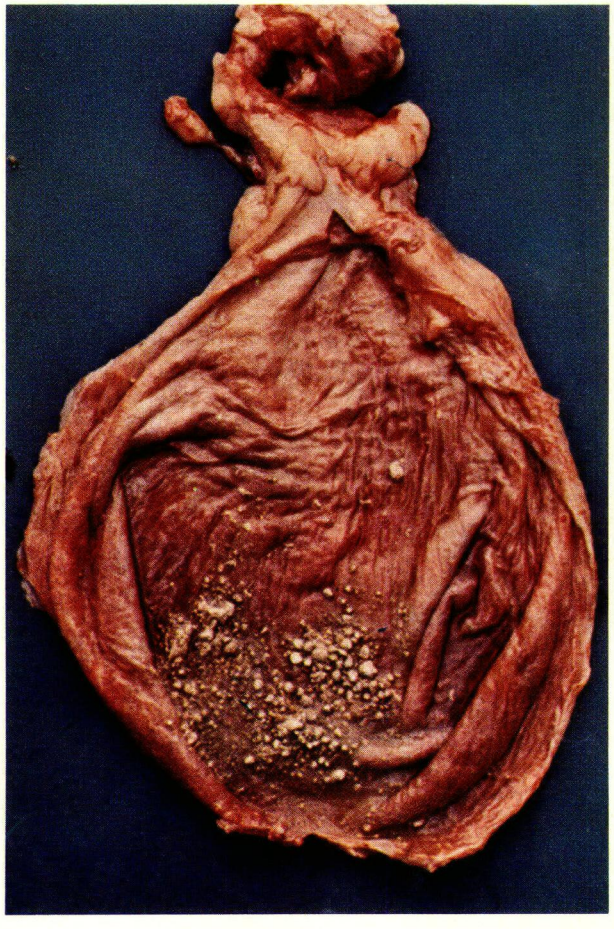

PLATE 221: CYSTIC CALCULI

Bladder stones are not common in pigs but are quite common in most other species. Numerous different types of calculi can be identified as to composition, but it is more difficult to identify most of them grossly. Most are associated with dietary imbalances of minerals and vitamins, but many cases have no consistent etiological factors involved. Males castrated early in life have more problems with these than intact males. This is because the urethral lumen size does not enlarge as much as in the noncastrated males. A larger urethra probably explains why females are less affected than males. The tiny processus urethra at the end of the penis in male sheep and goats should always be examined in these animals when obstruction is found. In the bull, the calculus often lodges at the beginning of the sigmoid flexure of the penis, and in the dog, they often lodge just as the urethra enters the os penis. These were an incidental finding in this pig.

PLATE 222: URINARY BLADDER EMPHYSEMA

The entire surface is elevated with blebs of gas which in some areas appears as gas pockets. Histologically, the gas pockets were in the mucosa proper and no appreciable inflammatory response was present. With time, giant cells can be seen phagocytizing the gas bubbles. This was a diabetic dog and the gas is considered to be CO_2 from tissue metabolism of the urinary excreted sugar. It can also be seen in cattle that have been given large quantities of sugar intravenously with subsequent urinary excretion of excess sugar within a matter of hours. A similar lesion may be found in the abomasum of calves given large quantities of sugar solutions per os.

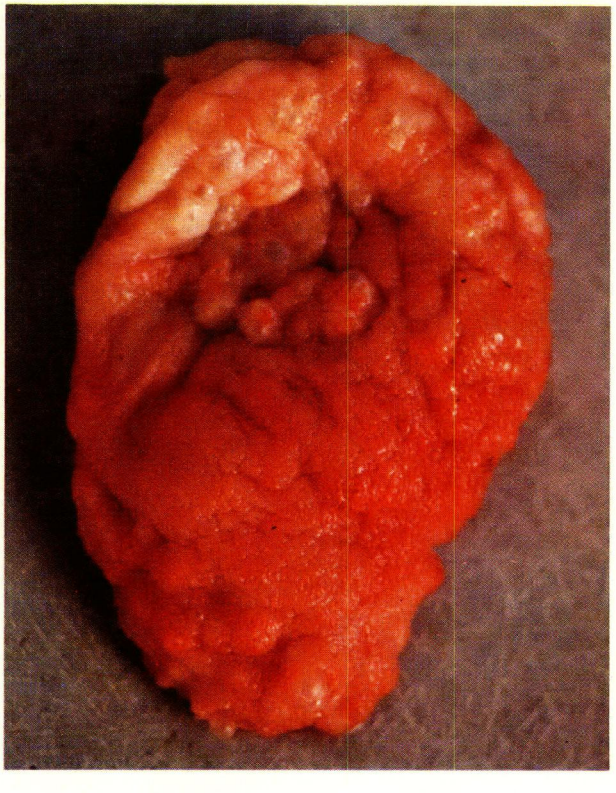



PLATE 223: ENZOOTIC HEMATURIA

These multiple polypoid masses attached to the urinary bladder of this cow are a mixture of epithelial hyperplasia, epithelial neoplasia and angiomatous neoplasia. Papillomas and hemangiosarcomas are found in some cases. The actual cause is not known but a chemical agent that may come from bracken fern is suspected by many. The problem is more commonly seen in cattle that are on unimproved pastures. As the name implies, the disease is only seen in certain areas, but bracken fern, Pteridium aquilinum, is a quite common plant, so its actual role is not known. Affected cattle usually have hematuria and die from anemia.

PLATE 224: URACHAL ABSCESS

The 2 cm. slightly darkened mass just under the dark liver edge and attached to the abdominal wall is an abscess pocket of the urachus. It could be called an internal umbilical abscess. Its elongated portion curves caudally to attach to the urinary bladder. This was one of many abscesses scattered in the body of a debilitated piglet. The extremely dark liver suggests cachexia as it is dark because of its lack of fat. It is thought that the pig's problem may have developed from the umbilical infection. Many bacterial agents could have been causative. The 2 mm. strand of tissue attached to the cranial portion of the abscess is the falciform ligament of the liver.

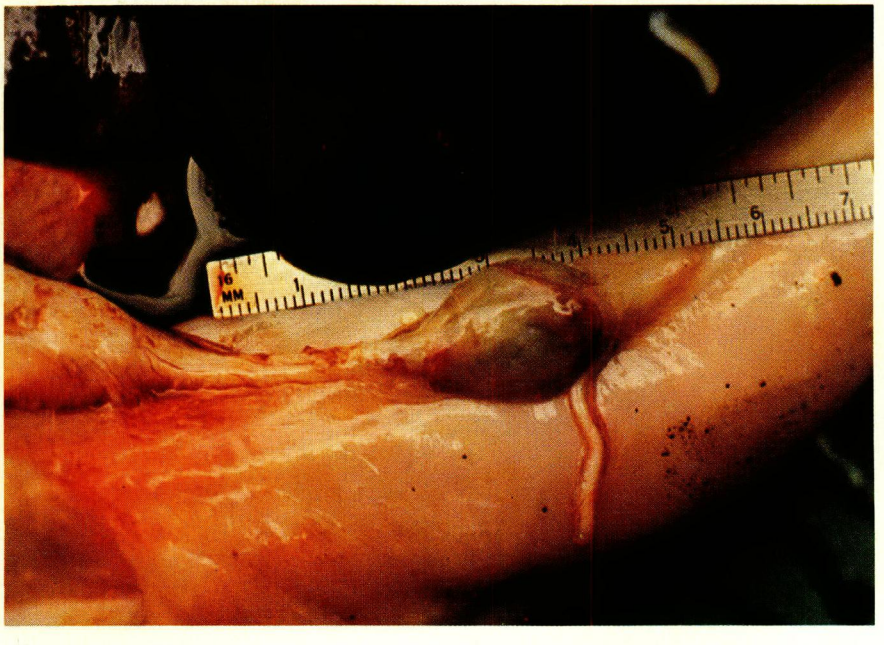



PLATE 225: PROLAPSED VAGINA AND UTERUS

The large mass protruding under the tail is the edematous and congested everted uterus and vagina. The portion nearest the tail is the vagina and the uterus is the portion with the fissure. The fissure is the separation of the uterine horns. This sow had just farrowed and this apparently caused the prolapse. Any cause of continued straining such as an intrapelvic abscess, tear or inflammation of the uterus during parturition can be a predisposing factor to this lesion.

PLATE 226: SEGMENTAL DILATATION OF THE OVIDUCT

A large proximal segment of the oviduct associated with the dark hemorrhagic ovary is dilated many times normal size and filled with a clear, thick, slightly viscid fluid (mucosalpinx). If filled with a watery type fluid instead, it would be called hydrosalpinx. The cause of either is not understood. The ovary has several cysts in it and one had just ruptured to cause the hemorrhage.

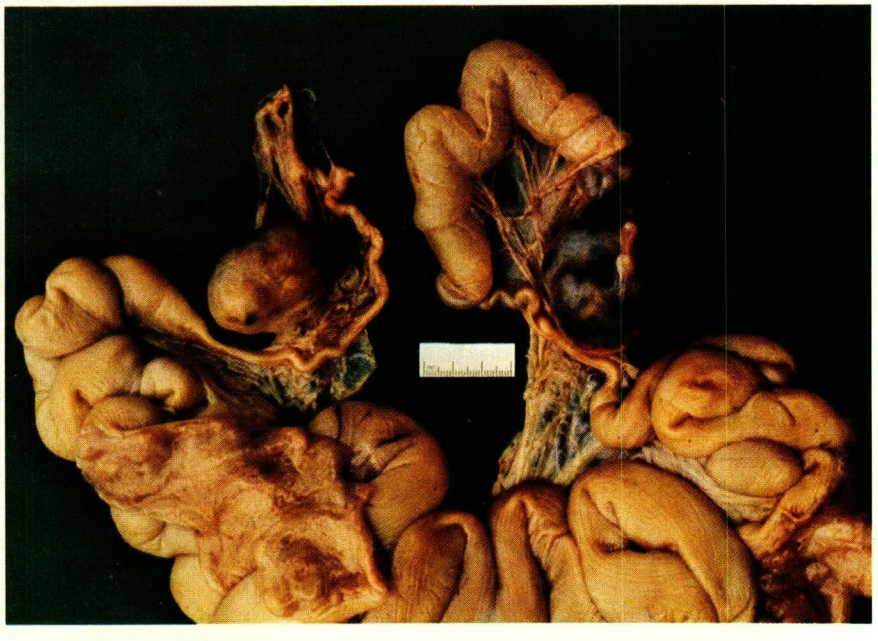



PLATE 227: CYSTIC OVARIES

Both of this sow's ovaries are markedly cystic and both have a collapsed cyst showing on the surface. The sow had a reproductive problem in failing to conceive. The actual cause for most of these in many animals is not known.

PLATE 228: MESOSALPINX CYST AND HYDROSALPINX

This 2 cm. soft, fluid filled cyst is located in the mesenteric attachment of the oviduct, the mesosalpinx, and not attached to the ovary. There are at least 9 different types of cystic structures associated with the ovary and related tissues most of which have been described for the cow. This is a common one in the sow and it was an incidental finding at necropsy. This lesion would only be significant if it obstructed the oviduct.

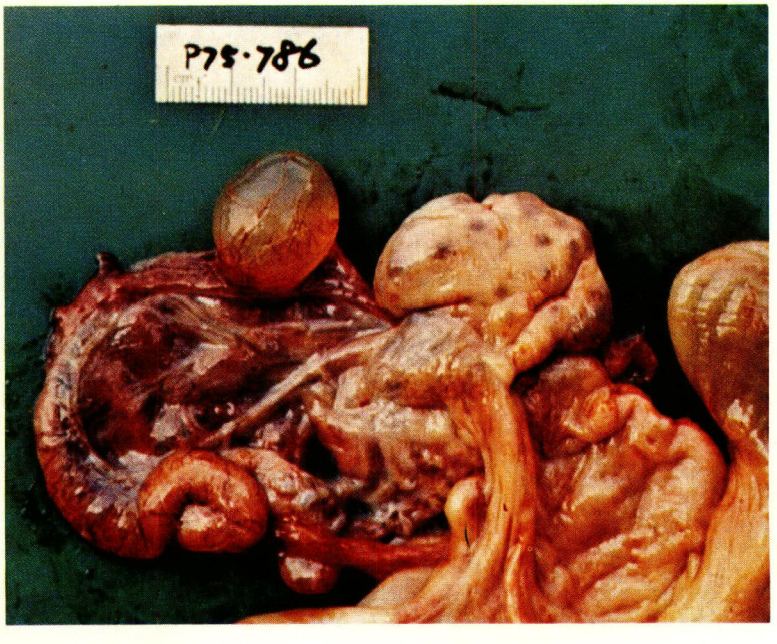



PLATE 229: OVARIAN HEMORRHAGE

This large cystic ovary ruptured and fatal exsanguination occurred in this adult sow. The cause of the cystic formation is unknown, but when it ruptured, a vessel was also damaged and the animal bled to death into the abdominal cavity. Fatal exsanguination occasionally occurs in cattle in which the corpus luteum is expressed. Relatively small vessels that rupture in both the ovary and brain have a tendency to continue bleeding while similar sized vessels in other tissues almost always stop bleeding spontaneously.

PLATE 230: ABSCESSATION

The thick, creamy like material in the region of this ovary is pus, and the ovary itself is completely surrounded by adhesions. It is thought that most lesions in the periovarian area have ascended from the uterus proper.

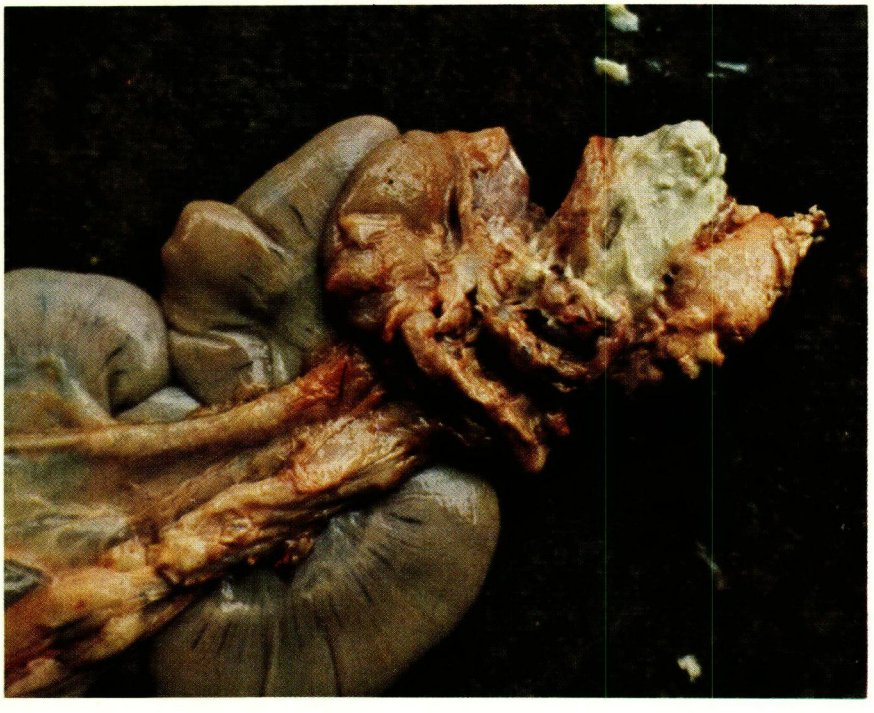



PLATE 231: PURULENT HYDROMETRA (PYOMETRA)

In this twisted mass, the uterine horns and body are slightly dilated, atonic and filled with a cloudy, thick milky exudate. This is a post artificial insemination case from which Staphylococcus spp. was isolated. There is a question about what this is to be called. Some believe that it is mainly just purulent fluid in the lumen, but without infection of the uterus proper. Others suggest that even a few inflammatory cells in the endometrium justifies the suffix "itis".

PLATE 232: PURULENT HYDROMETRA AND PERIMETRITIS

The dilated uterus with some bloody fluid and markedly congested endometrium is seen here cut open to show the markedly edematous soft tissues just on the outside of the opened uterus. About 12 liters of thick milky fluid escaped when the uterus was opened. Some fibrin debris is still attached to the mucosa. An iatrogenic perforation of the uterine body at the time of artificial insemination was the initial cause. Many organisms may be responsible for similar cases, but Staphylococcus spp. was isolated from this case.

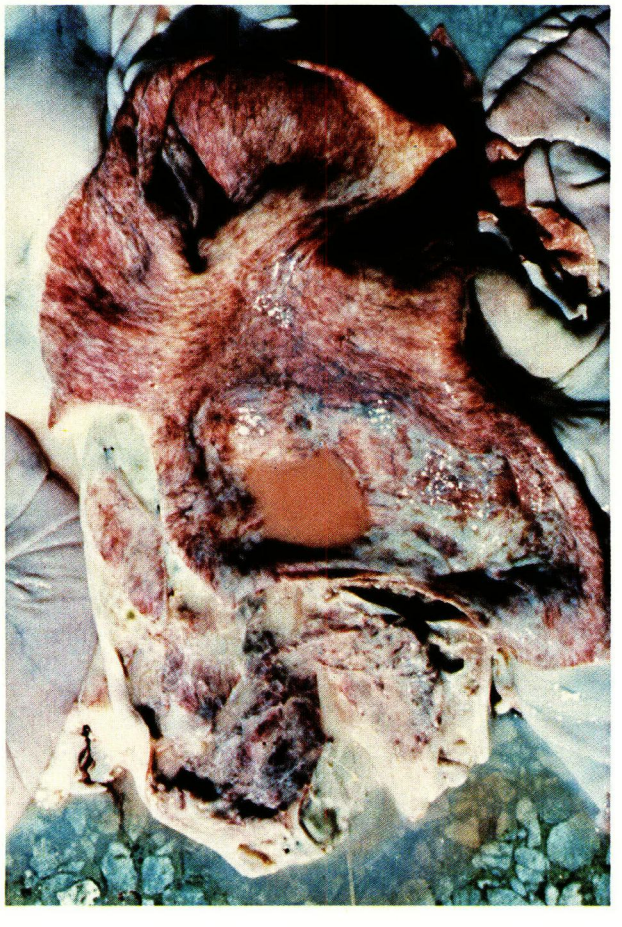



PLATE 233: PURULENT ENDOMETRITIS

The yellowish material attached to the roughened uterine mucosa of this sow is purulent debris. Many tiny firm nodules can be palpated in the mucosa from which a creamy pus can be expressed. These are cystic uterine glands with purulent debris in them. This process frequently follows abnormal parturitions as abortions and dystocia. Many different organisms may be cultured from such a lesion.

PLATE 234: CHRONIC ENDOMETRITIS

The lining epithelium is hyperplastic on the surface and adjacent to the area of epithelial loss (ulceration) where a clump of neutrophils and other inflammatory cells are present. Numerous chronic inflammatory cells are scattered in the submucosal areas and some edema is separating the deeper tissue components.

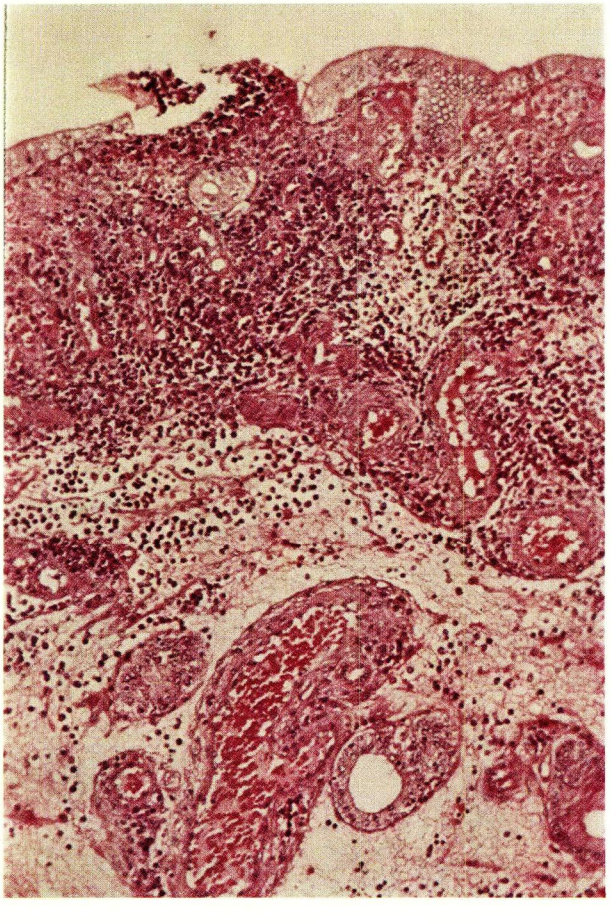

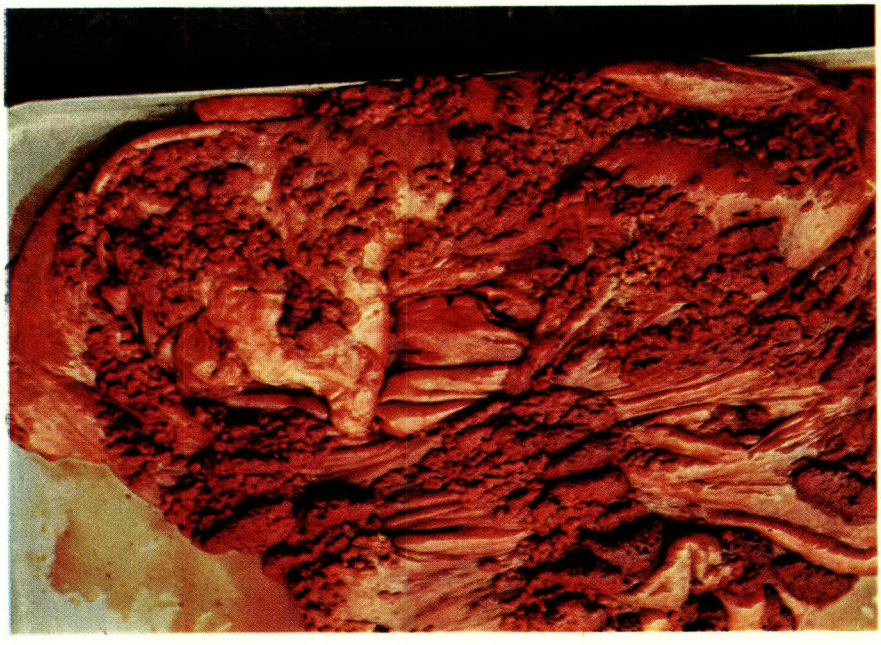

PLATE 235: ADVENTITIOUS PLACENTATION

Normally the cow has many caruncles in the uterus for placental attachment which are relatively uniform in size and overall shape. In this case however, there are hundreds of various sized and shaped attachment sites (adventitious placentation). It is thought that at the time of a previous parturition the caruncles were traumatized in some way that pieces of caruncles were broken off and became implanted on the normally clear intercaruncular spaces to form these adventitial caruncles. These are functional and would be covered by normal placental cotyledons in the subsequent pregnancies.

PLATE 236: SQUAMOUS METAPLASIA

The uterine glands normally have a low, cuboidal cell lining, but these have a thick, stratified squamous cell lining. Some keratin and cellular debris is in a few crypts. The epithelium of several of the large cystic crypts is normal, but the crypts should not be cystic. The cyst formation is probably related to the blockage caused by the squamous metaplasia of their ducts near the surface. A hormonal imbalance may cause this metaplasia, but in most instances, especially where ducts of glandular organs are also involved, one should consider a Vit. A deficiency. Some toxic agents may interfere with Vit. A metabolism such as chlorinated naphthalene.

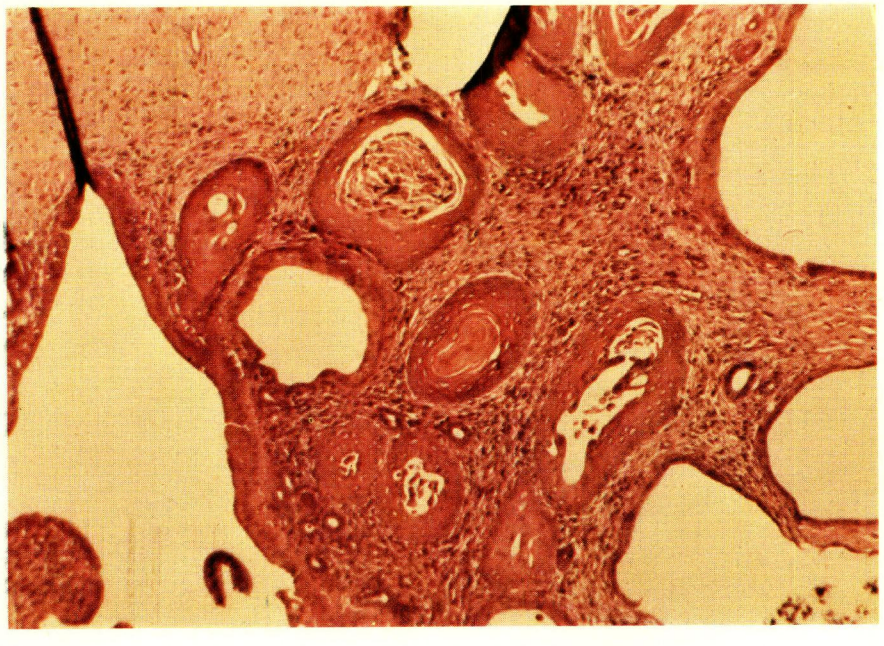



PLATE 237: FOCAL FIBROTIC NODULES

On the peritoneal surface of this sow's uterine horn and mesentery are several connective tissue nodules. They are common in sows but not in gilts, so it is assumed that they are related to pregnancy. Histologically, they are amorphous masses of connective tissue covered by peritoneum, and they do not have appreciable numbers of inflammatory cells associated with them. Many "fibrotic tags" are to be found commonly on the costal pleura of cattle often filled with fat. These are normal. On the diaphragmatic surface of the liver and on the spleen of horses, slender connective tissue tags are most common and thought to be related to parasites. They are seen in newborn foals however without parasites which suggests they may not be parasitic in origin.

PLATE 238: VAGINAL NECROSIS

Tags and small sheets of necrotic debris and hemorrhage mark the area of vagina in which a decomposed fetus was lodged. The pale white mucosa, on which the identification number was placed, is essentially normal mucosa of the dilated cervix. As the other feti were expelled normally, it is thought that this last fetus had died in utero and became emphysematous.

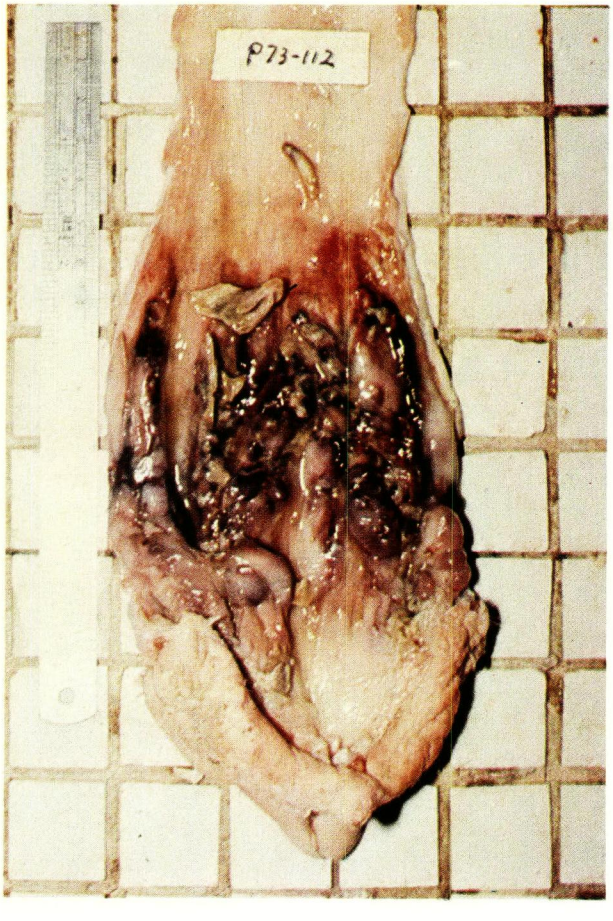

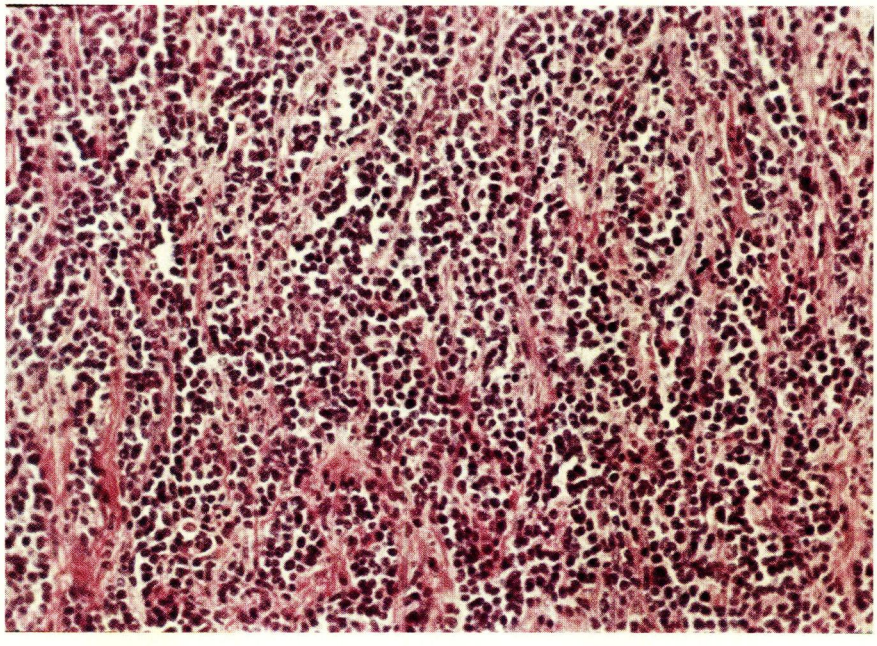

PLATE 239: LYMPHOMATOSIS

The uterine wall is infiltrated with a massive number of neoplastic lymphocytes scattered throughout a moderate amount of connective tissue stroma. It should be noted that the amount of collagen seen in some of these tumors is a function of the specific host tissue in which the tumor cells are found rather than the stimulatory effect by the tumor cells themselves. This apparently does not hold true for all tumor cells. Many types of neoplastic cells will not grow in some metastatic foci possibly because the "soil is not fertile", but the lymphoid cells can and do proliferate in almost all tissues.

PLATE 240: GRANULOSA CELL TUMOR

This 12 cm. cystic mass had completely replaced one ovary of a mare that was in constant heat (nymphomania) clinically. There are several different types of neoplasms that commonly occur in the ovary of various species, but the one most likely to be highly vascular and cystic is the granulosa cell tumor. It often produces estrogen which accounts for its clinical activity.





PLATE 241: LEIOMYOMA

This was a firm, irregular, 16 cm. mass attached to the broad ligament of one ovary in an otherwise normal sow. The surface was covered by peritoneum and it was clearly lobulated as seen here. Histologically, it was a typical spindle shaped cellular mass often in whorls. The smooth muscle cell tumor is common in the stomach wall also.

PLATE 242: LEIOMYOMA

The large spindle shaped cells with their nucleus in the center are characteristic of smooth muscle cell tumors. The central nuclei differentiates it from a fibroma and several other spindle shaped cell tumors. One should look diligently for cross striations in the elongate cell to rule out striated muscle cell tumors. This was from the uterus which along with the stomach are common sites for this tumor in most species.

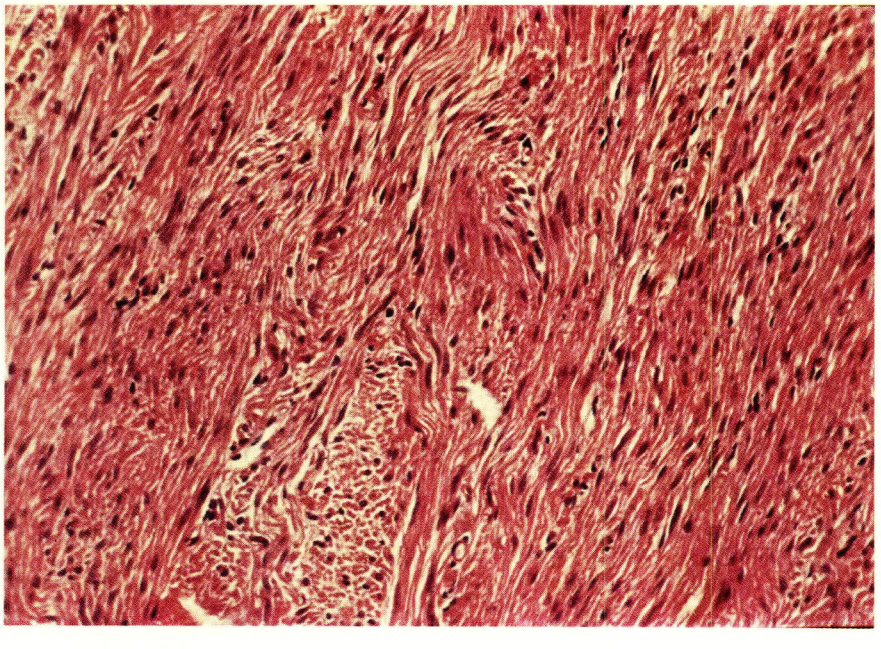



PLATE 243: SEPTIC MASTITIS

Botn halves of this cow's mammary glands have been cut open longitudinally and one halt of each discarded to show only the cut surface of all four quarters. When first removed and cut open, no appreciable difference was seen between any of the quarters, but one quarter had a slight odor of fermentation. On standing exposed to the air, the above dark quarter became discolored to demonstrate that it was the affected quarter. Several organisms may be isolated from such quarters, E. coli was in this case. This type lesion demonstrates the need for the sense of smell in pathology as well as the idea of waiting for a visible change to develop.

PLATE 244: CHRONIC SUPPURATIVE MASTITIS

Six reddened, elevated, draining fistulae are seen scattered on the surface of this one section of a sow's udder. Numerous other healed over drainage sites have contracted star shaped scars about them. Several organisms may be cultured from such lesions, but Staphylococcus aureus is a common one.



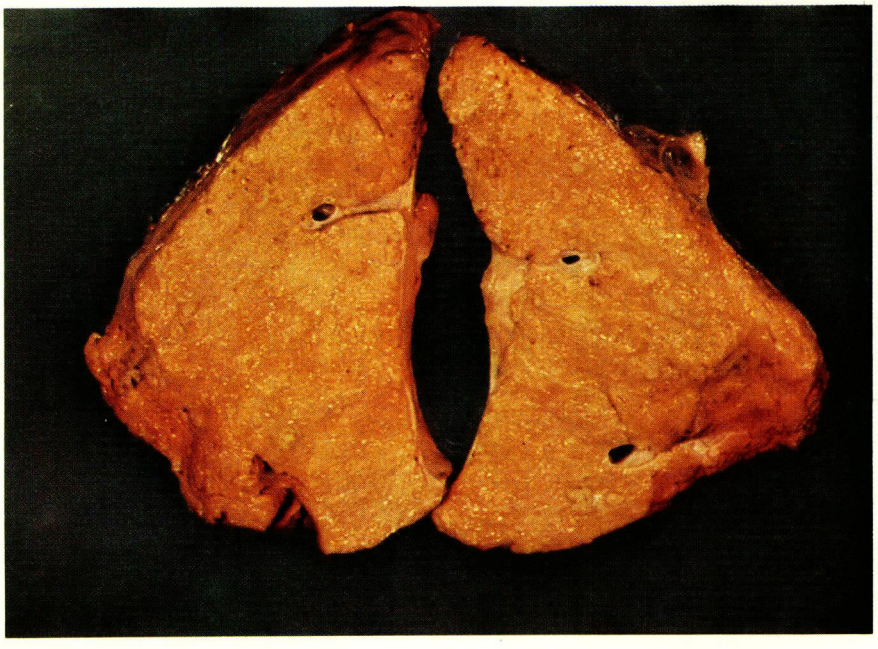

PLATE 245: GALACTOPHORITIS

The main mass of these sections of mammary gland are essentially normal, but scattered throughout are small islands of denser tissue with yellowish, dry purulent debris in their centers. These foci are slightly firmer than the remaining parenchyma. They represent the many ducts which are involved with a chronic inflammation and are filled with inspissated pus. It is not a case of chronic mastitis in the usual sense of the alveoli (parenchyma) being involved.

PLATE 246: CHRONIC GALACTOPHORITIS

In the center of this picture, there is a slightly thickened milk duct with a few inflammatory cells in its wall and a large amount of purulent debris in the lumen (chronic galactophoritis). The surrounding mammary gland tissue is inactive but otherwise is not involved in the inflammatory process. Several pieces of mineralized secretion (milk sand) are in a few alveoli.

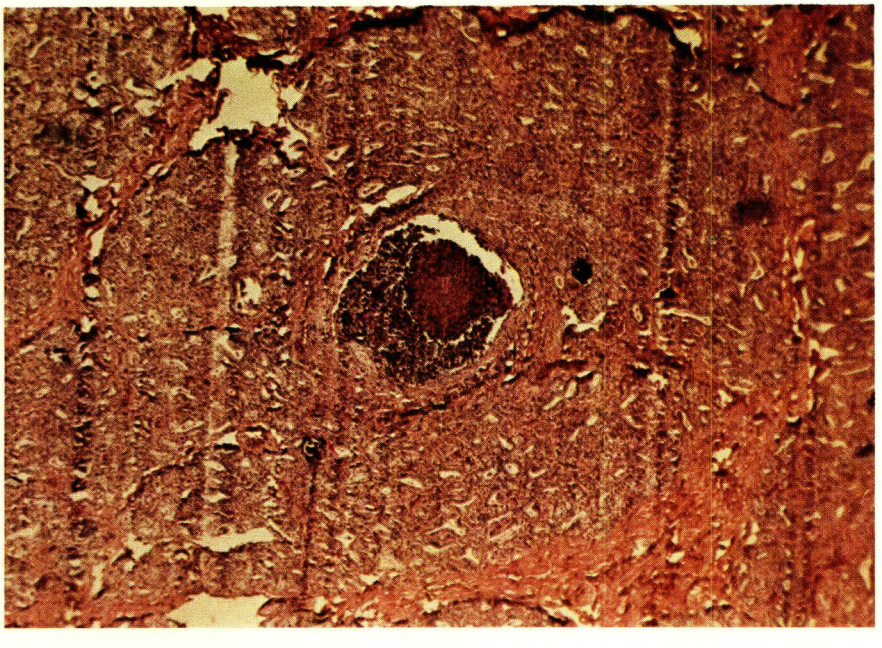

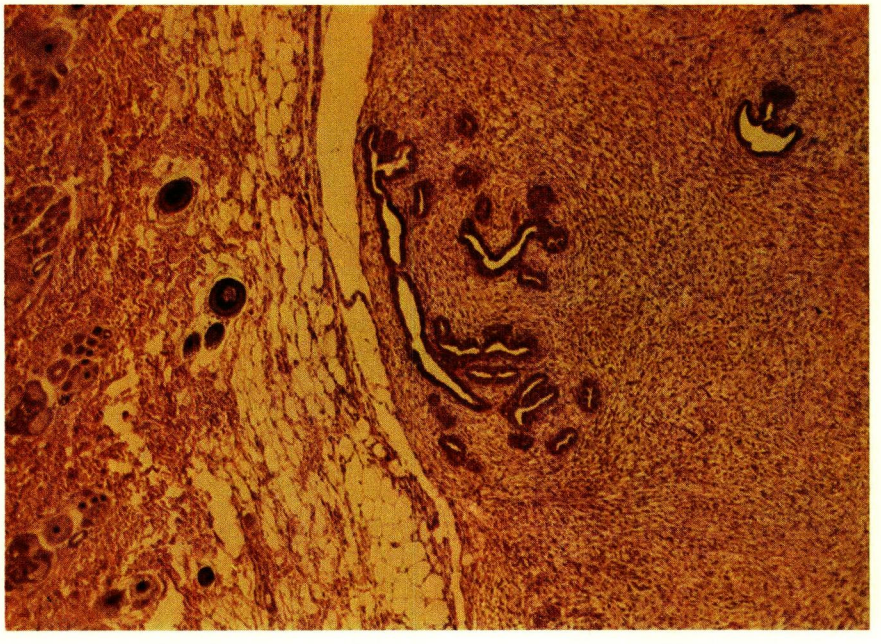

PLATE 247: BENIGN JUVENILE HYPERPLASIA

The one area of rather uniform loose connective tissue with several duct like structures near one edge is a portion of enlarged mammary tissue from an 8 mo. old female cat. This is a hormonally caused hyperplasia of the mammary gland commonly seen in cats and often is erroneously diagnosed as a tumor. They will regress spontaneously in several months.

PLATE 248: ADENOCARCINOMA

The numerous follicle like structures are neoplastic gland formations from the mammary gland of a cat. They are lined by cells that are more basophilic, more pleomorphic (varying in shape) and have numerous mitotic figures all of which help to distinguish these cells from normal. Several small islands of similar cells are scattered in the stroma and have not formed acini as yet. There are also several clumps of cells that are in small vessels, either lymphatics of dilated capillaries, and this vascular invasion is the one feature that is most consistent with the classification of a malignant tumor histologically. The other features as mitotic figures, pleomorphism and basophilia are all helpful, but as they may be seen in non-malignant processes, they are not as absolute in their value. This is called a mammary gland adenocarcinoma. These can be graded as to their degree of malignancy by experts.

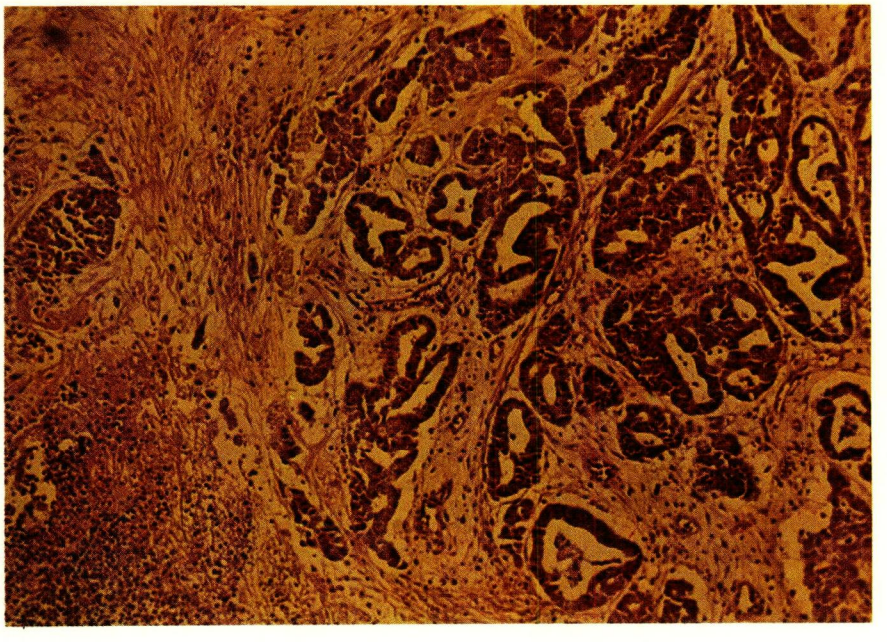



PLATE 249: SCIRRHOUS CORD AND URINARY CELLULITIS (PHLEGMON)

The right scrotal area is massively swollen and firm as a result of infection that originated from the castration wound seen on its surface. Many organisms may be isolated from such a lesion. In addition, this picture shows a massive ventral abdominal wall swelling with marked superficial congestion, hemorrhage and necrosis. When incised, much fibrin and edema was found about the scrotal tissues, and a massive amount of bloody and watery fluid with a urine odor was present in the swollen ventral abdominal wall tissue. Further examination showed that the penis had been ligated causing a subsequent urethral rupture with urine leakage into the tissues. This end result can be considered an internal chemical burn. At first glance, a large mass in this area can also be considered an inguinal hernia.

PLATE 250: TRUE HERMAPHRODITE

A large vessel is in the junctional zone between the multiple hypoplastic spermatic tubules and the large mass of ovarian tissue. The seminiferous tubules are lined with Sertoli cells only and are surrounded by interstitial tissue. Hermaphroditism occurs frequently in swine and ruminants. One often has to section many areas of the suspected gonadal tissue to show that both sex tissues are present.

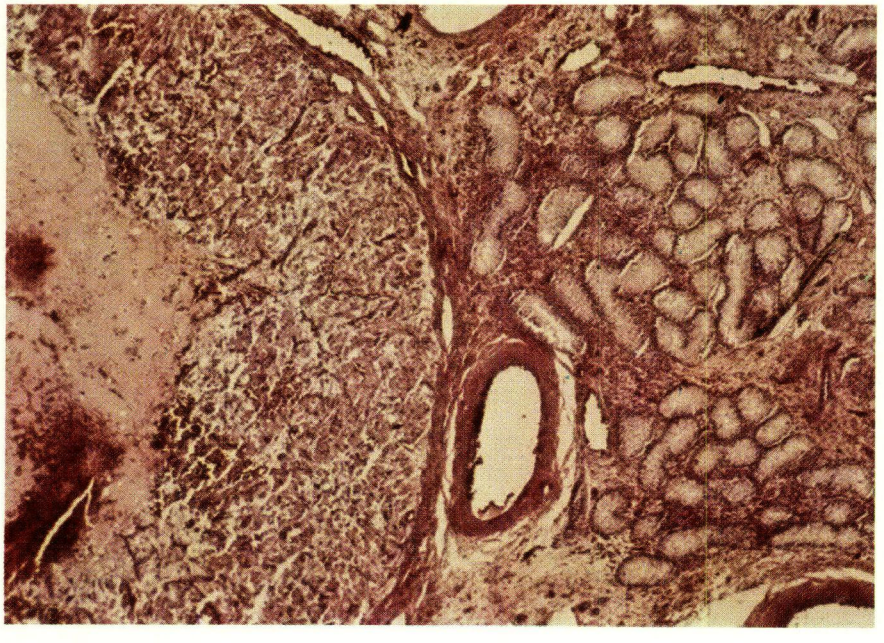



PLATE 251: MALE PSEUDOHERMAPHRODITE

The two brownish masses buried in the fat are kidneys. The slightly pinkish masses on the outside of each kidney are the testicles with the whitish band of epididymis on their surface. Winding away from the testicles in a tortuous fashion are the uterine horns which opened into a relatively normal vagina (not shown). The penis was absent, and no ovarian tissue was found. A pseudohermaphrodite has genitalia of one sex, but the gonadal tissue is of the other sex. A true hermaphrodite has gonadal tissue of both sexes with varying amounts of other genital structures.

PLATE 252: ECTOPIC LYMPH NODE

The greyish, 2 cm. mass at the beginning of the spermatic cord as it leaves one testicle is a normal lymph node that was apparently displaced in embryological development. Its intended original location was not ascertained. This can be considered ectopia, as it is a normal tissue out of place.



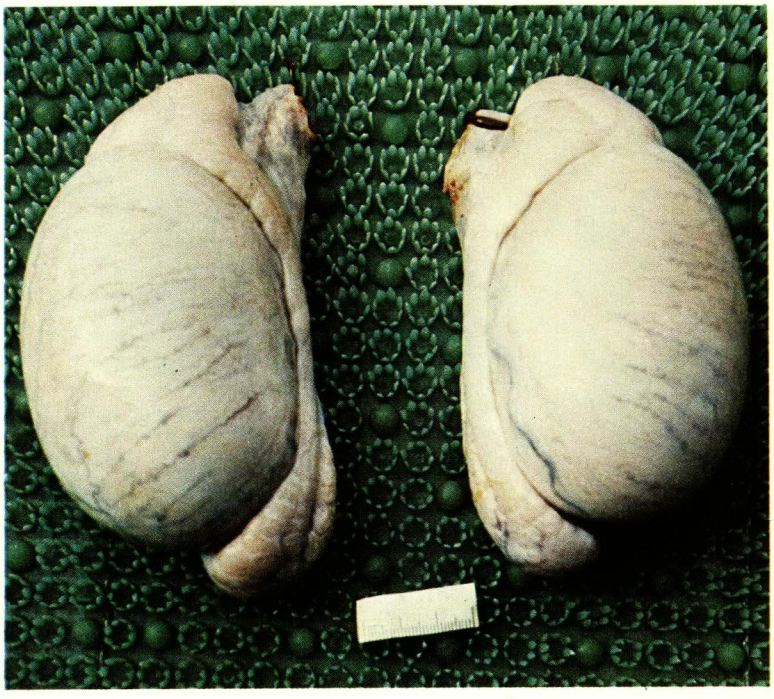

PLATE 253: NORMAL TESTICLES

Often in cases of atrophy, hypoplasia or hyperplasia, the changes are difficult to recognize unless one uses controls for comparison.

PLATE 254: TESTICULAR ATROPHY AND GRANULOMA FORMATION

Both testicles are smaller than normal as evidenced by the relatively large epididymis which is shown on the one testicle. The other testicle has been turned over to show the small mass of granulation tissue at the outer curvature of the testicle proper in the junctional area with the rete testis. The epididymis on this side of the testicle is narrowing down normally to form the ductus deferens. Granulomas may be caused by several infectious agents and Brucella spp. should be considered first. The cause of the atrophy is not known, but by applying "the KIS principle", we should consider that the granulomatous process may be related.

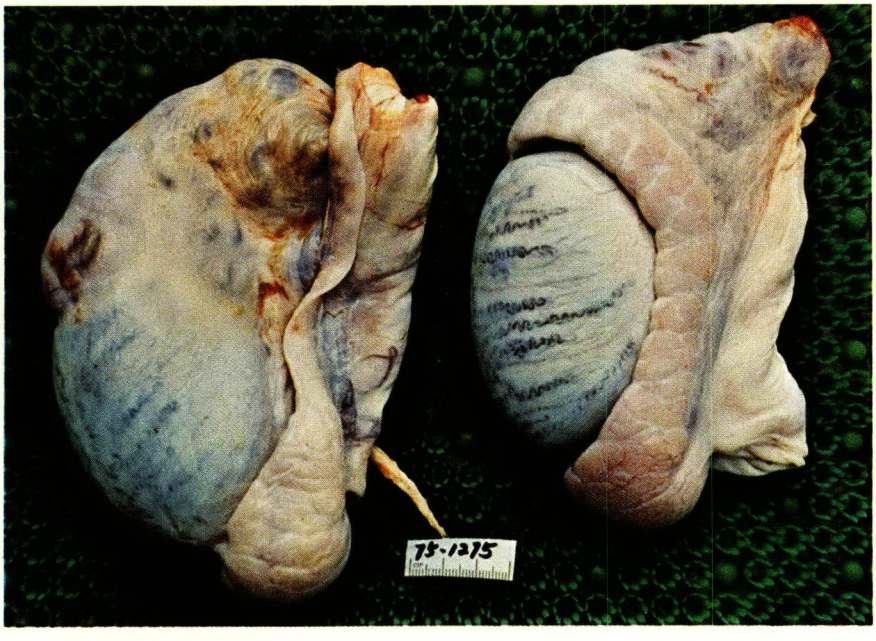

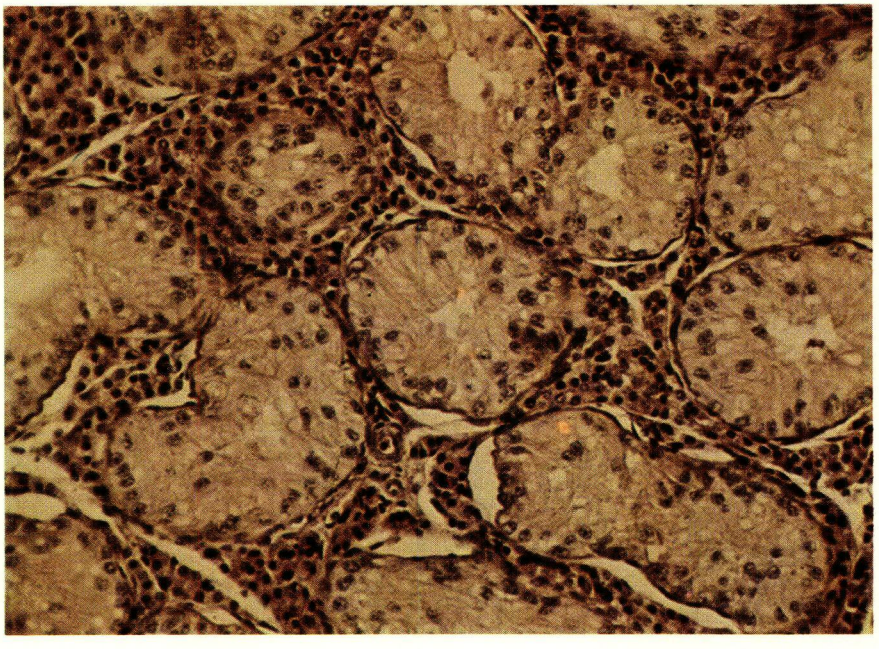

PLATE 255: TUBULAR HYPOPLASIA

The tubules are greatly reduced in size and contain only a relatively few rather uniform epithelial lining cells (Sertoli cells). There is a relative increase of interstitial cells, all quite similar with an eosinophilic cytoplasm. This testicle was also grossly reduced in size and located in the abdominal cavity (cryptorchid).

PLATE 256: TUBULAR DEGENERATION

The tubules for the most part lack the normal multiple layered epithelial cells in this adult pig which at one time was a normal breeding boar. A few basal and supporting cells are present in their place. Many chronic inflammatory cells have infiltrated the stroma. An allergic orchitis was suspected but not proven grossly. The testicles were greatly reduced in size (atrophy) from what they once were. Infections, vascular problems and trauma could result in similar changes.

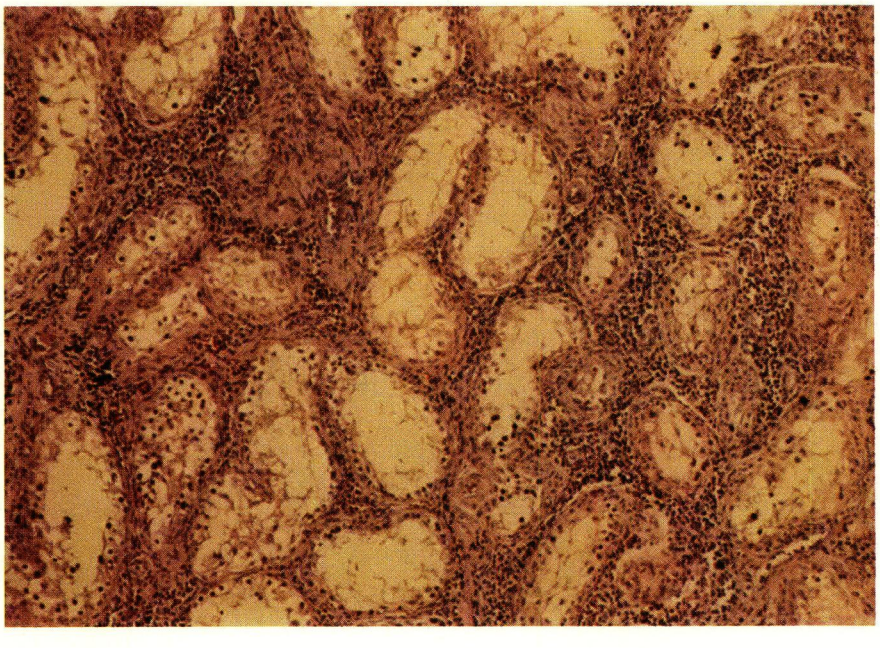



PLATE 257: SPERMATIC GRANULOMAS

The many yellowish foci scattered throughout this goat's testicle and epididymis are granulomas caused by the escape of sperm from the tubules into the surrounding stroma. They have caused a foreign body reaction in these foci, many of which may have Langhan's type foreign body giant cells associated with them. An acid fast pigment found in the sperm may be the actual cause of the giant cells proper. The cause for the sperm leakage is unknown in most instances unless a predisposing factor such as trauma or an infection is found.

PLATE 258: SPERMATIC GRANULOMA

Large numbers of multinucleate giant cells, chronic inflammatory cells and sperm are present in this portion of the granuloma. Some eosinophilic debris, as well as many sperm, have been phagocytized by the giant cells. With an acid fast stain, much positive pigment can often be demonstrated in such an area. Infections in which Brucella spp. is often found as well as trauma and even an allergic process may result in this lesion. This lesion is common in older goats.

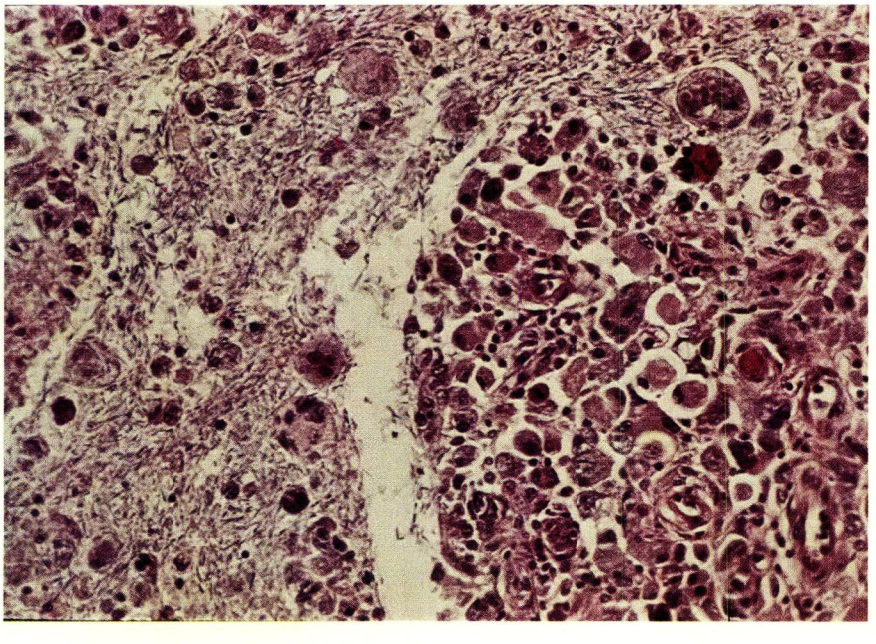

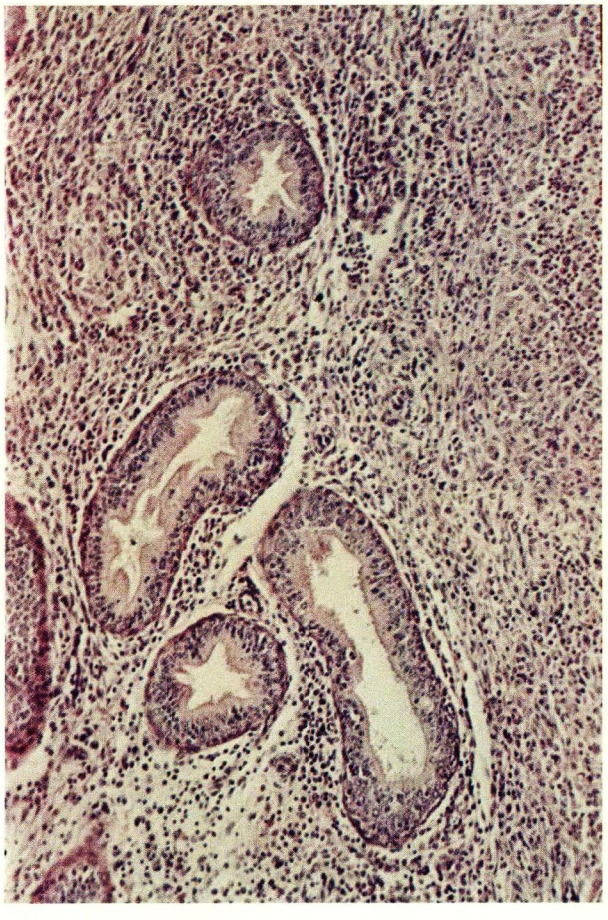

PLATE 259: EPIDIDYMITIS

A large number of round cells, including many plasma cells, have infiltrated this area separating the tubules. A few clumps of neutrophils are also present. Grossly, this was a swollen, reddened focus in the epidiymis. The type of inflammatory cells suggests a chronic process as that caused by an infectious agent or a leakage of sperm with "sperm granuloma" formation. The plasma cells also suggest an autoimmune process as may be seen in other endocrine organs such as the thyroid, adrenal, and pituitary. This is from a case of allergic orchitis.

PLATE 260: INTERSTITIAL CELL TUMOR (LEYDIG CELL TUMOR) AND GRANULOMATOUS EPIDIDYMITIS

The single, reddish, discrete mass in the parenchyma of one testicle on this dog is an interstitial cell tumor, the most common testicle tumor in dogs. It is a soft tumor and usually more yellowish than this example. This one has more blood present. The other two rather common tumors are the seminoma and the Sertoli cell tumor (sustentacular cell tumor). The seminoma is the one most likely to become malignant. It is pale white and rather soft, while the Sertoli cell tumor is often grey, firm and glistening on the cut surface. The Sertoli cell tumor is prone to hormone production which causes sexual attraction, some alopecia, a pendulous abdomen and nipple enlargement. This latter neoplasm has a tendency to develop in cryptorchid testicles. The other testicle is essentially normal but the epididymitis shows a marked connective tissue reaction and swelling, as a result of a Nocardia spp. infection.





PLATE 261: EPISTAXIS (NOSEBLEED)

In living or recently dead animals when one sees relatively fresh blood or blood mixed with mucus or froth from the nares or mouth, one should suspect such things as trauma, foreign bodies, atrophic rhinitis, pneumonia or even a bleeding gastric ulcer with vomition. It is also common to see this with extreme exertion and dyspnea. In a decomposed carcass, the blood from the normal pulmonary bed or nasal cavities may escape and drain out via the nose, but in this case it would be an artefact.

PLATE 262: CLEFT PALATE (PALATOSCHISIS)

The roof of this piglet's mouth should be a solid structure, but instead it has an elongated opening directly into the nasal cavity on both sides of the nasal septum. This is an anomaly and it is usually fatal as the newborn animal cannot get suction for nursing. Most consider this a genetic defect and the "drastic slaughter" method of control is advocated.

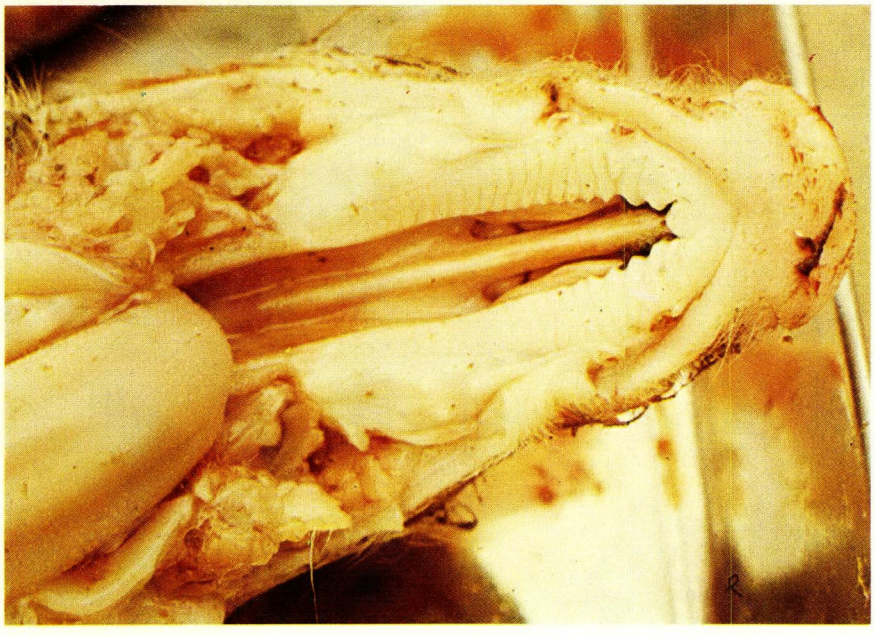



PLATE 263: DEVIATION OF THE SNOUT

This crooked snout can be caused by several things including various types of infections early in the animal life that localize in the nose. Both atrophic rhinitis and bull nose (S. necrophorus infection) should be prime suspects.

PLATE 264: BULLNOSE

The right side of this pig's snout is greatly swollen and this has caused a deviation of the snout to the left. This is a case of "bullnose" caused by Spherophorus necrophorus. A wound near this area probably served as the portal of entry for these organisms.





PLATE 265: ATROPHIC RHINITIS

The one nose has essentially normal thick turbinate scrolls. The other three all have their turbinates affected to varying degrees. In one, the turbinates have atrophied and in addition the nasal septum is deviated to help enlarge the nasal cavity even more on that side. There are some investigators that consider a bacterial agent, Bordetella bronchiseptica, as the primary cause, while others think it a nutritional problem. In a recent survey by the authors, over 85 percent of the cases examined were bilaterally symmetrical which is unlike other bacterial diseases.

PLATE 266: ATROPHIC RHINITIS (AR)

The first four snouts, starting in the upper left, are considered essentially normal, with the remaining nine snouts showing varying degrees of AR. It is to be noted that the ventral turbinates are more affected than the dorsal turbinates, and that all but one are almost bilaterally symmetrical. This symmetry is not the usual finding in bacterial diseases. Much work has been done to prove that this disease is caused by an infectious agent, Bordetella bronchiseptica, and even a vaccine is in vogue. There are some who consider it a nutritional problem. The snouts were cut through on a line with the corners of the lips to get a uniform plane of section for comparative purposes.



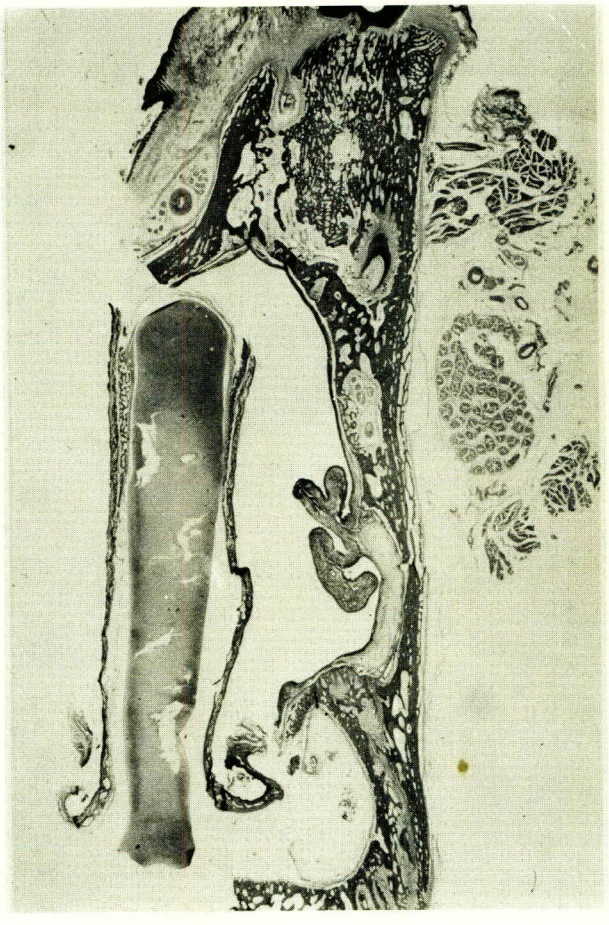

PLATE 267: ATROPHIC RHINITIS

The nasal septal cartilage is present as a long mass of homogenous tissue on one side of the picture. Opposite it are the two small irregular masses that represent the markedly atrophic remains of the dorsal and ventral turbinate bones on that side. In any swine herd with this disease, one may see the entire gamut of atrophic lesions from just visible atrophy to lesions this severe and worse.

PLATE 268: ATROPHIC RHINITIS

This section is through a complete section of an atrophied turbinate. Columnar epithelium is present on the surface and large numbers of round cells are scattered in the remaining tissues which are mainly loose connective tissue, relatively hypertrophied arteries and dilated other vessels. There is a complete loss of all bone and cartilage in this chronic case of atrophic rhinitis.





PLATE 269: CRYPTOCOCCOSIS

The large, yellowish green, multilobulated mass in the right nasal cavity of this adult horse's nose is a granulomatous formation caused by Cryptococcus neoformans. It was originally thought to be a tumor, but impressions and subsequent study showed it to be a chronic inflammatory disease. This is another example of calling a "lump" until proven otherwise.

PLATE 270: LYMPHOMATOSIS

Several large round masses are in the tissues of both nasal cavities in this cow's head. On the one side, there are several teeth missing and a large mass of packed hay is in the cavity above the missing teeth. Surrounding the impacted food stuff, the neoplasm is yellowish green with necrosis. It is apparent from this that the lymphoid neoplasm caused the loss of teeth with the resultant impaction. The roundish masses in both nasal cavities are areas of tumor invasion.





PLATE: 271: NASAL ADENOMA

In the nasal cavity just under the frontal sinus, a large, reddened, cystic mass is present that encompases both the dorsal and ventral meatus. Two of the large cysts have been opened in the ventral meatus and a clear, viscid fluid escaped. The caudal portion of the lower mass that projects toward the pharynx has a yellow, necrotic surface. Many types of masses could be in this area such as a foreign body granulomas, abscesses, misplaced teeth (anomalies) or as in this case, a tumor. The viscid secretion, cystic character and absence of other features suggests its neoplastic nature. Histologically, it is a glandular tumor of the olfactory epithelium that arose from the epithelium of the cribiform plate at the rear of the dorsal meatus. This is called a transmissible respiratory adenoma of sheep.

PLATE 272: THROAT BOTS

The two bots (fly larvae) in the granulomatous opening on the right side of the pharynx of this caribou are larvae of Oedemamagena tarandi, the throat bot. Other bots of importance include the nose bot (Estrus ovis) of sheep, the stomach bots (Gastrophilus spp.) of horses, Cuterebra spp. in cats and the warbles (Hypoderma spp.) in cattle. The pouch opening shown above was formed by these bots and from several to a hundred or more bots may fill the pocket produced. This pouch is not to be confused with the resonant chambers some similar animals may have.





PLATE 273: PETECHIAL HEMORRHAGES

These pinpoint and slightly larger hemorrhages on the tongue and epiglottis of this pig are petechiae. They are commonly seen in many septicemic diseases of pigs and other species, but when found in cases suggesting hog cholera, they are quite useful diagnostically. Such hemorrhages may be seen in animals that die with exertion and thus they have to be interpreted carefully.

PLATE 274: HYDROTHORAX

Excess pleural fluid may be seen in both inflammatroy conditions, such as polyserositis, and in non-inflammatory ones such as heart failure, heart anomalies and hypoproteinemias. In this case of a heart anomaly, the lung is also slightly enlarged and heavy on palpation from passive congestion. A left sided heart problem should be first suspected, such as a stenotic aortic valve or an incompetent mitral valve which would allow passive congestion in the pulmonary bed. It is often difficult to differentiate grossly a transudate from an exudate because a transudate often contains enough fibrinogen to clot to form fibrin upon exposure to air. It can be seen here as a thin band lying on the lung proper. A slight amount of blood has accidentally contaminated the once clear fluid in this case.

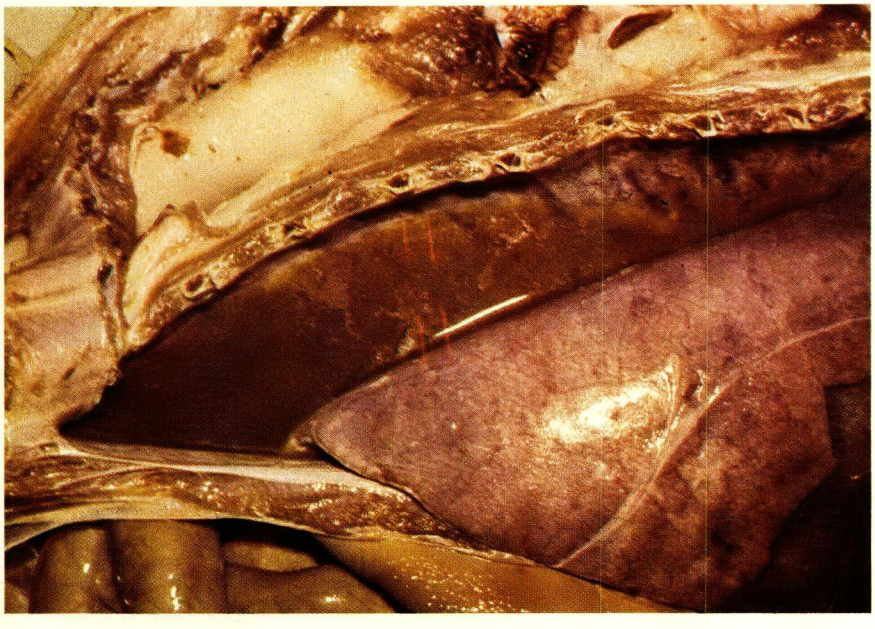



PLATE 275: SEROFIBRINOUS PLEURITIS

The slightly bloody fluid in the pleural cavity and the several strands and clumps of fibrin on the lung surface, along with the excess fluid in the pericardial sac suggests the diagnosis of polyserositis. The several dark lung lobules in the apical lobe represent fetal atelectasis, areas of lung not yet expanded with air, possibly from amniotic fluid or mucus still being in the airways. Hemophilus spp. among other organisms may be cultured from such serositis cases. In the in vitro culturing for this organism, one should recognize its need for special growth factors which are supplied in part by a Staphylococcus spp. streak on the culture plate.

PLATE 276: FIBRINOUS PLEURITIS

The entire pleural surface, both costal and visceral, is covered with a thick layer of pale fibrin. The slight amount of pleural fluid was accidentally contaminated with blood as the original fluid was clear which is shown by the fibrin mass being not blood colored. While most cases of pleuritis are secondary to ruptured lung abscesses, there was no such lesion found in this animal. This is a case of primary pleuritis, probably polyserositis.

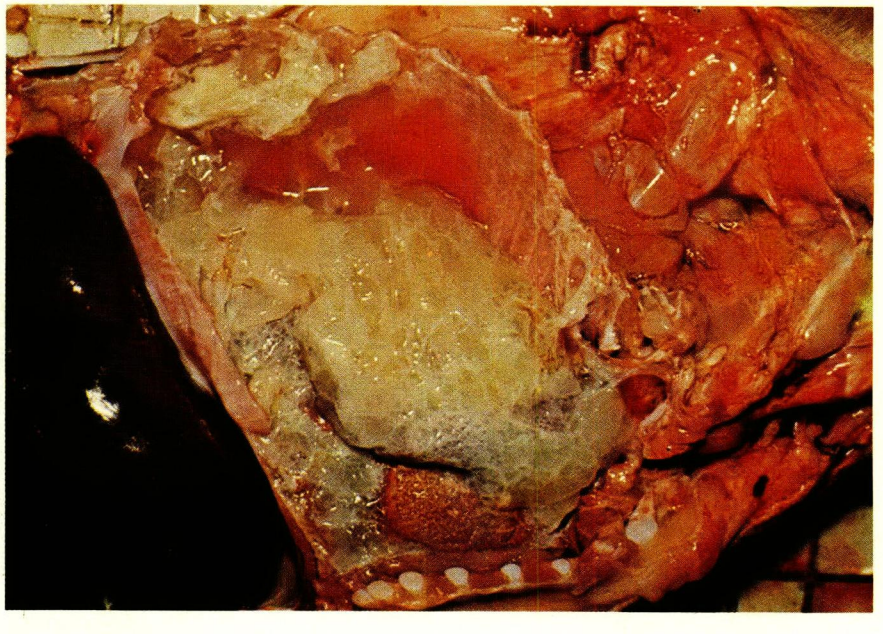

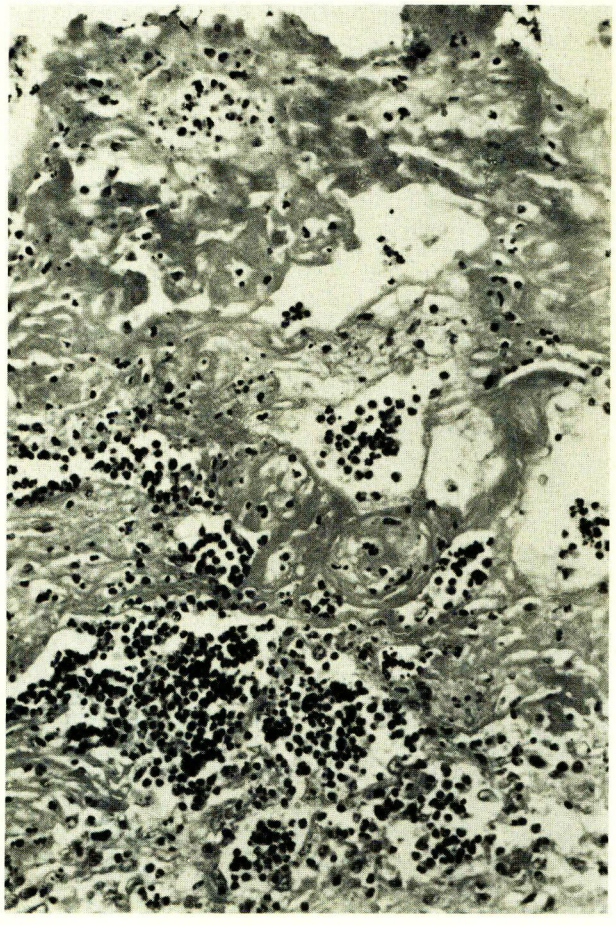

PLATE 277: FIBRINOUS SEROSITIS

In this photograph, large numbers of neutrophils and other blood cells are enmeshed in clumps and strands of amorphous fibrin. Such a lesion can be found in any acute inflammation of serous membranes. A later stage would have more lymphocytes and less neutrophils. This is from a case of Glasser's disease (polyserositis).

PLATE 278: CHRONIC ADHESIVE PLEURITIS

Numerous thin, but strong connective tissue strands and bands are adherent between the costal, diaphragmatic and visceral pleura. This is often confused with, and must be differentiated from, fibrinous adhesions which are easily broken strands of tissue in an acute inflammatory process. One should remember that it takes weeks for connective tissue to form but only seconds for fibrinogen to become fibrin under the proper conditions. The connective tissue adhesions pictured here are probably the sequelae of an acute fibrinous pleuritis that occured some time ago as with Glasser's disease (polyserositis).

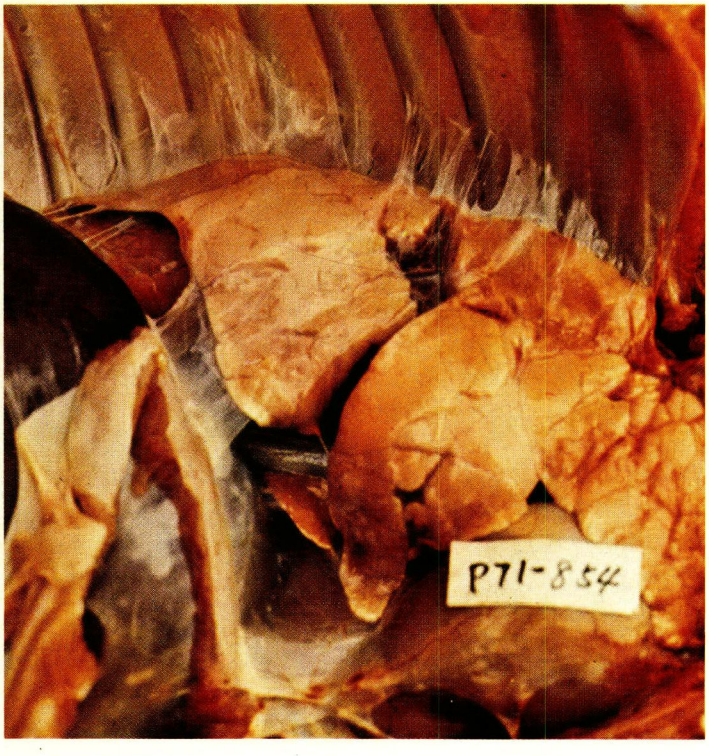



PLATE 279: EMPYEMA (SUPPURATIVE PLEURITIS, PYOTHORAX)

The chest cavity is partially filled with a purulent, cloudy, foul smelling fluid with bits and pieces of necrotic and bacterial debris. The cardiac and apical lobes are collapsed (acquired atelectasis) as a result of the increased pleural pressure. Some granulomatous proliferation of the chronically inflammed mediastinal pleura, especially along the sternum, is also present. Many different bacteria may be isolated including Nocardia spp.. The bacteria are almost always secondary to a ruptured lung abscess as from a foreign body pneumonia. A diligent search is often necessary to find the primary lesion which may be very small as it was in this cat.

PLATE 280: UREMIC FROSTING (PLEURAL MINERALIZATION)

The yellowish, small streak like patches, perpendicular to the ribs in the intercostal spaces are deposits of mineral, mostly calcium salts. They are more concentrated in the first and second intercostal spaces, but with time they will become progressively more severe caudally. When severe enough, the material can be palpated and cut with a gritty (sand like) sensation. Although seen in other species, it is most common in dogs with chronic renal failure. When seen, other lesions of renal failure such as gastric and vascular mineralization, parathyroid hypertrophy, renal osteodystrophy and visibly apparent diffuse renal lesions should be looked for. Hypervitaminosis D can make a similar lesion in the pleura.



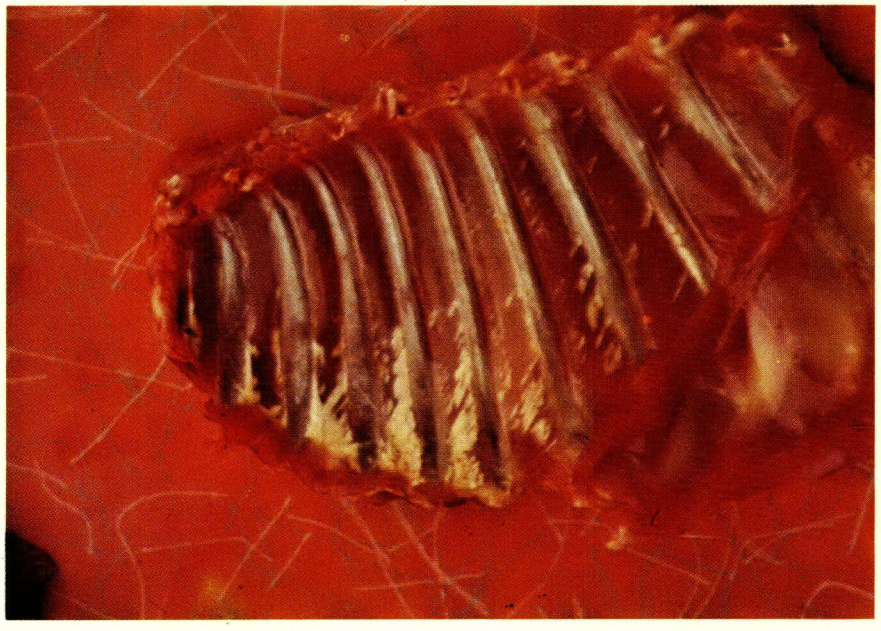

PLATE 281: CHOLESTEROL DEPOSITION

In the pleura of the intercostal spaces are many whitish, soft, streaked depositions of cholesterol in this experimental rabbit fed a 4% cholesterol diet for several months. Its distribution is similar to that for calcium salts in cases of renal failure. This helps demonstrate that it is probably a problem of metastatic deposition from the high level in the blood, and not an example of dystrophic deposition with prior damage to the area. This process is to be compared with metastatic and dystrophic mineralization.

PLATE 282: MEDIASTINAL EMPHYSEMA

The large pockets of air in the dorsal mediastinum were an incidental finding in this pig. This was the only emphysema found in this animal, but it is usually associated with emphysema of the lung proper from ruptured airways or alveoli. The air that escapes usually migrates dorsally to the mediastinum and from here to the subcutaneous tissues of the back. Of all the domestic animals, this is especially common in cattle.



LUNG LESIONS

Palpation and notice of gross distribution of lesions cannot be excluded from the interpretation of lung diseases. All pneumonias are firm on palpation and just being "dark" does not qualify to call the area pneumonic. It is also a common mistake to describe histological findings as diagnostic without regard to their gross distribution. Pulmonary lesions should be placed into one of the three following catagories which are self explanatory and fit most lung lesions as the examples demonstrate.

I. Focal or Multifocal
   - Embolic Shower
   - Dust Inhalation
   - Single Particle Inhalation
   - Lungworms
   - Most Granulomatous Infections

II. Locally Extensive
   - Pasteurella Pneumonia
   - Hemophilus Pneumonia
   - Fluid Inhalation
   - Mycoplasma Pneumonia

III. Diffuse
   - Toxoplasmosis
   - Proliferative Pneumonia
   - Heart Failure Lungs
   - Anaphylaxis

PLATE 283: MULTIFOCAL DISTRIBUTION

These multiple, reddened lesions, some with a raised yellowish central portion are an example of the multifocal distribution of lung lesions. This is an embolic shower from a vegetative endocarditis of the right heart, but it could just as easily be from a ruptured liver abscess, jugular vein or other venous site thrombosis draining into the right heart and hence into the pulmonary arterial bed. It is also possible that these could be the localization sites of bacteria, or mold in cases of septicemia. Some parasite migrations may also be suspect.

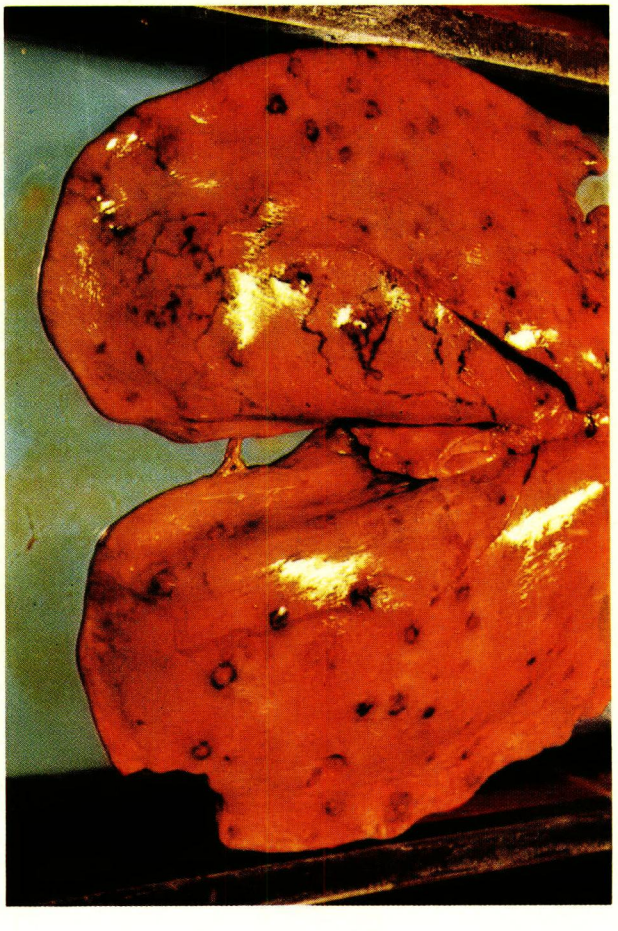

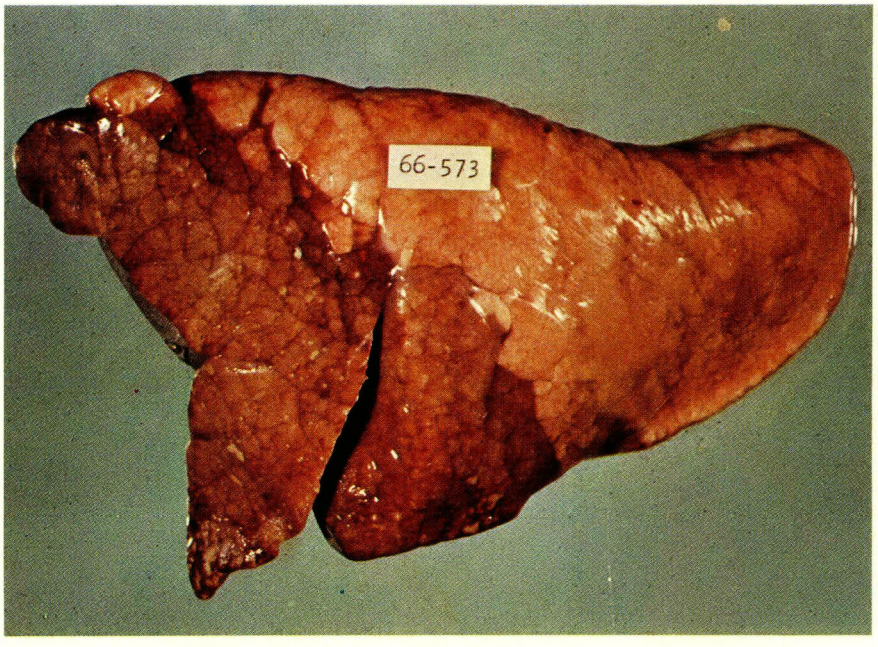

PLATE 284: LOCALLY EXTENSIVE DISTRIBUTION

The well delineated, firm areas in the cranio-ventral lobes of this left lung well demonstrate this type of distribution. Its actual cause, on the other hand, may be difficult to ascertain. What may be cultured from it at this late stage, probably after antibiotic therapy, may not have been the actual causative agent. Its distribution suggests that it can be the result of inhalation pneumonia, Pasteurella spp. pneumonia, or even bacterially complicated Mycoplasma spp. pneumonia.

PLATE 285: DIFFUSE DISTRIBUTION

This entire lung is swollen, firm, wet and heavy. The small pale foci are areas of emphysema, and the dark areas of the ventral left lung lobes are artefacts. Histologically, all lobes showed a similar lesion of marked alveolar lining cell proliferation and scattered larval nematodes. This was diagnosed as a case of proliferative pneumonia which is rare in the pig but quite common in the cow.

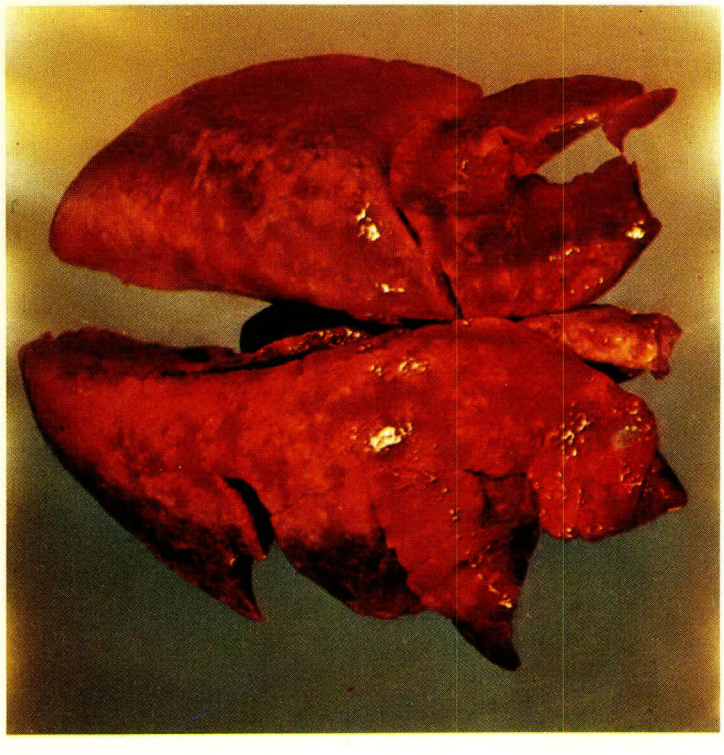

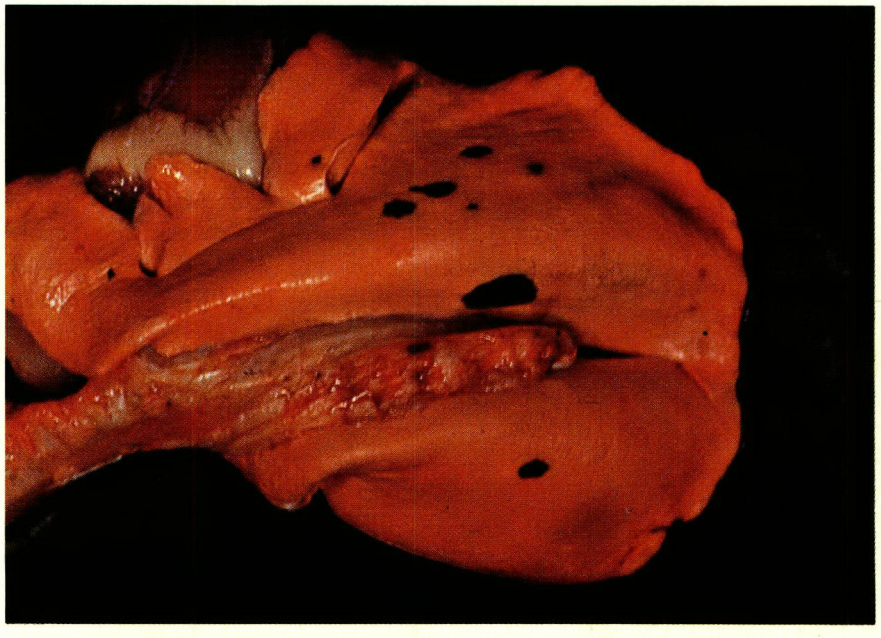

PLATE 286: MELANOSIS

The several discrete black foci in this lung are examples of normal melanin pigmentation. They are common in pigmented animals and may be seen in many tissues such as the uterus, adrenals, brain and meninges as well as occurring sporadically in other tissues. The mouth and skin are considered the normal locations.

PLATE 287: HEMOSIDEROSIS

The several scattered granules of brownish pigment are granules of hemosiderin, the iron containing portion of broken down red blood cells, in macrophages. This section is from one of several, large, grossly visible foci of brownish lung and probably represents areas of old hemorrhage as the tissue is essentially normal otherwise. If the entire lung was tan to brown, one could consider a hemolytic disease with increased red blood cell destruction generally or even a "heart failure lung" from blood stasis with red cell breakdown and phagocytosis.

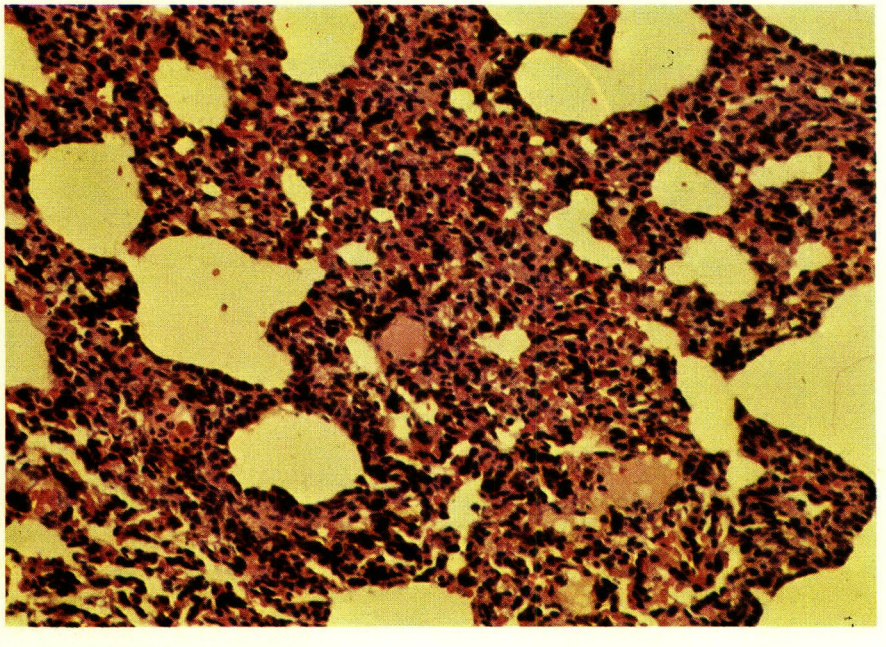

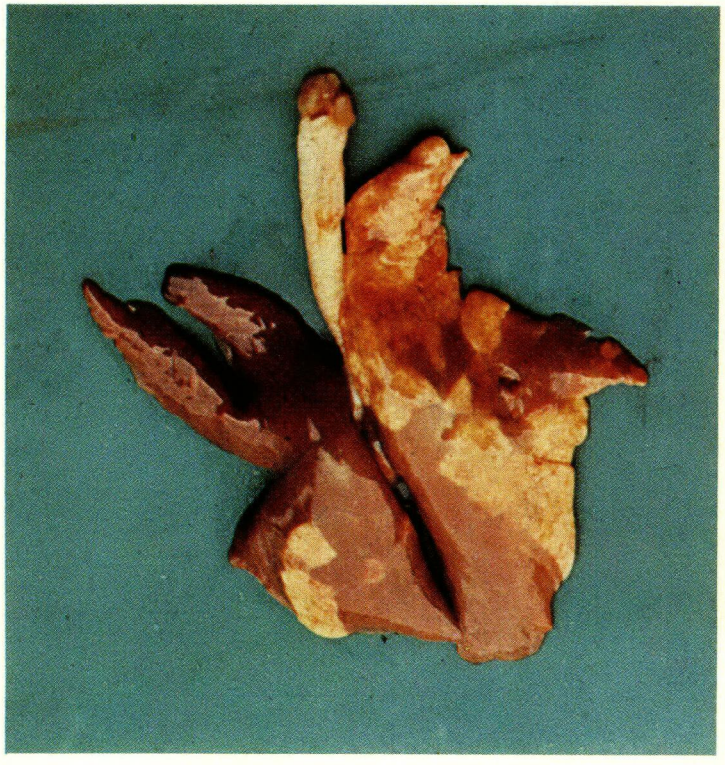

PLATE 288: FETAL ATELECTASIS

Scattered throughout the lobes are dark reddish areas of soft, pliable lung tissue which are sunken below the surface of the surrounding tissue. These are areas of lung that never have been expanded with air since the animal's birth and are still collapsed. By observation alone, it is often difficult to distinguish atelectasis from focal pneumonia. Fetal atelectases usually disappears by several weeks of age.

PLATE 289: ARTEFACTUAL ATELECTASIS

The dark area of lung near the surface is an area of collapsed lung tissue which has been produced by the postmortem pressure of the heart and other tissues pushing the lung against the rib cage. This was not present in the living animal, so it is an artefact. If this had occured during life, it would appear similar, probably affect the entire lobe and be called acquired atelectasis. The multiple tiny red foci scattered throughout the lobes are lesions caused by the small lungworm, Muellerius capillerius, in this sheep.

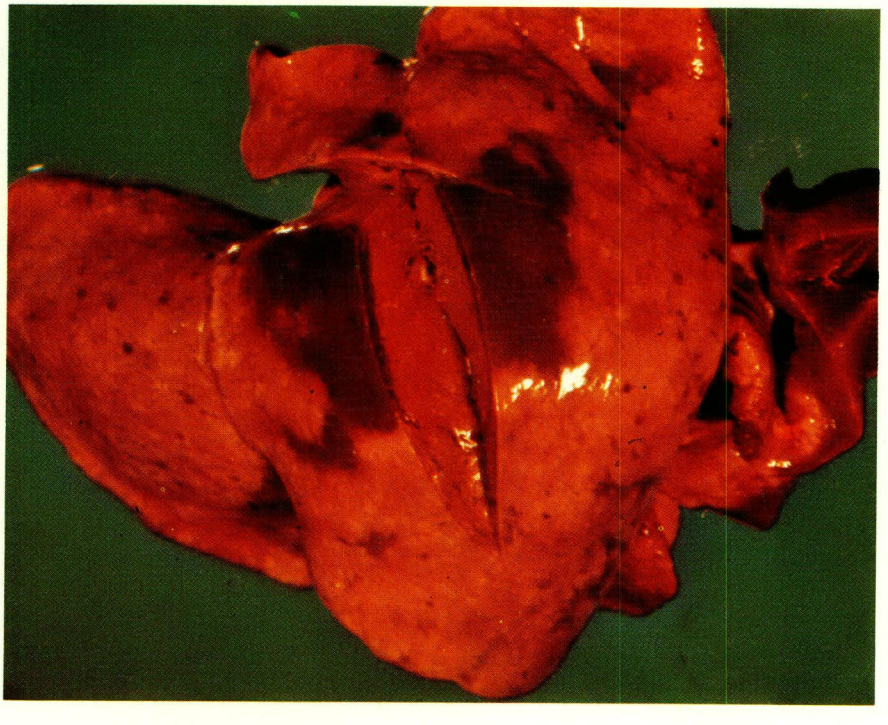

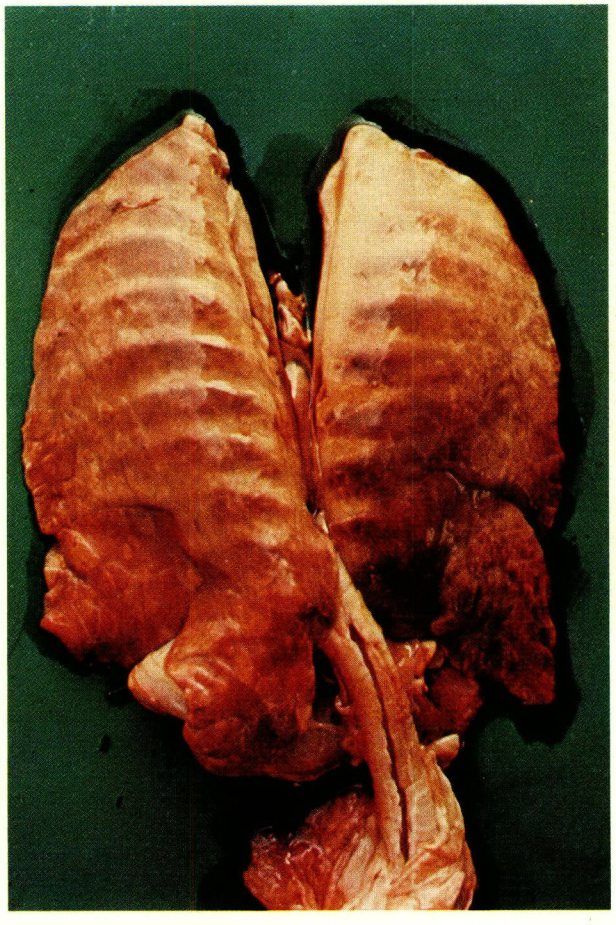

PLATE 290: PULMONARY CONGESTION, EDEMA AND EMPHYSEMA

The markedly inflated lungs clearly show multiple rib impressions on both major lobes. This is from a young pig dying of septicemia. It apparently died slowly allowing blood serum to escape into the alveoli and airways. This serum was in turn mixed to a froth with air by respiratory movements which effectively blocked air flow leading to the terminal emphysema. While this may have been the actual cause of the animal's death, it was not a factor in its disease except to terminate the process.

PLATE 291: PULMONARY CONGESTION AND EDEMA

Without a known cause such as anaphylaxis, a heart anomaly, an airway foreign body or the like, there is no such lesion as pulmonary congestion and edema. All such lesions should first be considered artefacts or at most postmortem hypostasis. Out of context, the above hyaline material (edema) in the alveoli and airway and the blood filled vessels (congestion) could just as well be postmortem hypostasis as well as an area of acute inflammation adjacent to an area of actual pneumonia. The history and gross findings are necessary to evaluate this lesion properly. The several, clear bubble like lesions in the airway and alveoli are trapped air pockets.

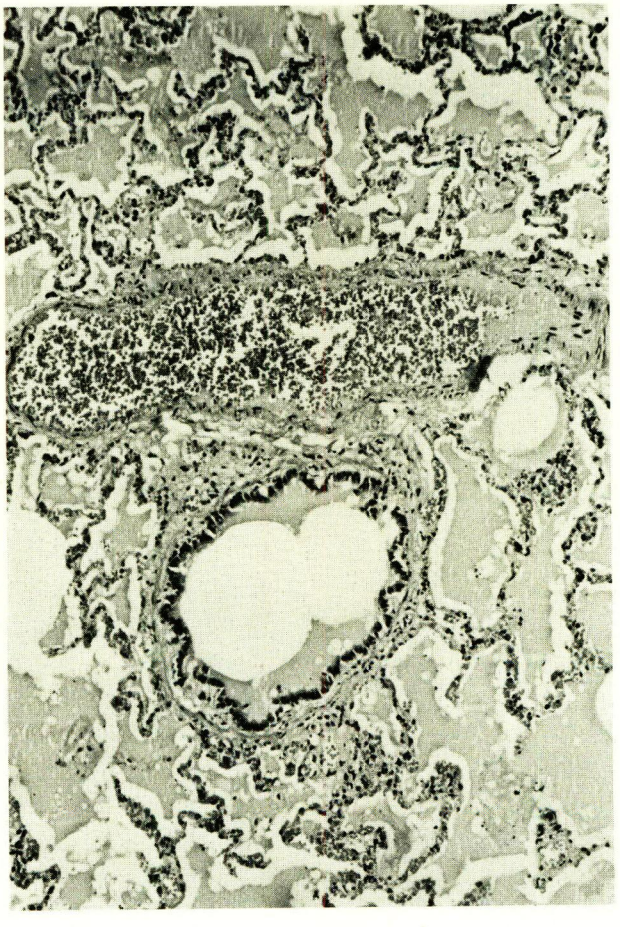



PLATE 292: TRACHEAL FROTH

The white froth with many air bubbles in the trachea and bronchi of this pig represents serum that leaked into the animal's alveoli and airways terminally, or even after death. It was mixed to a froth by terminal gasping or even the elastic recoil of the lung proper after death. By itself, it is almost never diagnostic. Many animals have this "lesion", even normal animals killed for necropsy demonstration.

PLATE 293: INHALED BLOOD

The numerous, dark reddish foci in both lungs that feel like the remaining parenchyma are areas of inhaled blood. The individually distinct areas in the anterior ventral areas of the three right lobes and the left cardiac lobe are slightly firm, pliable and probably represent areas of resolving bronchopneumonia. Inhaled blood may be seen in cases of severe exertion with ruptured lung vessels leaking blood into the airways. It is then partially expelled, but inhaled into other airways before it is completely expelled. It is also seen in bleeding gastric ulcers with vomition, atrophic rhinitis and at slaughter when the trachea is cut at the time of exsanguination.

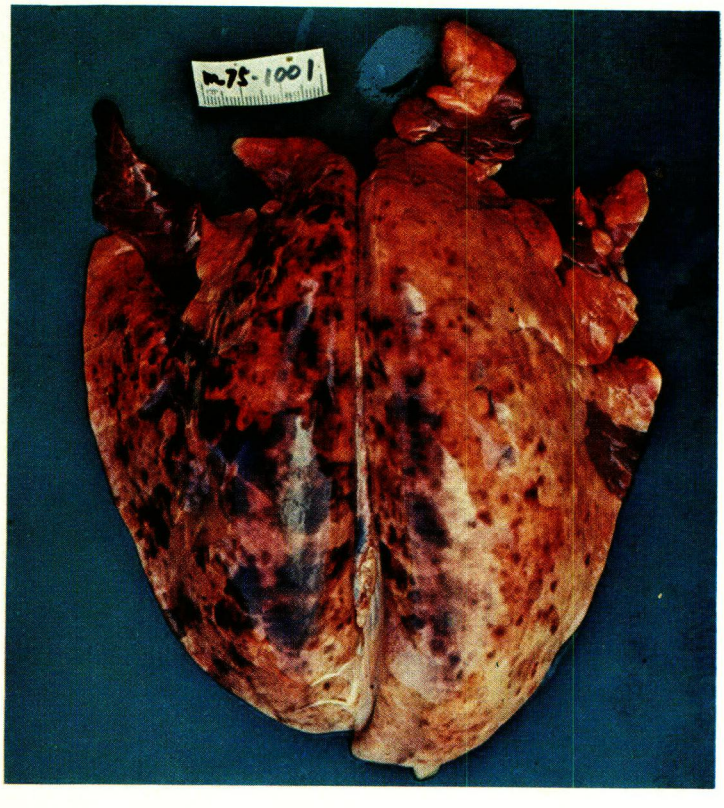



PLATE 294: PETECHIAE

The large number of 1-3 mm. (pinpoint to pinhead size) hemorrhages (petechiae) and the several, slightly larger hemorrhages (ecchymoses) scattered throughout the lungs are suggestive of the rather severe, virulent, septicemic process which this pig had. They are nonspecific by themselves as they may be seen in animals that undergo severe exertion just prior to death or even as a result of dying. They are common in horses dying with acute equine infectious anemia.

PLATE 295: BULLOUS EMPHYSEMA

The large pockets (bullae) of gas, usually air in cases involving the lung, can be seen in the interlobular septae of the lung and well marked in the middle portion of the dorsal mediastinum. This lesion is often a terminal one and of no great significance otherwise. In a relatively few cases, it may represent a significant lesion when an animal such as a pig is physically exerted and develops dyspnea which may help to kill it. In cattle with lungs notoriously prone to this as a lesion, one should be able to find the cause of the dyspnea that led to the lesion's development.



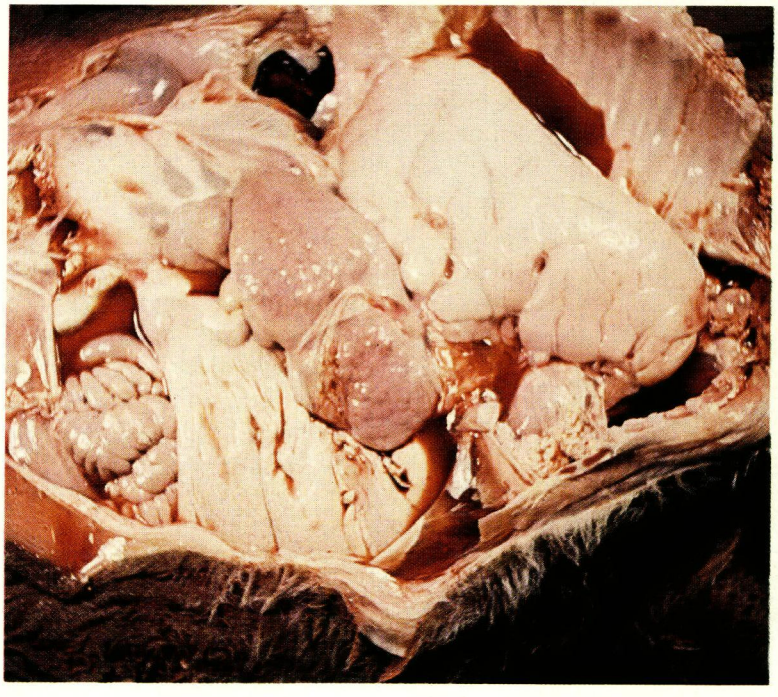

PLATE 296: BRONCHIAL HAMARTOMA

The only normal lung tissue present in this late gestationally aborted calf are the two pinkish triangular areas of the ventral tip of the right diaphragmatic and apical lobes. The remaining pleural mass is the firm, spongy hamartoma. Histologically, the hamartoma was a mass of dilated, cuboidal cell lined bronchioles. The liver is coarsely nodular from chronic passive congestion as the intrapleural mass restricted blood flow out of the liver. Some call this redundant amount of tissue, in a normal location, a fetal tumor while others consider it a developmental defect. Many are associated with vessels of the genitalia such as the vascular hamartomas of the ovary, etc..

PLATE 297: BRONCHIAL HAMARTOMA

The small triangular piece of tissue is normal newborn lung. Markedly dilated lumina of the abnormal bronchioles lined by cuboidal epithelium and thickened stroma make up the major mass of this hamartoma which filled 90% of the thoracic cavity and caused chronic passive congestion of the liver.

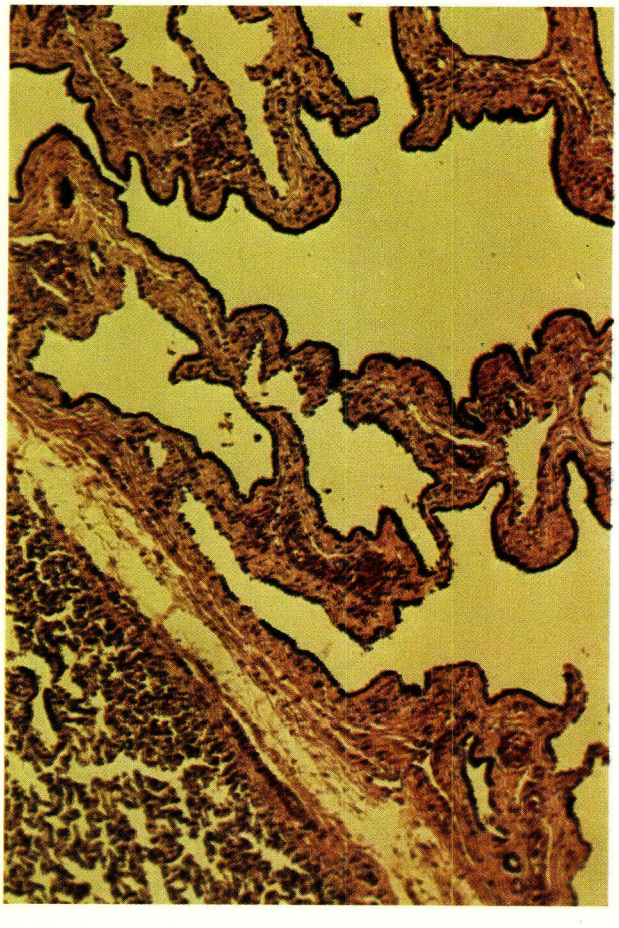



PLATE 298: PULMONARY EDEMA

The interlobular septae are distended with clear fluid (edema). The lungs are enlarged and heavy. Such a lesion is usually caused by anaphylaxis or a suddenly decompensated heart lesion as by an anomaly or Zenker's degeneration in white muscle disease. This pig died from the serum leaking into the alveoli and airways (pulmonary edema) where it was mixed to a froth to prevent air flow. This problem is to be differentiated from the more common terminal edema as a result of euthanasia in which there is tracheal froth and alveolar edema, but not interlobular edema as seen here. This piglet had a left side heart anomaly.

PLATE 299: CONGESTIVE HEART FAILURE

The diffuse wet lung with a slight tannish color, not as marked in this case as some, suggest that this lung had been affected with pulmonary edema and congestion for a prolonged period. In this case, a subaortic septal defect was present. On closer examination, the left apical and cardiac lobes are slightly shrunken and firmer than the remaining lung (swine enzootic pneumonia).

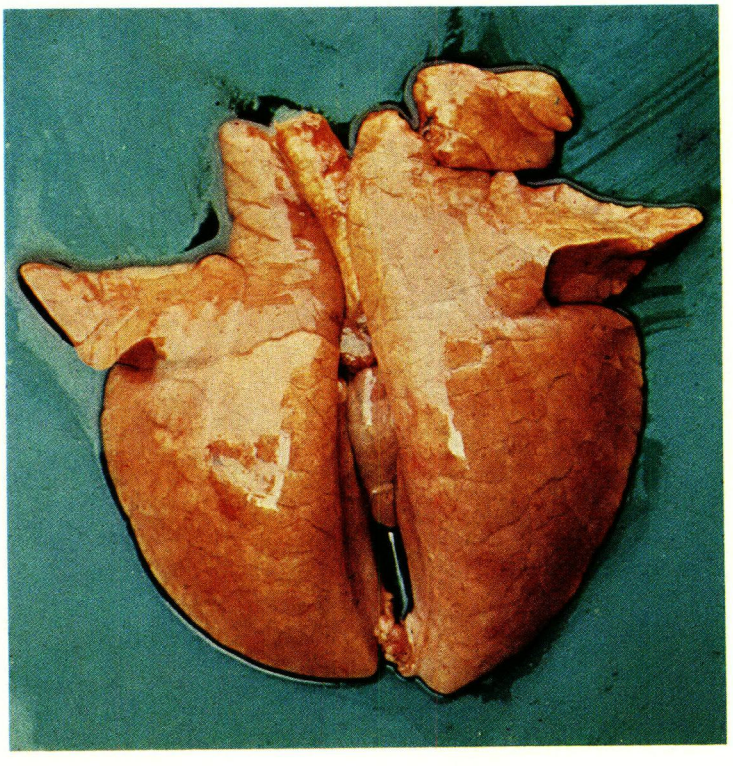

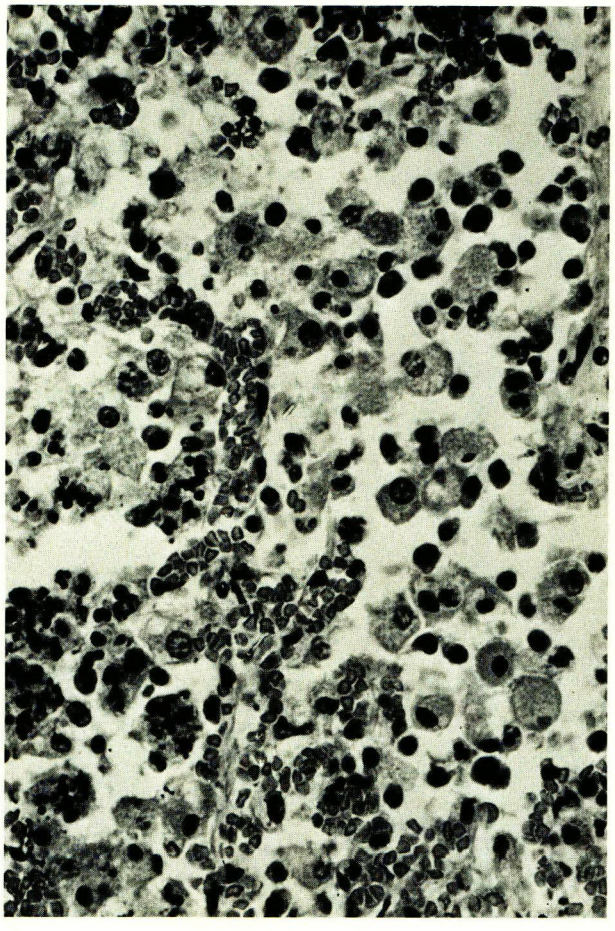

PLATE 300: HEART FAILURE LUNG

This high power magnification of the lung shows several alveoli partially filled with round, swollen phygocytes (heart failure cells), themselves filled with fluid and granular, red blood cell debris and pigment. This pigment helps give the lung the grossly tan to brown appearance. As the title suggests, this lesion is often the result of a failing heart. A tan lung may also be seen in cases of chronic blood destructive diseases as equine infectious anemia in horses.

PLATE 301: ANTHRACOSIS

The entire surface of the lung is sprinkled with fine, dark specks of dust, mostly carbon, in this city dog. In fact, it is scattered throughout the entire lung not just on the surface. The ventral portion of these lobes appear relatively less pigmented because of the terminal emphysema in these lobes. As this type of pneumoconiosis is nonreactive, the lungs feel normal. Histologically, the black pigment, in this case coal dust, is in macrophages scattered in the tissue. Draining lymph nodes get progressively darker as the phagocytes continue to clear the lung.





PLATE 302: ACUTE HEMATOGENOUS PNEUMONIA

The extensive distribution of this multifocal pneumonia almost resembles that of a diffuse pneumonia. The massive number of red foci are foci of acute pneumonia or petechiae caused by acute Salmonellosis. Some areas could even represent inhaled blood from rupture of small vessels. Several septicemic type organisms can cause this and a culture is necessary to determine which one. Edema and some emphysema is causing the lung to be enlarged and not collapse.

PLATE 303: HEMATOGENOUS PNEUMONIA

The many dark red foci, some of which have a discrete pale center, are multiple foci of a bacterial multifocal pneumonia. The red periphery is the inflammatory peripheral zone surrounding the small central core of purulent debris (abscess). Several complete lobules are even darker red and more diffusely involved. Most of the lobules are swollen, probably from emphysema resulting from the edema and the subsequent froth production blocking the airways and air outflow.

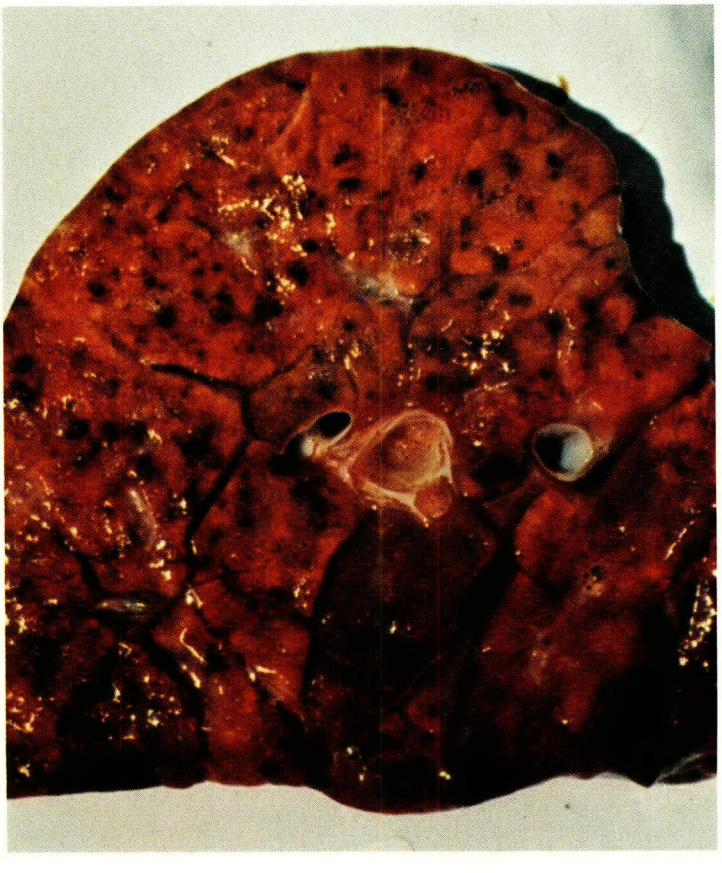



PLATE 304: EMBOLIC PNEUMONIA

This multifocal type of pneumonia shows many scattered pinpoint to several centimeter, firm, yellowish nodules with a reddish periphery. These are embolic abscesses. The pulmonic lesion itself usually does not involve a significant area of lung, but its nature of being embolic suggests that a more serious problem exists such as a vegetative endocarditis which is the source of the emboli. The right heart, or vessels leading to it as the jugular veins, and the caudal vena cava over a liver abscess, especially in the cow, are likely areas to search for the source of the emboli. The source was an infected uterus in this sow.

PLATE 305: EMBOLIC ABSCESSATION

The few abscesses seen in this low power picture are associated with blood vessels (hematogenous) and not with the airways which are mainly clear. In bronchopneumonia, the airways would be primarily involved.

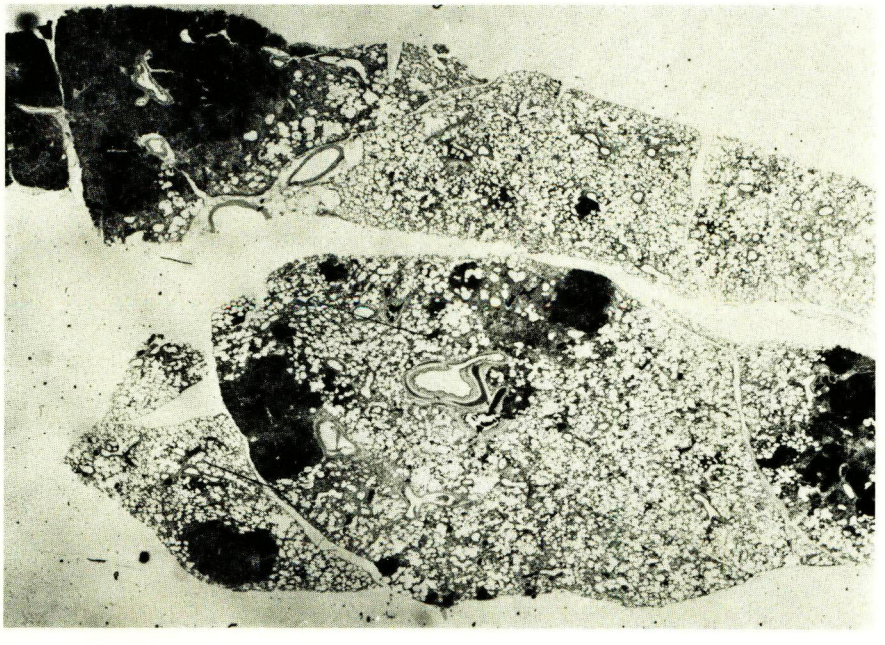

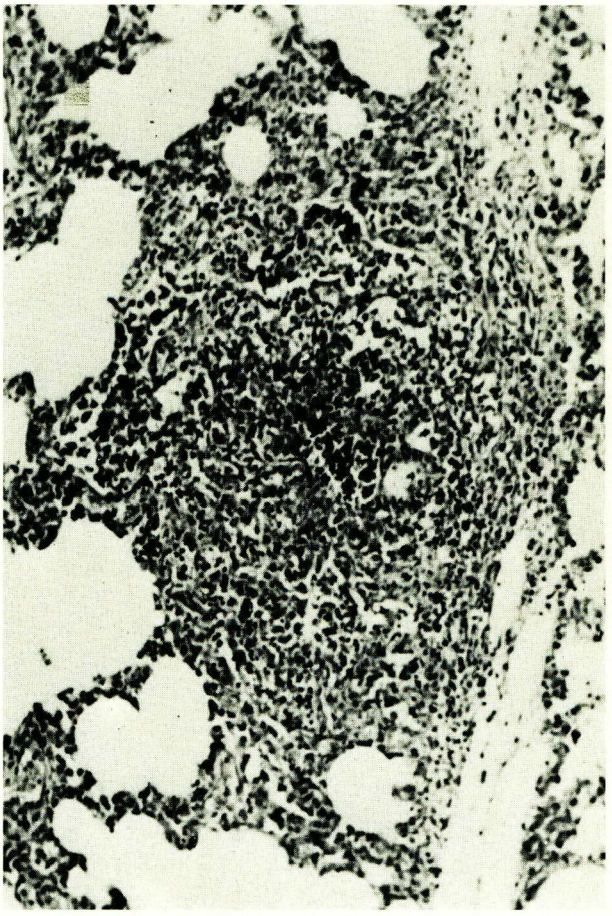

PLATE 306: HEMATOGENOUS ABSCESS

This individual abscess is one of many associated with a septicemia and the bacteria localizing in a typical hematogenous fashion throughout the lungs. A culture of this pig's lung revealed Shigella spp., but a number of bacteria or molds could just as well have been responsible.

PLATE: 307: EMBOLIC ABSCESSED PNEUMONIA

This single purulent focus was one of many, and consists of a purulent core of cellular and bacterial debris surrounded by a zone of inflammatory cells and then a zone of congestion and early connective tissue proliferation. At an earlier stage in this lesion or elsewhere in this lung, the vessel in which the lesion began would be seen and thus make one sure it was embolic in nature. The surrounding parenchyma, alveoli and airways, are essentially normal. One of many organisms could cause this lesion, but a hemolytic Staphylococcus spp. was isolated from this case.

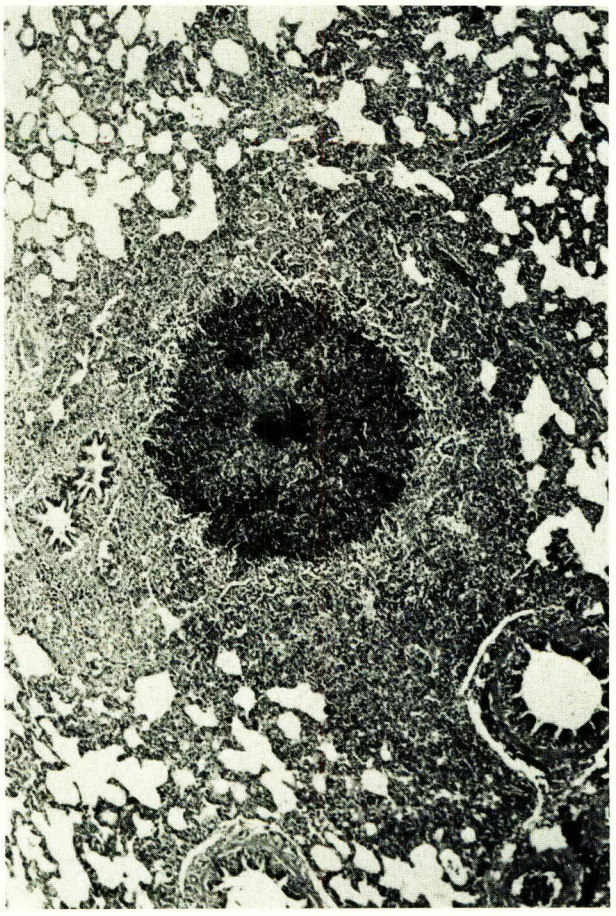

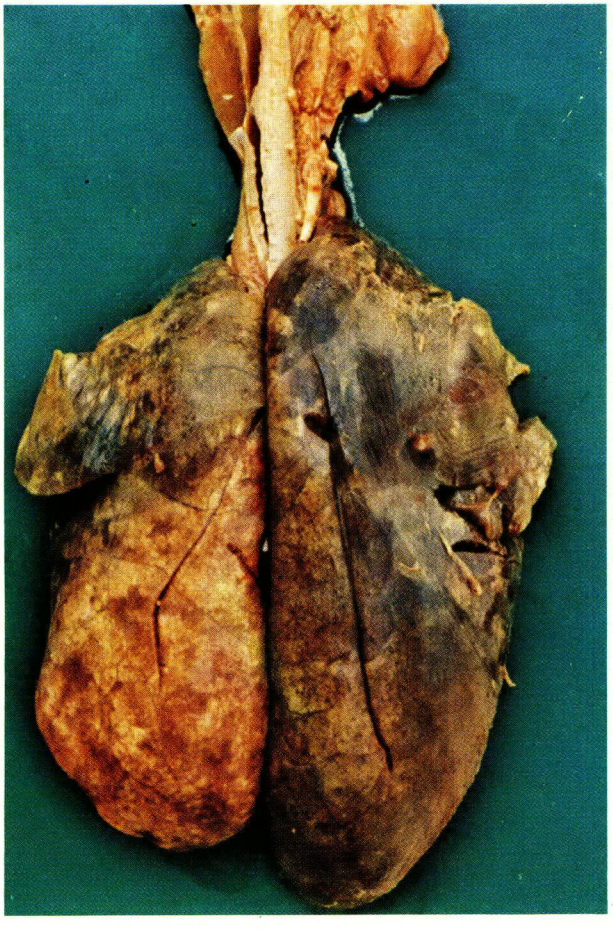

PLATE 308: GANGRENOUS PNEUMONIA (INHALATION, FOREIGN BODY PNEUMONIA)

The large locally extensive areas of pneumonia involve the cranial ventral two thirds of the right lung and the cranial one third of the left lung. These areas while not clearly separate from the normal areas are easily palpable. They are firm and coarsely nodular. Several fibrous adhesions have been broken down and appear as tags on the surface of the right lung. Different from single particle or dust inhalation, this case is suspected of being the result of fluid inhalation. Many organisms washed down from the mouth or throat could be the isolated agents if cultured. A history compatible with inhalation, such as recent worming by drenching, would be of benefit in making such a diagnosis. One can not rule out a secondary infection with gangrenous organisms superimposed on a preexisting less severe pneumonia. In many chronically damaged tissues as in "end stage" renal, hepatic or pulmonic lesions, one can not always be sure of the initial cause or pathogenesis.

PLATE 309: GANGRENOUS PNEUMONIA

The cut surface of lung shows many purulent foci with depressed, liquified, necrotic centers. The surrounding tissue is wet and firm with edema and congestion. An inhaled septic fluid is the suspected cause. Such a lesion usually has a locally extensive distribution and many different organisms are capable of causing this reaction with Pasteurella spp. commonly found.

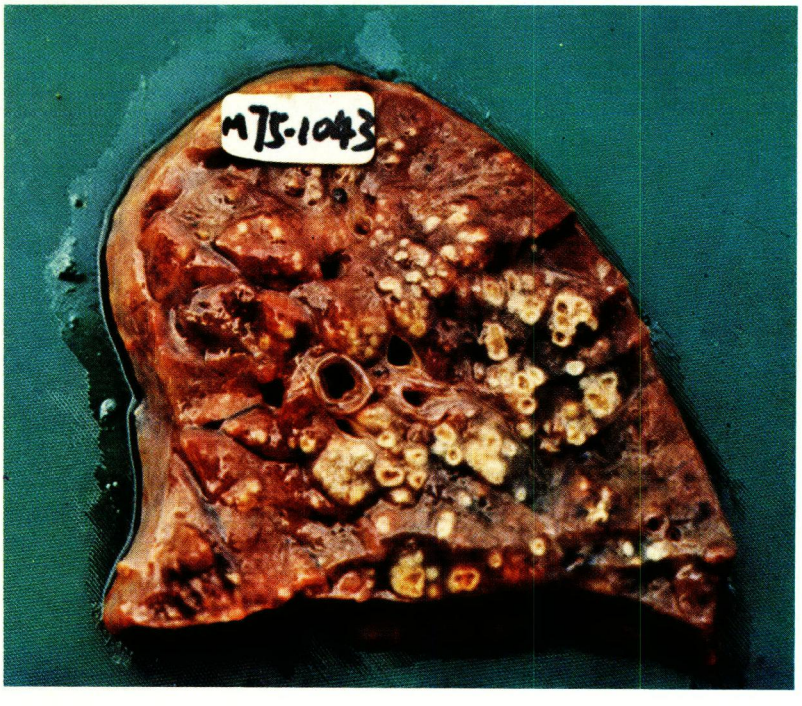



PLATE 310: CHRONIC BRONCHOPNEUMONIA

This single, firm, fibrotic mass of lung tissue with several more pale areas of abscessed debris in its center is an example of single particle inhalation pneumonia. There is a marked thickening of visceral pleura and interlobular septae with connective tissue. This single focus of a locally extensive pneumonia is 7 cm. along its longest edge in this adult horse. It caused a classical stimulation of periosteal bone near the ends of most long bones, hypertrophic pulmonary osteoarthropathy (HPO). Surgical removal of the causative lung lesion if possible usually causes some remission of the bone reaction. Most cases of HPO are associated with a pleural or thoracic cavity lesion, but some are seen with urinary bladder tumors.

PLATE 311: PURULENT PLEURITIS (EMPYEMA)

This partially collapsed lung (atelectatic) from a cat has much fibrin attached to its surface. When this left pleural cavity was opened, the collapsed lung was covered by a foul smelling, thick milky fluid with pieces of debris in it (pyothorax, empyema). When the purulent debris was washed from the lungs, an adhesion was found between the left cardiac and the cranial ventral left diaphragmatic lobe. Histological examination revealed the presence of a chronic purulent focus of pneumonia surrounding a piece of plant material in a small airway near the surface. This had ruptured into the pleural cavity to cause the purulent pleuritis. Over 90% of empyema cases in all animals have a similar cause.

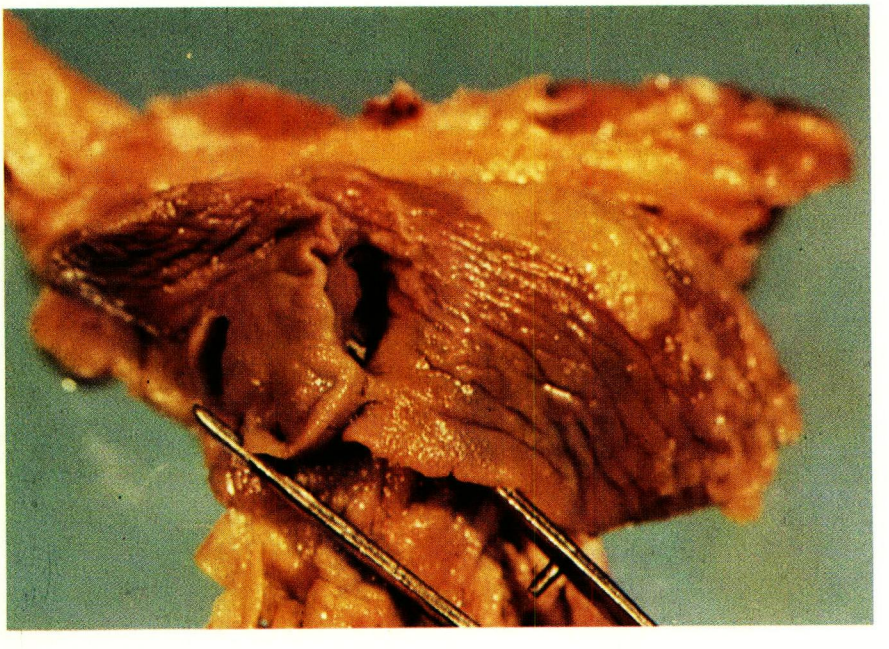



PLATE 312: BRONCHIAL FOREIGN BODY

This 1½ cm. foreign body was taken from a bronchial airway of a cat that died from empyema which resulted from the rupture of a lung abscess caused initially by this fragment of plant. This awn type foreign body was subsequently identified as a terminal twig of an ornamental cedar tree. The spines all going one way make it difficult for an animal to cough this up naturally and also enhances its travels within tissues.

PLATE 313: BRONCHIAL FOREIGN BODY

This piece of plant material can be recognized as not being animal tissue by its internal character and somewhat by its spiny cuticular edge. It may be easily mistaken for a parasite. It is surrounded by purulent debris in an airway with just a small area of epithelium over a few glands. With such "one way" spines on plant materials, they are difficult to remove spontaneously by coughing. Materials of this sort are a common cause of foreign body pneumonia and subsequent empyema in cats and other species.

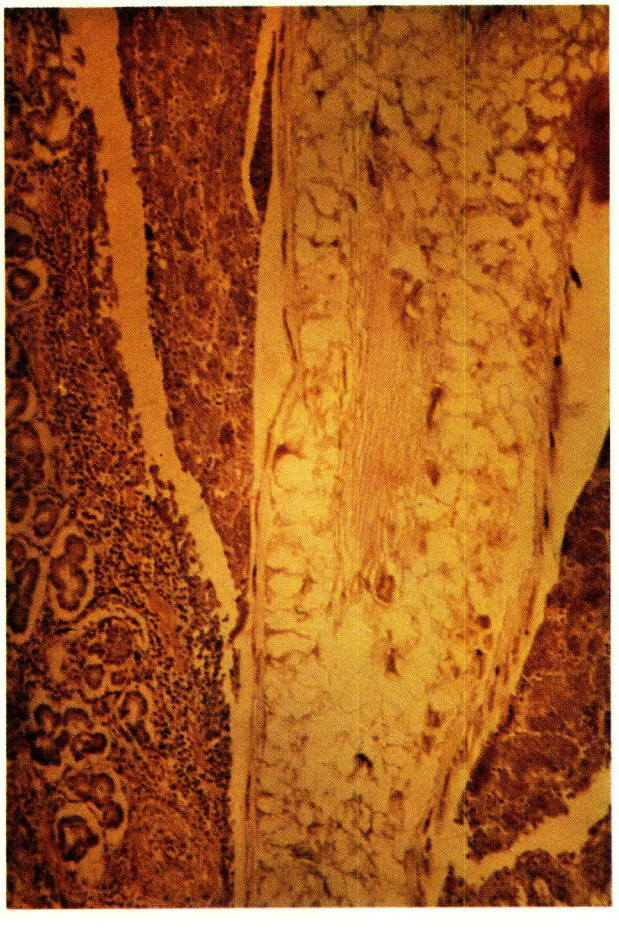

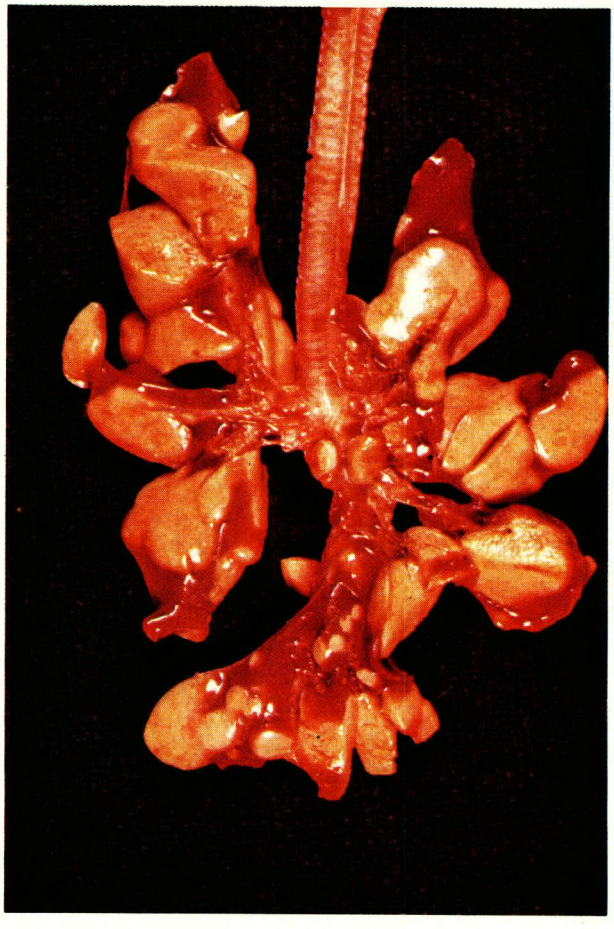

PLATE 314: FOREIGN BODY PNEUMONIA

The multiple foci of locally extensive pneumonia are pale and firm. They consist histologically of large numbers of macrophages and some giant cells containing clear vacuoles. These vacuoles once contained mineral oil which was inhaled by this cat when it was treated orally for hairballs. The mineral oil was removed during slide preparation. The dark red areas are collapsed (post-mortem) normal lung parenchyma.

PLATE 315: LOCALLY EXTENSIVE AV PNEUMONIA

The AV (anterioventral) (cranioventral) lobes are firm with the left lobes more congested than the right. Fibrin strands are present over the affected tissues and also gives this type of pneumonia the name fibrinous pneumonia. While Pasteurella spp. was isolated from these lesions, it could also be considered an example of so called mycoplasma pneumonia or even inhalation pneumonia. Although this was in a pig, the lesion is similar in other species with fibrinous pneumonia.

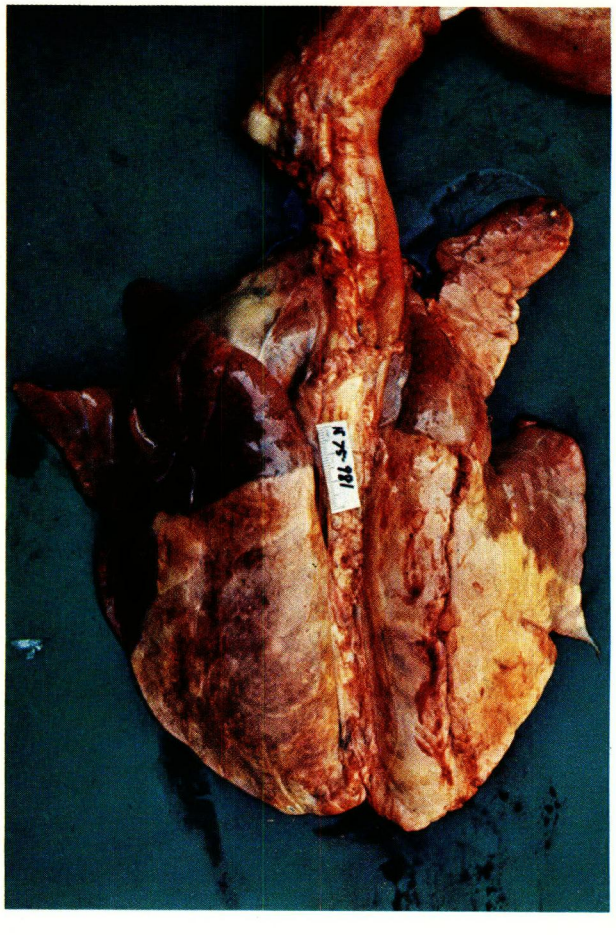

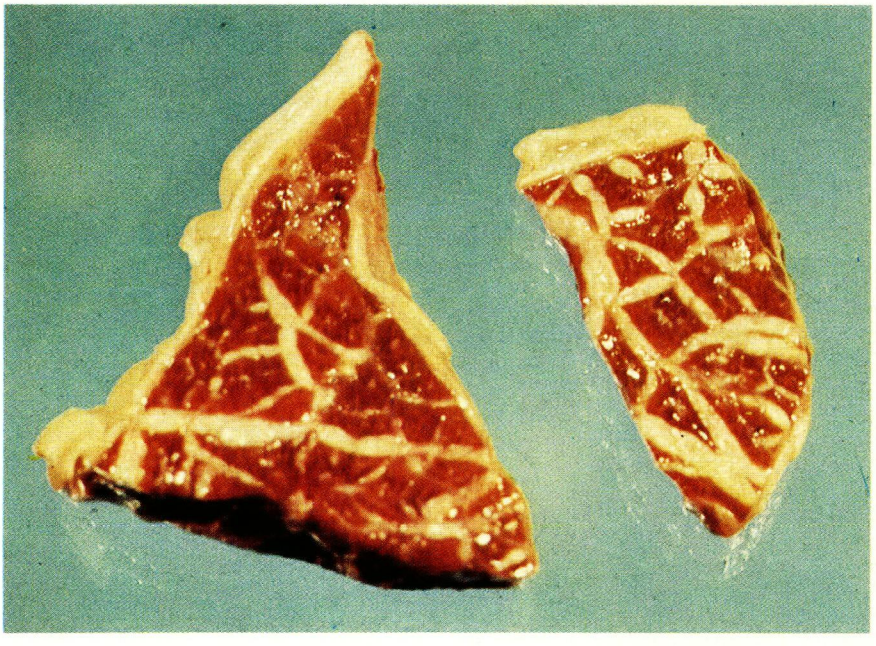

PLATE 316: FIBRINOUS PLEURITIS (MARBLING)

The white tissue is a marked fibrin deposition on the lung surface and between the lobules giving it the appearance of fat between muscles in a fat carcass called marbling. The red tissue is slightly atelectatic but otherwise normal lung. Most cases of this are associated with fibrinous (pasteurella) pneumonia as indeed it was in this bovine case with classical AV fibrinous pneumonia. Pneumonia is not present in the areas shown in the picture.

PLATE 317: FIBRINOUS PNEUMONIA

The surface of this lung shows a distinct dark zone of round cells (mononuclears and neutrophils) and a less dense zone of edema and cellular debris on the surface proper with one large serum pocket and several large clumps of fibrin in its wall. Edema, fibrin and cellular debris are present in the alveoli and the stroma is thickened by congestion. Such a lesion is quite common, and often associated with pasteurella and hemophilus pneumonia.



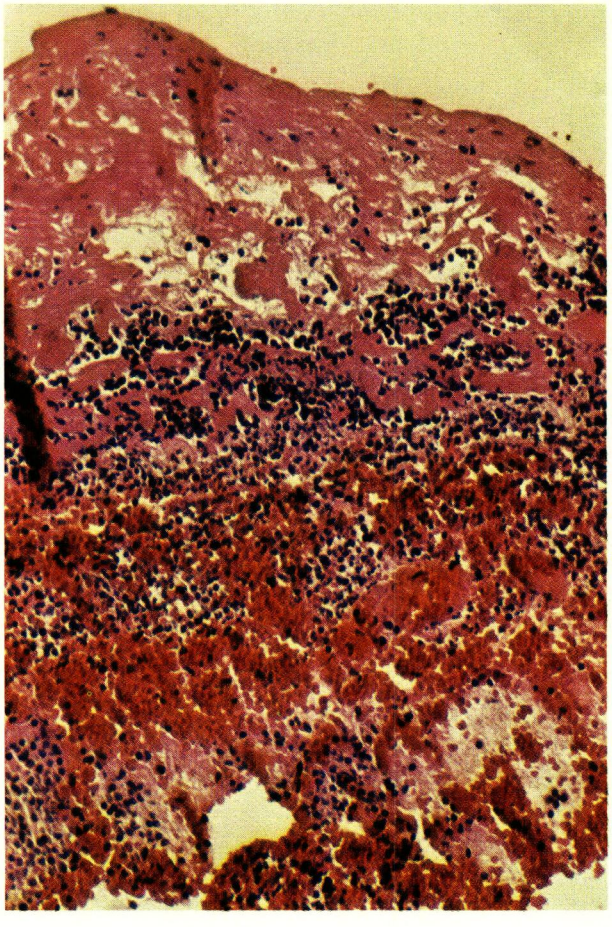

PLATE 318: FIBRINOUS PLEURITIS

The surface debris consists of fibrin and edema with an increase of inflammatory cells, chiefly neutrophils. The underlying lung is congested and has some hemorrhage and neutrophils in the alveoli. This is a case of fibrinous pneumonia (Pasteurella spp.), but this focus itself could just as well be seen in hemophilus pneumonia, inhalation pneumonia or just about any acute necrotic lung lesion near the surface.

PLATE 319: BRONCHOPNEUMONIA

This locally extensive pneumonia is mainly in the AV (anterioventral, cranioventral) lobes which are reddened with congestion, quite firm and delineated along lobular lines suggesting it is a bronchopneumonia. The remaining lung is soft and spongy with emphysema from terminal dyspnea. These pneumonic lesions are not diagnostically significant as many organisms may result in similar lesions in their early stages. This SPF (specific pathogen free) pig was experimentally infected with Bordetella Bronchiseptica organisms.





PLATE 320: RESOLVING BRONCHOPNEUMONIA

This is the chronic resolution stage of a locally extensive pneumonia which could have been a mycoplasma, pasteurella or even inhalation pneumonia. The lack of any acute inflammatory changes as edema, fibrin or hemorrhage and the depressed, firm character similar to all the lesions suggest it is nonprogressive and is probably resolving. The pink parenchyma is terminal emphysema. The right ventricle is enlarged and when opened the wall was noted to be both dilated and slightly thickened from hypertrophy (cor pulmonale). This thickening is the response to the increased work load of pushing blood through the pneumonic lung. It is surprising more hearts are not similarly affected when one considers the number of animal lungs with chronic pneumonia. It is sometimes difficult to differentiate fetal atelectasis from this lesion.

PLATE 321: PURULENT BRONCHOPNEUMONIA

Most of the airways have clumps of purulent (suppurative) debris in them and a rather marked round cell invasion of the bronchial and peribronchial tissues. Scattered purulent foci are in the alveoli. In most areas, but especially about the major airways, the alveoli are slightly to entirely collapsed (atelectasis). Many organisms could cause such a lesion as it is not specific.

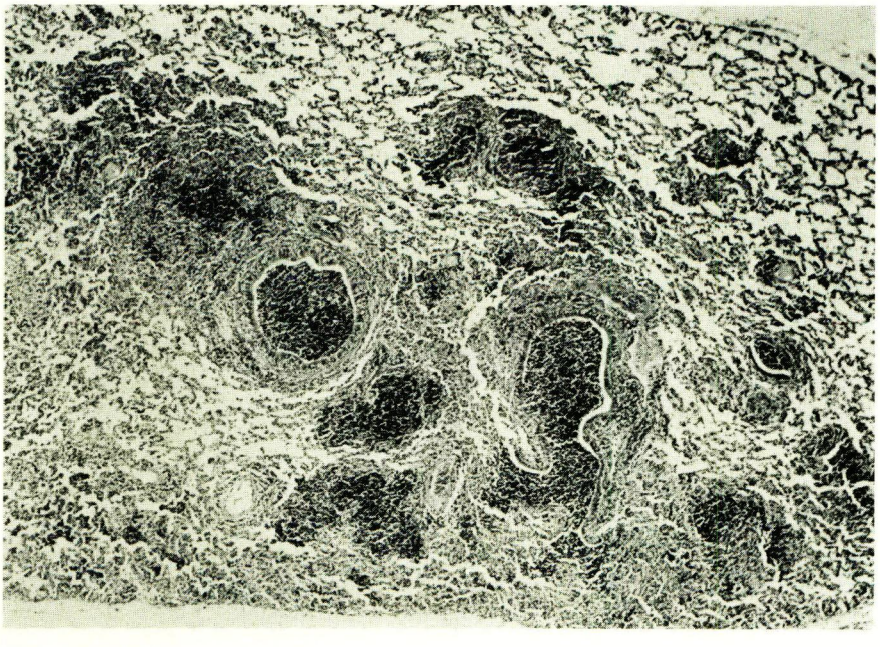



PLATE 322: CHRONIC BRONCHOPNEUMONIA AND EMPHYSEMA

The cranioventral lobes are firm with a few strands of fibrous tissue attached to their lateral surfaces. The remaining three fourths of the left lung is inflated with emphysema except for a crease in the lung tissue above the cardiac lobe. The entire lung is dark red because the animal was not bled out. This should be considered a case of resolving bronchopneumonia as we cannot be sure of its original cause even if we culture it. Pasteurella spp., Mycoplasma spp. or other organisms may be isolated at this stage, but may not have been the causative agents.

PLATE 323: MYCOPLASMA PNEUMONIA (SWINE ENZOOTIC PNEUMONIA, SEP)

The reddish areas of the cranioventral lobes are firm and congested. Several pink areas are scattered among these affected lobes and may represent unaffected lobes or surface emphysema over pneumonic areas. The bulging appearance of the remaining lung is from failure of normal collapse as terminal edema developed and was mixed to a froth with air. This prevented the normal collapse that occurs via elastic recoil action with death. This locally extensive pneumonia was at one time considered to be caused by a virus. There are others who consider that mycoplasma may not be the final answer to this problem.





PLATE 324: MYCOPLASMA PNEUMONIA (SWINE ENZOOTIC PNEUMONIA, SEP)

This locally extensive, anterior ventral pneumonia is greyish and firm and is in the stage of grey hepatization with a massive infiltration of white blood cells histologically. The diaphragmatic lobes are for the most part normal. The junctional zone between the grey affected lobes and the more normal lung is dark and homogeneous and is firm like the anterior (cranial) lobes. These junctional areas are examples of mixed red and grey hepatization. One area of grey hepatization is present in the left ventral diaphragmatic lobe.

PLATE 325: LYMPHOID FOLLICLE GENERATION (LYMPHOID HYPERPLASIA)

There are numerous chronic inflammatory cells scattered about this bronchiole. Three large lymphoid follicles and one smaller one are developing near the bronchiole. Slight epithelization (alveolar lining cell proliferation) of several alveoli is apparent. While a common and helpful diagnostic feature of mycoplasma pneumonia in swine, it is also commonly seen in chronic murine pneumonia in rats, Marsh's progressive pneumonia in sheep and other chronic pneumonias in animals.

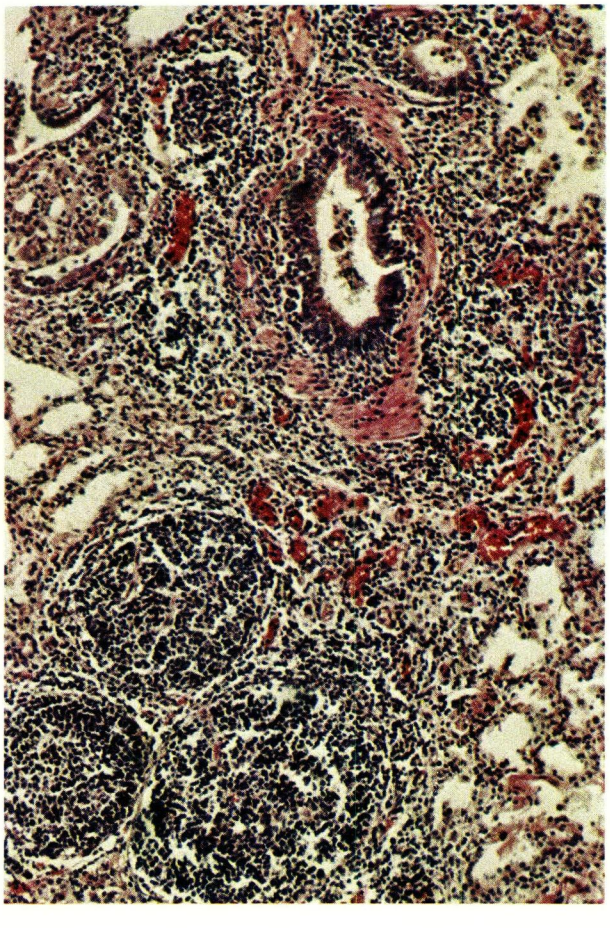

PLATE 326: CHRONIC ABSCESSED PNEUMONIA

The ventral portion of the left cardiac lobe shows a large chalky white mass of pus, well encapsulated by thick pleura and collapsed lung parenchyma. Another similar area is seen along the cranioventral portion of the left apical lobe. Several firm areas of chronic pneumonia could also be palpated scattered in the left lung especially under the fibrous adhesions seen on the central surface area of the diaphragmatic lobe. While C. pyogenes was isolated, it is thought this could be the chronic sequelae of several types of cranioventral pneumonia, most likely from inhalation pneumonia.

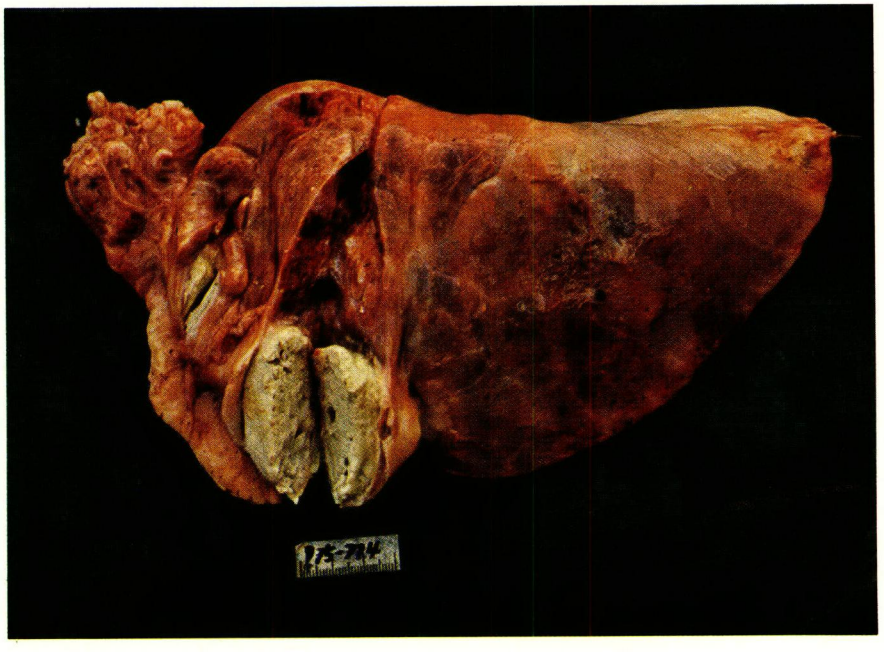

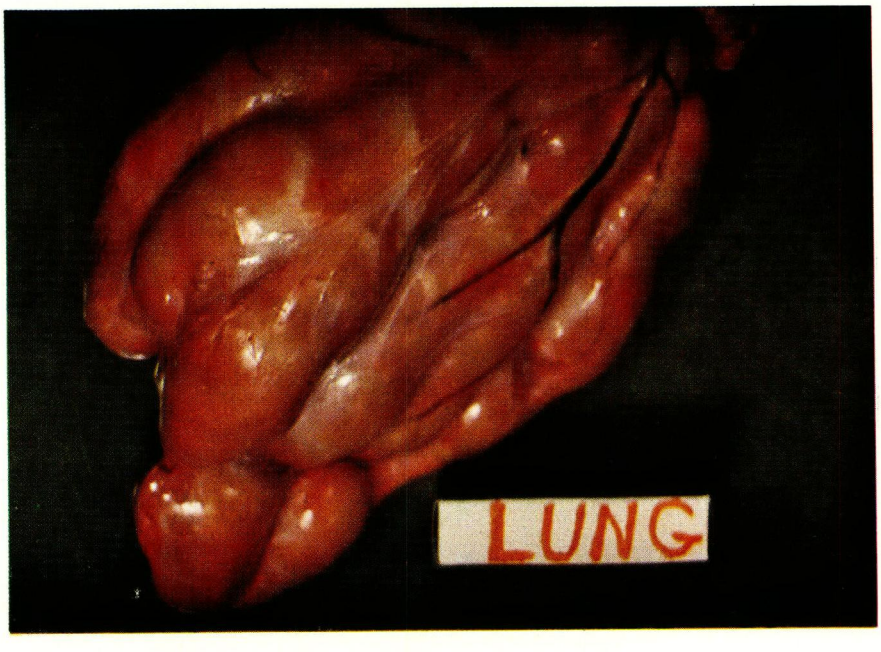

PLATE 327: BRONCHIECTASIS

This picture represents the tip of one lung lobe. Its swollen, round pocketed nature is due to all or most all of the airways in the section being dilated and filled with purulent debris (purulent bronchiectasis). This is the probable sequelae of a chronic bronchopneumonia with purulent debris in the airways weakening the walls which then dilated. The alveoli for the most part, are collapsed and nonfunctional. A congenital form may be seen in man and some animals, but most are secondary.

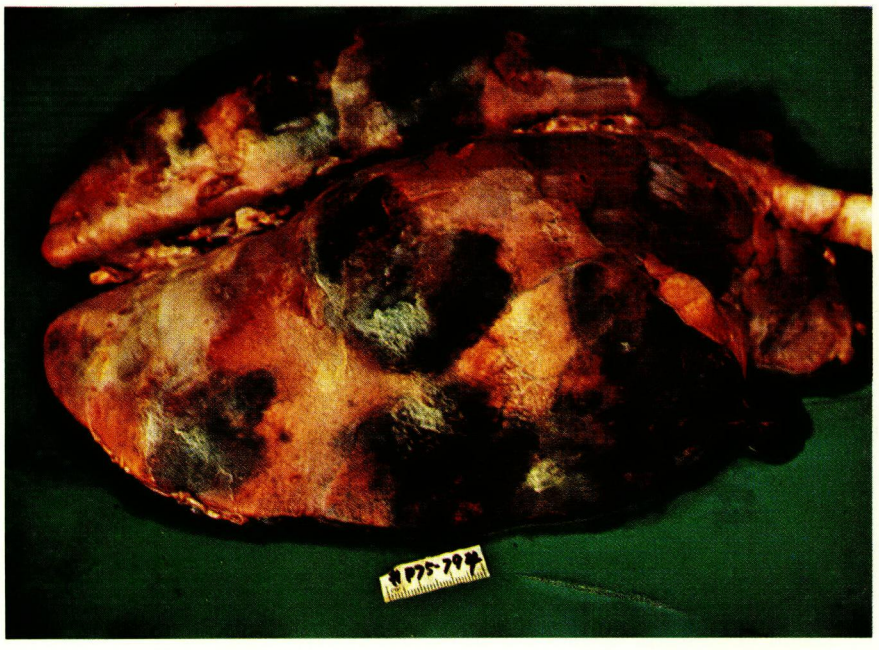

PLATE 328: HEMOPHILUS PNEUMONIA

This natural case in a pig of a locally extensive pneumonia is characteristic of Hemophilus parahemolyticus pneumonia showing its hemorrhagic, fibrinous, scattered pattern. Its hemorrhagic nature and scattered location differentiates it from the majority of other pneumonias including Pasteurella spp. pneumonia which is also fibrinous. Fluid and fibrin strands in the pleural, pericardial and peritoneal cavities are often seen in these cases. In some cases only a single hemorrhagic lesion may be found.

PLATE 329: HEMOPHILUS PNEUMONIA

This fibrinous, hemorrhagic, locally extensive pneumonia involves most of the left diaphragmatic lobe, 80% of the left apical and cardiac lobes under a large sheet of fibrin, and the cranial 50% of the right lung of this pig. Some emphysema of the right cardiac lobe with a hemorrhagic pneumonia is seen. Scattered sheets of fibrin are on various lobes. The anterior dorsal left diaphragmatic lobe shows a marked interlobular edema separating the lobules, which are otherwise normal. While this was an experimentally caused infection, the natural cases are often similar.

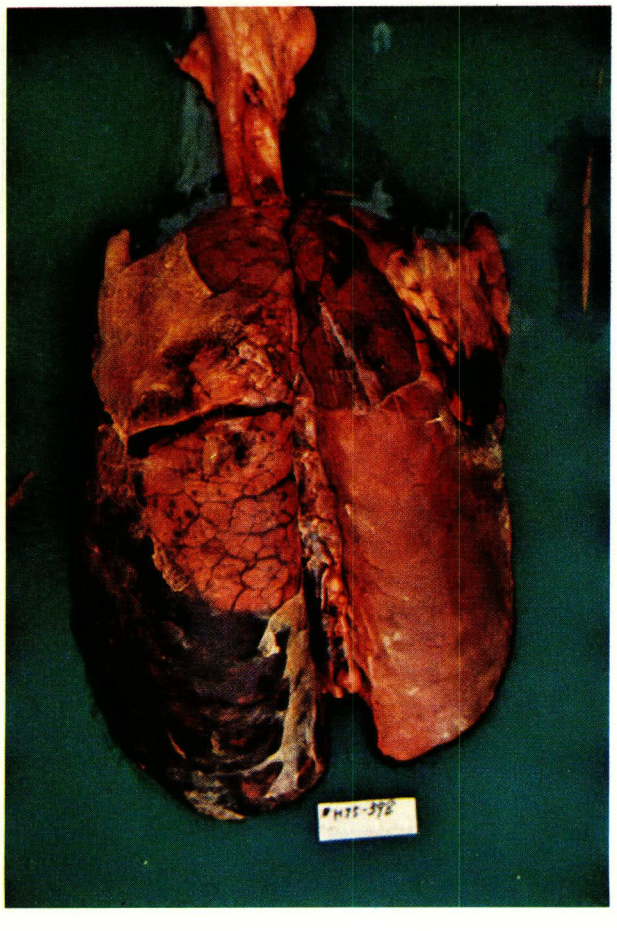



PLATE 330: HEMOPHILUS PNEUMONIA

This almost square discrete area of dark red lung is firm and slightly elevated above the surrounding tissue. The dark red color is characteristic of the hemorrhagic nature of Hemophilus parahemolyticus pneumonia. The remaining lung tissue is red as the pig was not bled out, but it is not firm so it is not pneumonic.

PLATE 331: SUBACUTE HEMOPHILUS PNEUMONIA

The portion of lung with the irregular, thin fissure extending in from the surface is firm and friable. This necrotic area is fairly well outlined by a slightly raised border of fibrin and debris. The opposite portion of this slice of lung is congested but otherwise normal. The irregular, circumscribed, individual lesions in the affected area are foci of necrotizing pneumonia which has helped decrease the tensile strength of the normal tissue allowing it to "tear" as it did. The more reddish tissue within the large area of affected lung and around the individual necrotic foci are pneumonic areas of lung without necrosis.



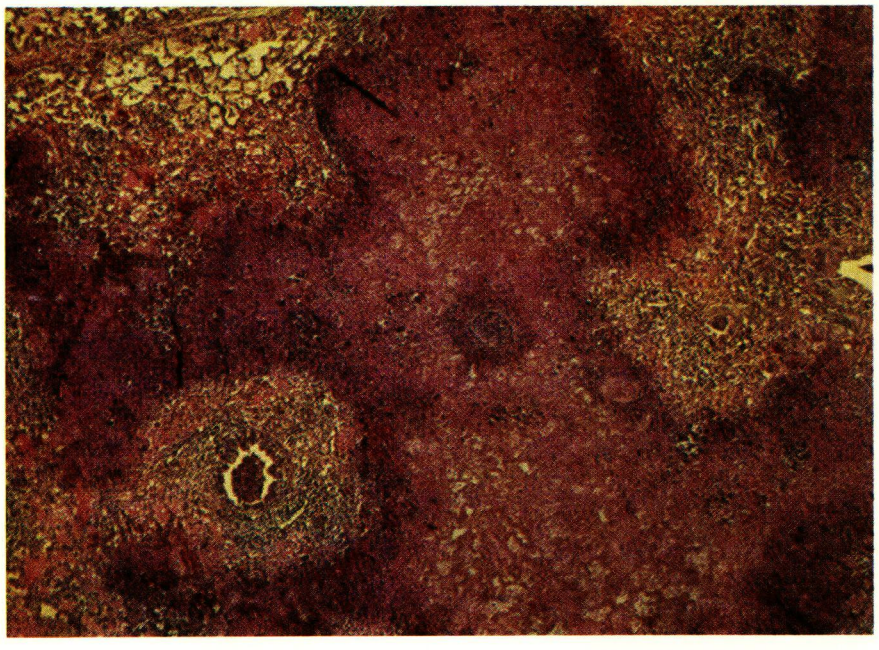

PLATE 332: NECROTIZING BRONCHOPNEUMONIA

The large, pale, irregular, homogeneous area of lung is mostly necrotic lung tissue with an inflammatory cell border. Purulent debris is in the airways and many inflammatory cells are in the adjacent alveoli. Hemophilus parahemolyticus was isolated from this pig's lung, but other agents cause similar lesions.

PLATE 333: BRONCHOPNEUMONIA

The severe inflammatory reaction present is concentrated about the major airway in this section and the associated vessels are congested (hyperemic). This suggests that the process probably originated at or near the bronchiole making it bronchiogenic in origin and not hematogenous. This relationship is not always a hard and fast rule.

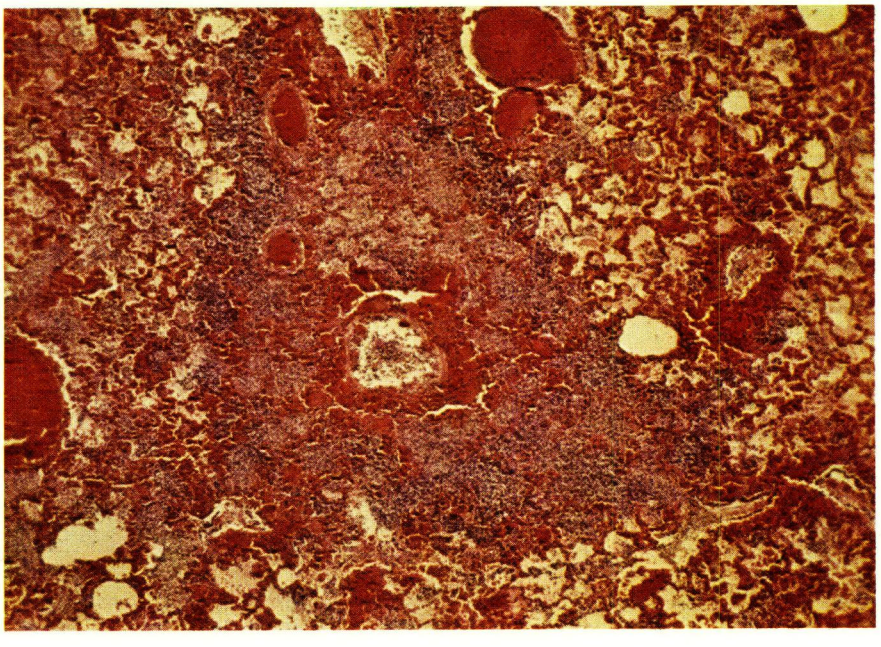

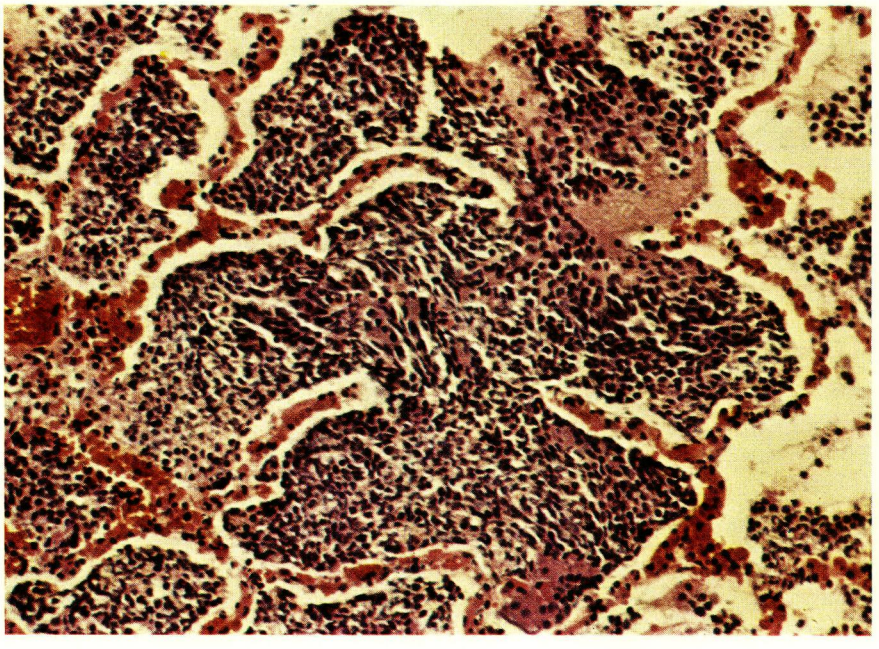

PLATE 334: HEMOPHILUS PNEUMONIA

These mononuclear cells, many of which have a spindle shape, are lined up into a swarming, whorled mass in these alveoli. This is a characteristic finding in Hemophilus parahemolyticus pneumonia in pigs.

PLATE 335: ACUTE PNEUMONIA AND VENOUS THROMBOSIS

The thin walled vein has an acute fibrin thrombus attached to one side and slight endothelial thickening around the rest of the vessel. Scattered inflammatory cells and edema surround the vessel's periphery. Large masses of inflammatory cells are present in adjacent alveoli. Hemophilus spp. was isolated.

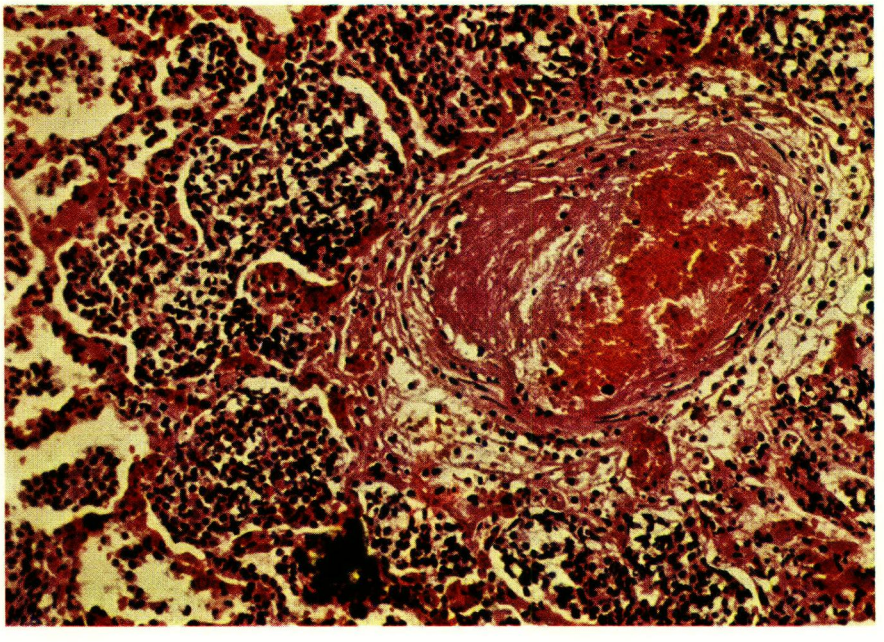

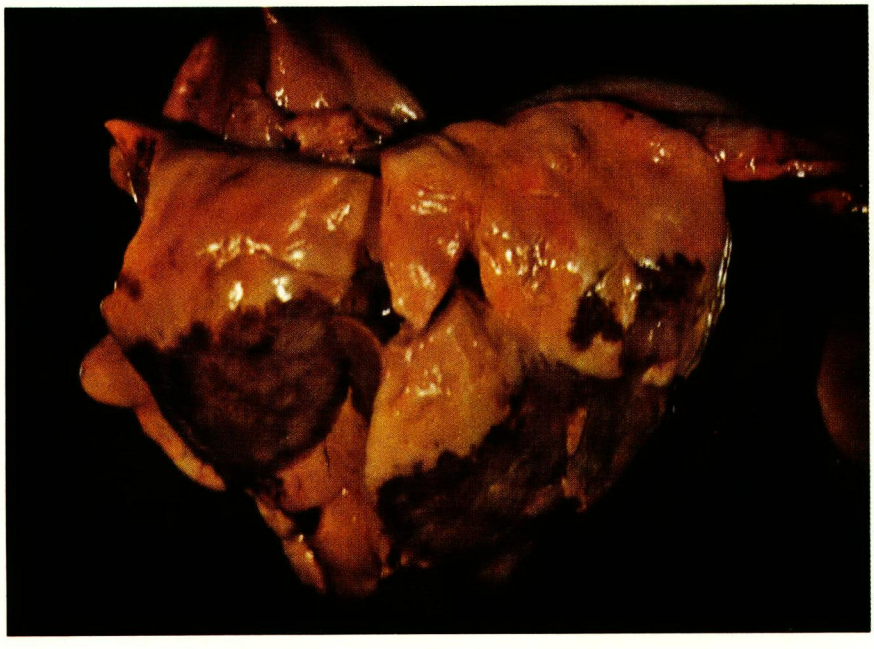

PLATE 336: CANINE DISTEMPER

The well defined ventral areas of dark lung are locally extensive areas of bacterial pneumonia superimposed on the viral pneumonia of canine distemper. Many areas of necrosis with neutrophils are present in these areas of bronchopneumonia histologically. Both intranuclear and incytoplasmic inclusions may be found in airway epithelium and even in large monocytes and giant cells if present. This is the most common form of distemper pneumonia, but a giant cell, adenomatoid and interstitial form are sometimes seen. When toxoplasmosis is associated with distemper, it usually causes a diffuse type of pneumonia with tiny white foci of necrosis. At one time when distemper was more prevalent, it was quite easy to say that any pneumonia in a dog was due to distemper until proven otherwise.

PLATE 337: SWINE INFLUENZA

Most cases of this viral disease are not fatal so one often does not get the chance to see this locally extensive type of pneumonia. Only a small amount of mucus can be expressed from the airways of these slightly firm pneumonic foci.





PLATE 338: PROLIFERATIVE PNEUMONIA

The lungs shown here are diffusely involved, heavy, wet and firmer than normal. Much emphysema is seen throughout the lung as a result of dyspnea. The pneumonic process is in all the lobes in this cow, but if part of the lung was still involved with a previous lung lesion, than this present disease may not necessarily affect that area. The whole lung is involved in most cases of this disease, but every lobule may not be. The meaty consistency of the lung is due to the proliferation of the alveolar lining cells (adenomatoid reaction). Hyaline membrane formation is also seen in acute cases, and more chronic cases may show smooth muscle hypertrophy and bronchiolitis obliterans fibrosa. The adenomatoid reaction is to be differentiated from adenomatosis which is a specific disease of sheep. High levels of atropine are suggested for treatment of these cases. The cause of this disease is not fully understood, but the higher oxides of nitrogen are probably involved as is the fact that ruminants inhale up to 80% of their rumen gas.

PLATE 339: ALVEOLAR LINING CELL PROLIFERATION AND HYALINE MEMBRANE PROLIFERATION

The pink, fibrin like membrane (hyaline membrane) lining the alveoli and some terminal airways is an abnormal protein condensate the exact source and nature of which is not known. Several alveoli have a partial lining of cuboidal cells (proliferation of alveolar lining cells). These two changes of hyaline membrane formation and alveolar lining cell proliferation are the basic early lesions seen in cases of proliferative pneumonia (atypical interstitial pneumonia) of cattle, goats, foals and swine. The cause of this entire group of related diseases including bronchiolitis obliterans in cattle is not understood. One should recognize that ruminants inhale up to 80% of their rumen produced gas volume, and it is possible that the oxides of nitrogen produced there may be involved. This would not be the case in the simple stomached animals.

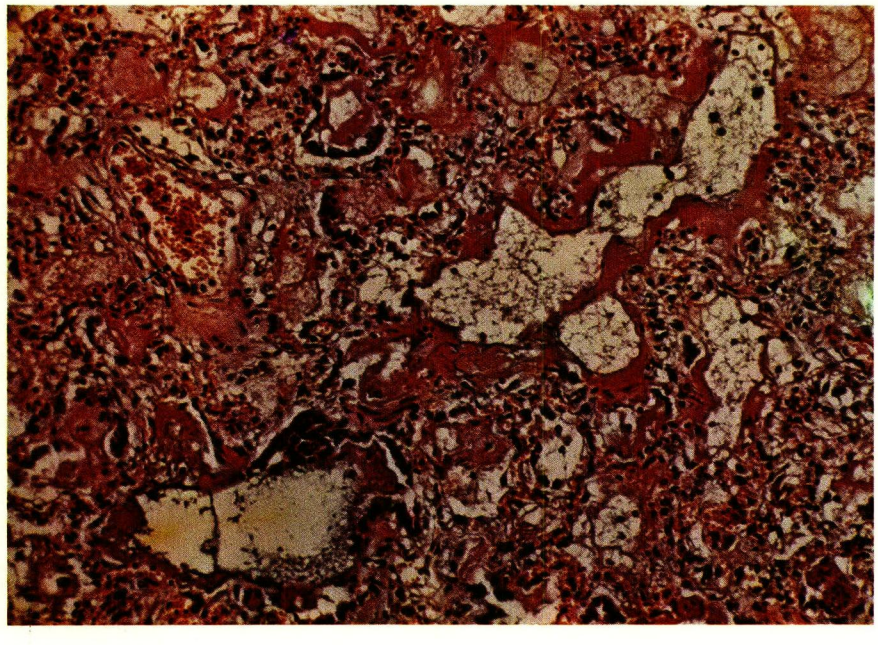

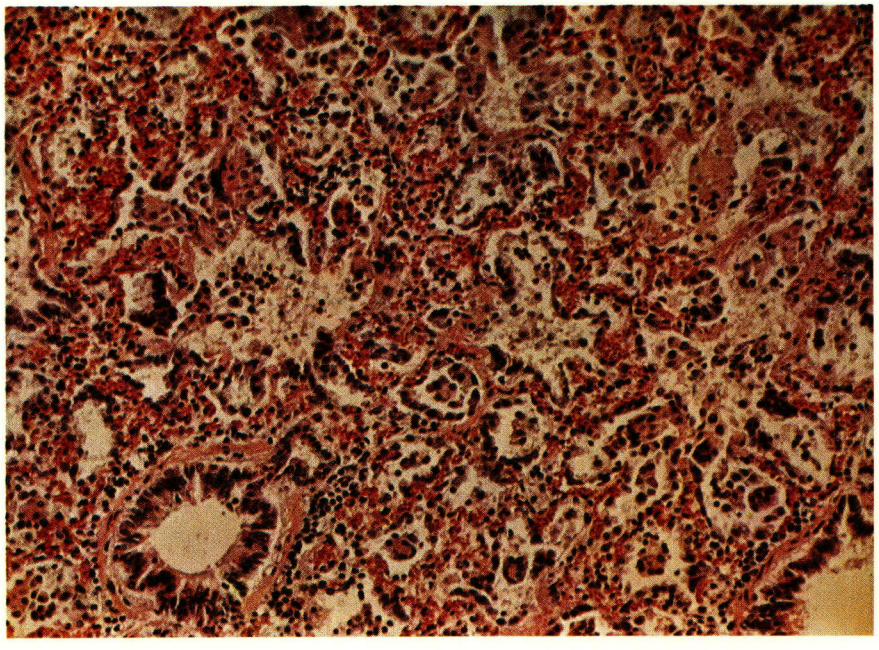

PLATE 340: ADENOMATOID REACTION (FETALIZATION)

This section of lung shows many alveoli lined by cuboidal cells which are the result of an alveolar lining cell proliferation. The two bronchioles are recognized by their thin layer of smooth muscle cells around them. A few sloughed alveolar lining cells are mixed with a few inflammatory cells in the alveoli. This lesion is characteristic of several viral diseases of sheep. It is seen as one form of pneumonia in dogs with canine distemper. It is also seen adjacent to a variety of lesions in the lung in many species. In the above three categories, this adenomatoid reaction is focal or multifocal in distribution. When seen in cattle as a diffuse lesion, it is usually diagnostic of proliferative pneumonia (atypical interstitial pneumonia). This is an acute disease probably caused by inhalation of the higher oxides of nitrogen from the rumen and remarkably responsive therapeutically to atropine in high doses.

PLATE 341: BRONCHIOLITIS OBLITERANS (BO)

This was a diffuse lung lesion. The lung was enlarged, spongy and light in weight. This section came from a cow that was bled out and shows the above characteristics plus the many tiny, grey, shiny foci in each lobule. These grey foci are areas of bronchiolitis obliterans fibrosa which give the disease its name. This is a chronic disease in adult, housed cattle. It usually occurs in late winter or spring. Its cause is not known, although rumen production and subsequent inhalation of the higher oxides of nitrogen may be a factor. There is a high morbidity and low mortality in this disease. The corticosteroids, to prevent fibroplasia, are indicated in therapy. A similar disease in man, "silo filler's disease", is caused by the brown gas at the bottom of a newly filled silo and is successfully treated with corticosteroids.

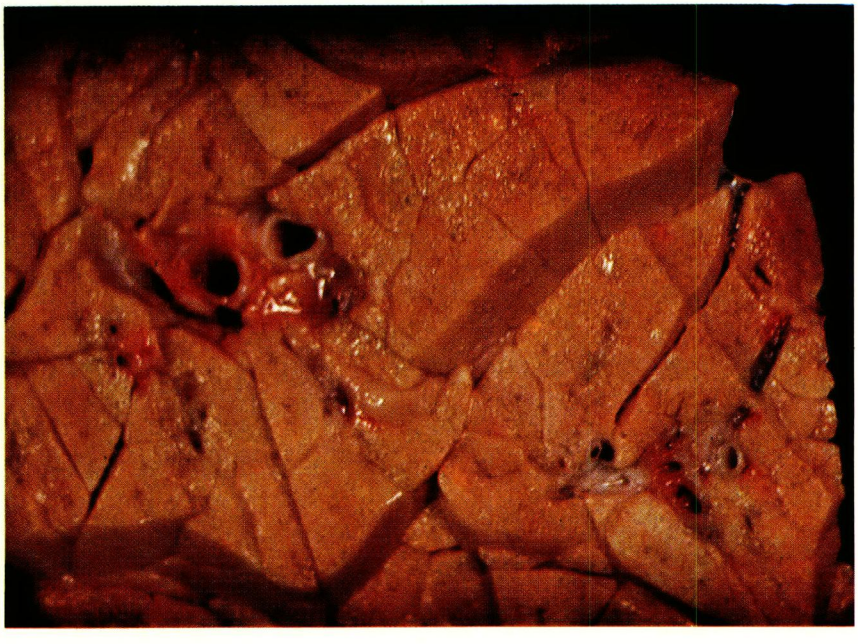

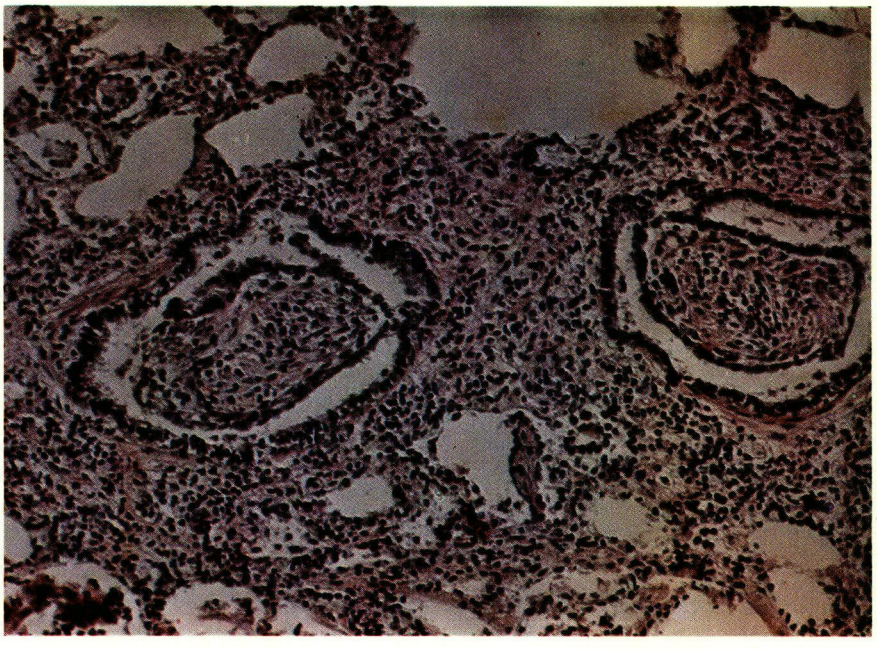

PLATE 342: BRONCHIOLITIS OBLITERANS FIBROSA

This lesion is characterized by polyp like ingrowths of connective tissue into the two bronchioles. The polyps are partially covered by proliferating bronchiolar epithelium. Both the polyps and the peribronchiolar areas have a moderate number of chronic inflammatory cells, mostly plasma cells, mixed with the proliferating connective tissue. Several of the alveoli in the area have a glandlike appearance from the proliferation of alveolar lining cells (adenomatoid reaction). This lesion of bronchiolitis obliterans fibrosa may be found in conjunction with many chronic bronchiolar lesions such as parasitic lesions, foreign body pneumonia and chronic bronchopneumonia as a nonspecific lesion. However, if it is the major microscopic lesion in cattle with a diffuse lung lesion grossly, it is quite specific for the disease entity bronchiolitis obliterans.

PLATE 343: TOXOPLASMOSIS

This is an example of a diffuse pneumonia in a pig. The entire lung is uniformly involved, firmer than normal and has many tiny white foci of necrosis and organism proliferation scattered throughout. Impression smears of the lungs may often show the tiny, curved, cigar shaped organisms. The bronchial lymph nodes and hepatic lymph nodes are often characteristically moist and swollen. A few cases have focal necrosis in the liver. Histologically, focal necrosis may be seen in any tissue or organ.

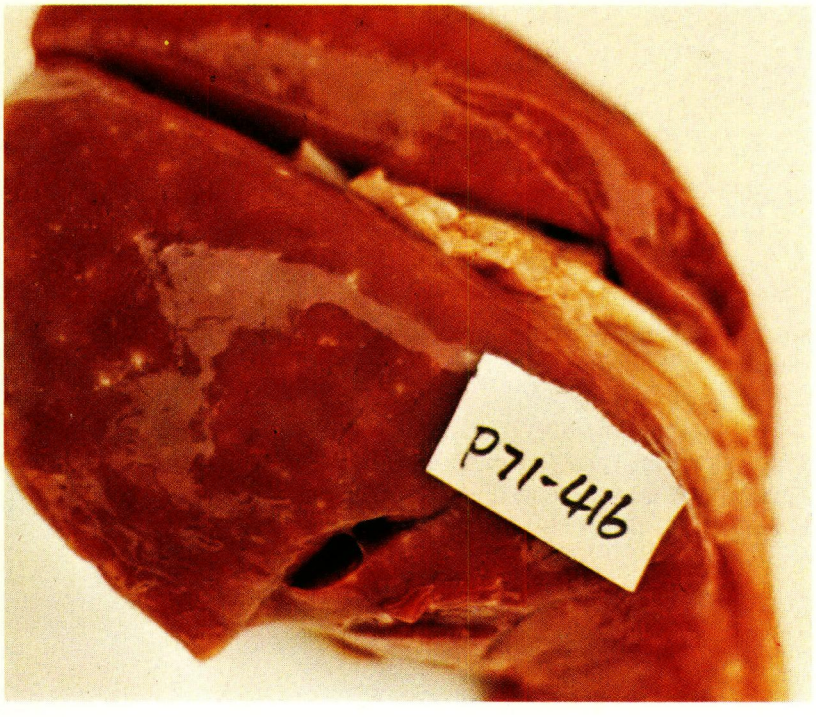

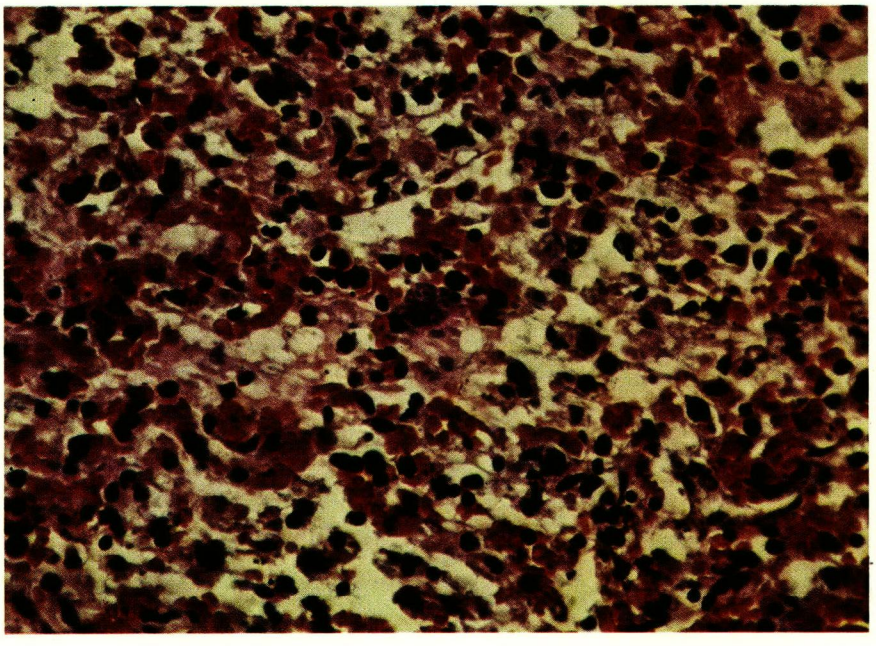

PLATE 344: TOXOPLASMA GONDII PSEUDOCYST

In the center, a single macrophage is present containing several Toxoplasma gondii organisms. The surrounding tissue is congested as most, if not all, of the red blood cells are still in vessels. A mixture of inflammatory cells is present. Grossly, the lesion was a diffuse pneumonia. In many animal species, toxoplasmosis is often seen in connection with a severe viral disease as canine distemper in the dog. For this reason, some people believe toxoplasmosis may be a common latent disease that is made clinically evident by a severe stress reaction.

PLATE 345: TOXOPLASMA GONDII

This Giemsa stained smear of affected tissue shows the nucleus of a macrophage and nine individual toxoplasma organisms with their slightly curved, cigar shaped bodies and single nucleus. The lung and affected lymph nodes are the best tissues from which to make a smear in order to demonstrate these protozoan organisms. In making this or any tissue smear, except for blood cell morphology, the technique is to press the slide onto the tissue or vice versa in a direct up and down fashion without any sideway movement.

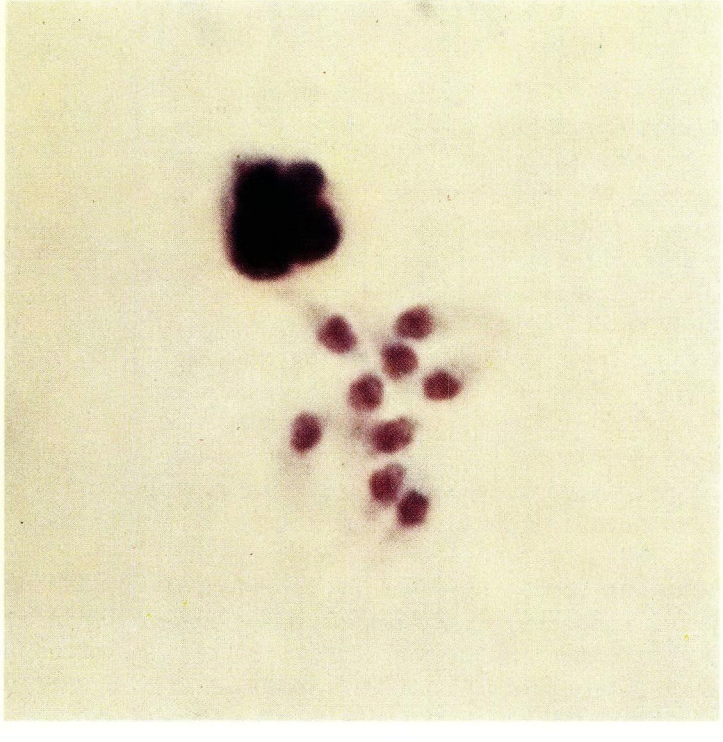

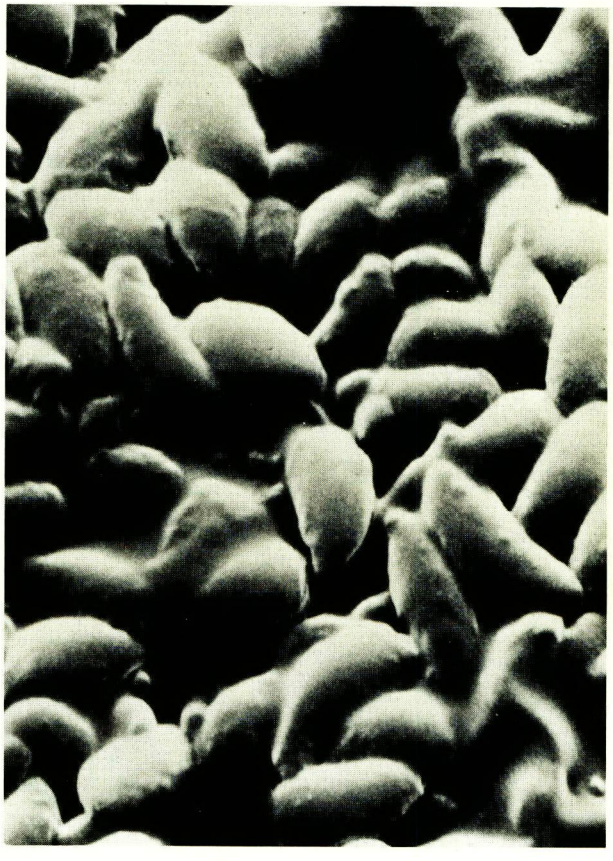

PLATE 346: TOXOPLASMA GONDII

This is a scanning electron microscope picture taken at about 6250 x magnification of organisms collected from the peritoneal cavity fluid of an experimentally infected mouse. The slightly curved, fat cigar shaped organisms are Toxoplasma gondii.

PLATE 347: MULTIFOCAL PARASITIC PNEUMONIA

Scattered 3-10 mm., slightly raised, greenish, firm nodules are seen here and were scattered throughout this cow's lung. One should consider wandering parasites or multible abscesses that were embolic from a vegetative endocarditis or ruptured liver abscess. The green color suggests pus or an eosinophil accumulation as associated with an allergic problem. Histologically, these nodules were masses of eosinophils and other cellular debris about sections of parasites. Grossly, there were numerous lungworms, Dictyocaulus viviparous, in the bronchi. This was diagnosed as "post fogging pneumonia" because many animals in the herd came down with moderate to severe respiratory signs after they were "fogged" inadvertently while the barn was being treated for fly control. The pathogenesis suggested is that the migrating lungworm parasites were killed in situ as a result of the fogging and the eosinophilic response developed subsequently.



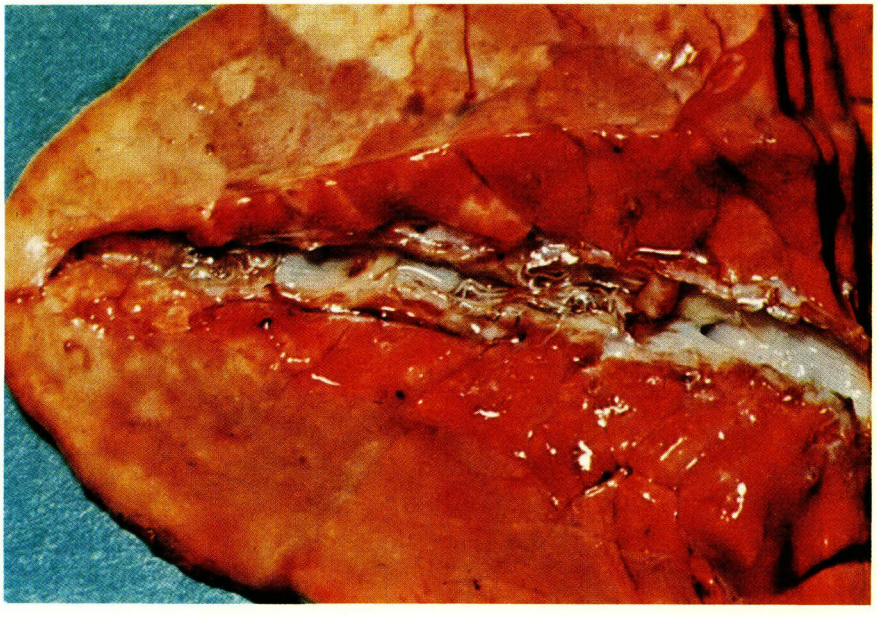

PLATE 348: LUNGWORMS

The cut, open main bronchus of this pig's lung shows several clumps of white worms mixed with a little mucus. These are the common lungworm of the pig, Metastrongylus spp.. Many of these may be present without the animal showing clinical signs or much in the way of lesions at necropsy.

PLATE 349: PARASITIC BRONCHITIS

The airway has been opened to show several lungworms easily recognized in the mucus by their darker internal structure. These are Metastrongylus spp. in a pig. In most domestic animals, lungworms such as Dictyocaulus spp., Protostrongylus spp. and Metastrongylus spp. are to be found in the dorsal diaphragmatic airways. The pneumonia caused by them can be considered almost a "pneumonic infarct" in that the worms and their engendered debris block the airways which cease to function properly. These cause swollen, firm lobules along the free edge or dorsal surface of the diaphragmatic lobes. In contradistinction to this distribution, other lung lesions caused by parasites such as Muellarius spp. living in the parenchyma are more diffusely scattered. They cause focal pneumonia, but they do not make the "pneumonic infarct" type lesion. In many cases, only a bronchitis results without any pneumonia even with large numbers of parasites in the airways. While most airway lungworms are in the diaphragmatic airways, they may be found in other locations quite specific for the organism.

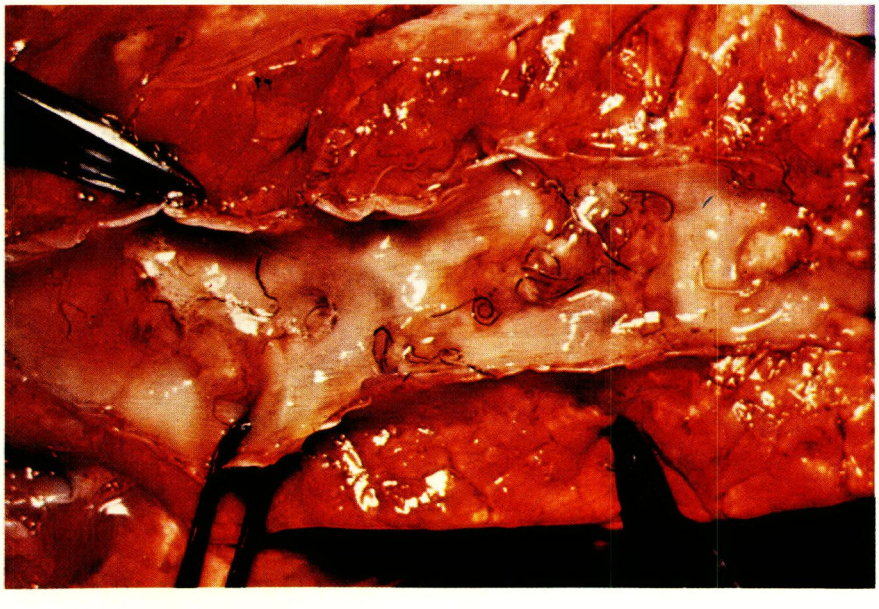

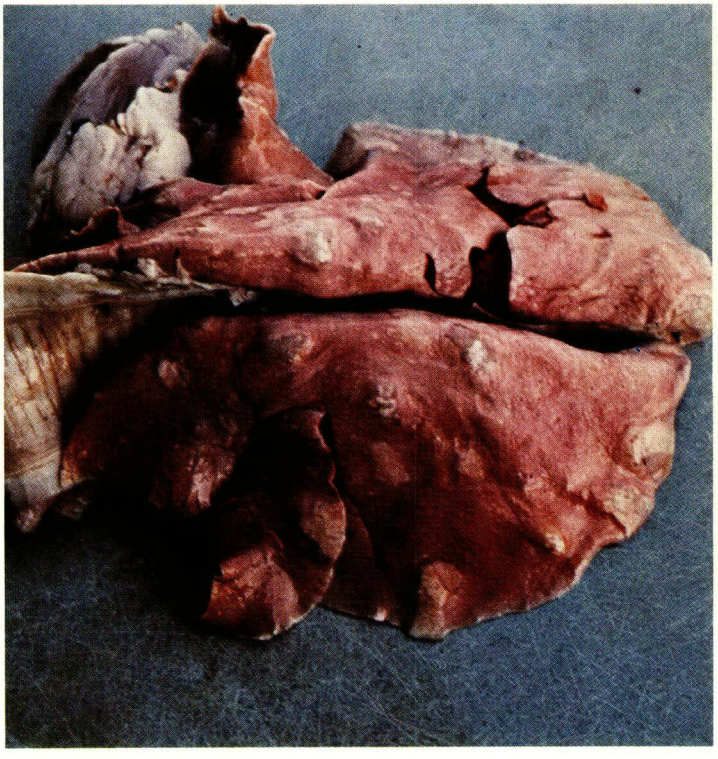

PLATE 350: VERMINOUS PNEUMONIA

This multifocal pneumonia is characterized by the pale, firm, relatively discrete foci scattered throughout the lungs. Several are along the free edge of the diaphragmatic lobes. The grey portions of these lesions are areas of white cell invasion, grey hepatization, and the more white areas are emphysematous. Their size and distribution in this sheep suggests they were probably caused by one of the airway lungworms, Protostrongylus rufescens, which indeed they were. The lesions, especially those along the free border of the diaphragmatic lobe, could have been caused by Dictyocaulus spp. in most species or Metastrongylus spp. in swine.

PLATE 351: PARASITIC BRONCHITIS

Cross sections of three parasites are present in this bronchus and numerous chronic inflammatory cells are present in the peribronchial tissues. Identification of entire (whole) parasites is much more exact and easier than by histological means. In some cases, eosinophils make up some or even the majority of the inflammatory cell population.

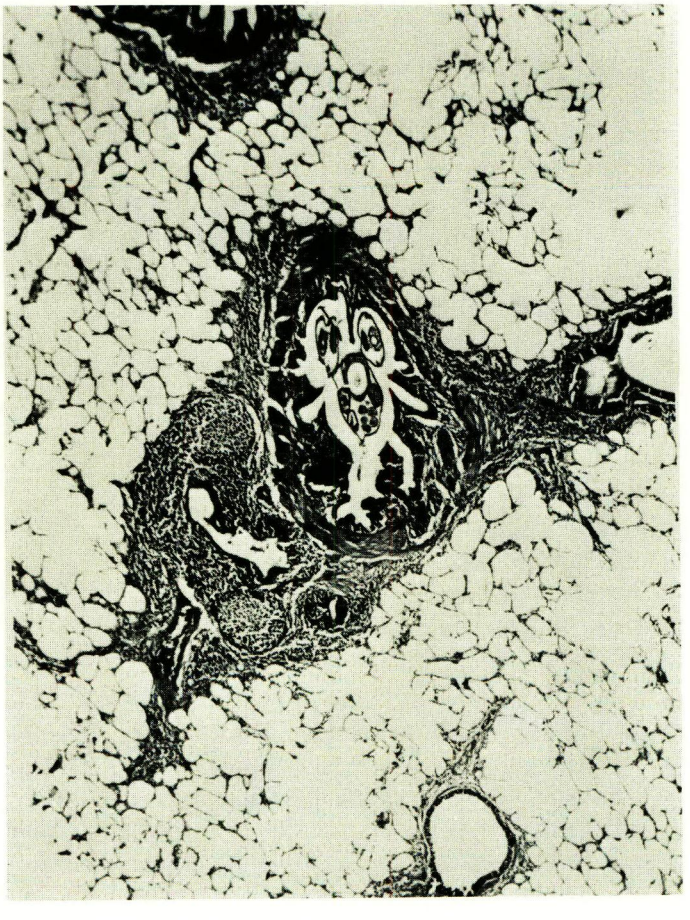

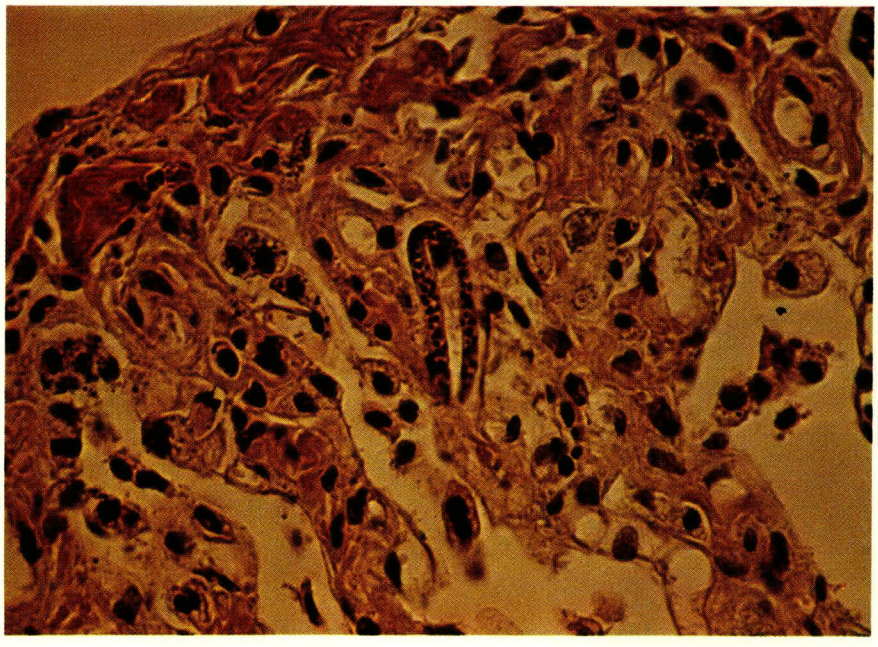

PLATE 352: MICROFILARIA

This lung section shows a capillary with a curved segment of an immature parasite, probably a microfilaria as suggested by its size. Scattered brownish yellow phagocytized pigment is in macrophages. Several microfilarial species can be suspected depending on the host species being examined. Onchocerca spp. and Setaria spp. in the horse; Setaria spp. in the cow; Dipetalonema spp. and Dirofilaria spp. in the dog are some that can be considered. As this is from a dog, one should suspect the latter two parasites first. They are difficult to identify in tissue sections.

PLATE 353: SCLEROSING VERSUS NONSCLEROSING TUMORS

The tumor masses seen in these lungs are both malignant tumors having metastasized to the lungs from their primary site elsewhere in the body. The brown, partially fixed dog's lung has multiple metastatic foci of a bile duct carcinoma. These have formed discrete tumor nodules (nonsclerosing) wherever they have proliferated. The pink, unfixed cow's lung shows a single focus of uterine adenocarcinoma. The pale, radiating grey white tissue (stroma) of the lung has been stimulated (sclerosing) by the presence of the tumor cells. Some tumors show these properties locally as well as in their metastatic foci.



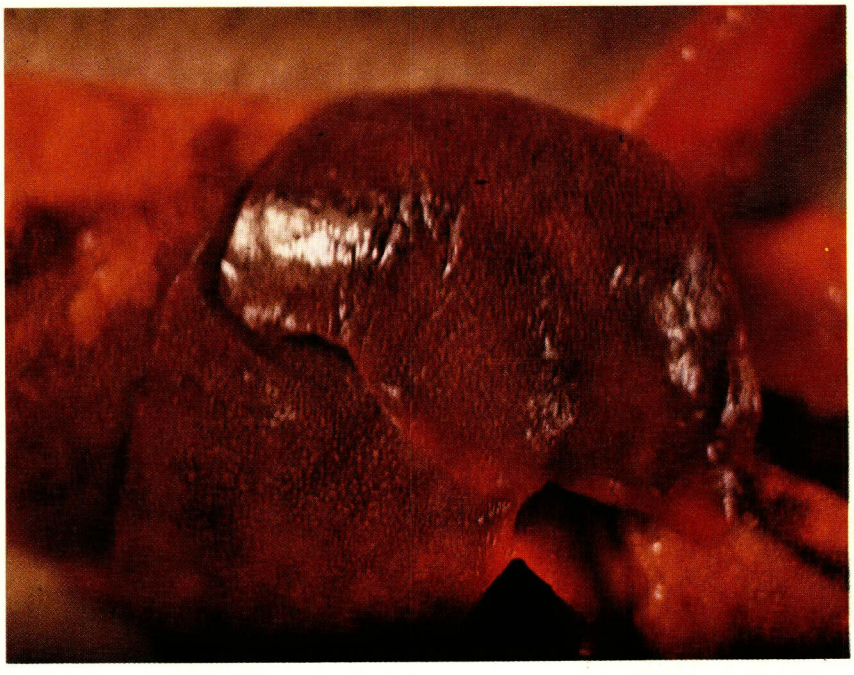

PLATE 354: ENDOGENOUS LIPID PNEUMONIA

The anterior, ventral lobes of this rabbit's lungs are firm, reddish brown with many tiny pale foci. When placed on absorbent paper for photography, the pneumonic areas left an oil stain on the paper. Histologically, massive numbers of macrophages filled with fat vacuoles and cholesterol (cholesterol clefts) make up the predominant reaction in the alveoli and stroma. These experimental rabbits were being fed a 4% cholesterol diet. After about 6 mo. on trial, they were attacked in their hutches by a group of dogs that killed some but only "frightened" others they could not reach. These latter animals died with this endogenous lipid pneumonia several days after the attack from the "stress caused" precipitation of endogenous lipids. The "stress" apparently allowed the lipid level to reach the threshold at which the lipid precipitated out. It was once accepted that fat emboli were mainly the result of trauma to fat depots or bone fractures, but recently the above explanation is considered more likely in the nontraumatic cases of fat embolism. One is forced to think from this about its role in human cardiovascular disease especially atherosclerosis.



PLATE 355: HYDROPERICARDIUM

This partially opened heart sac shows a clear fluid with a watery gelatinous appearance. A slight amount of clear fluid in the heart sac is normal, but excess fluid may be seen in heart failure, hypoproteinemias, passive congestion caused by some pneumonias and in several diseases as polyserositis and porcine stress syndrome (PSS). In a fresh necropsy, the material may be completely fluid when the cavity is first opened, but on exposure to air, even if it is just a transudate, it may gel to form the fibrin clumps.

PLATE 356: CARDIAC TAMPONADE

The partially opened heart sac shows a large mass of clotted blood, cardiac tamponade. Blunt trauma, needle punctures, rib fractures and even some infections of the heart sac may all result in this lesion. If enough blood is present, it may interfere with chamber filling and cause death.

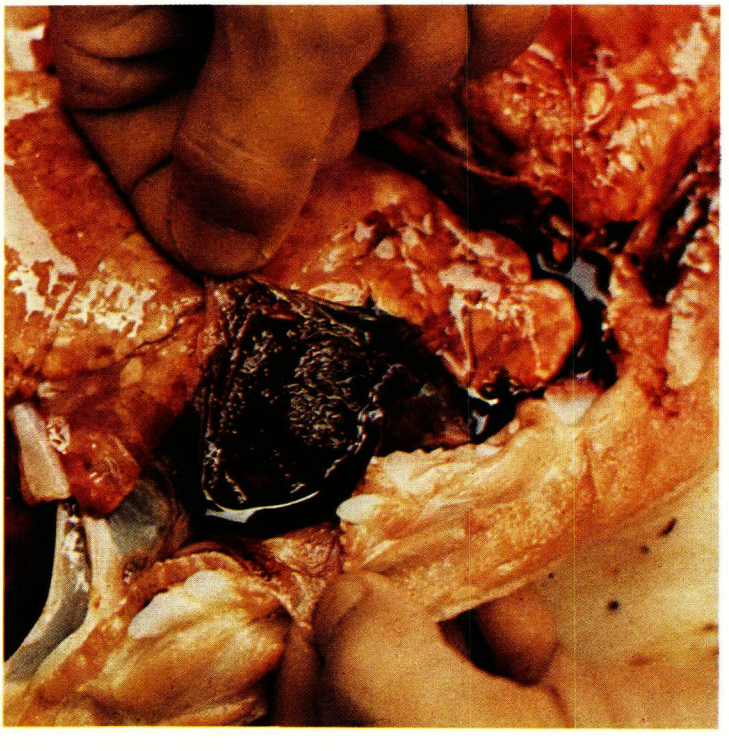

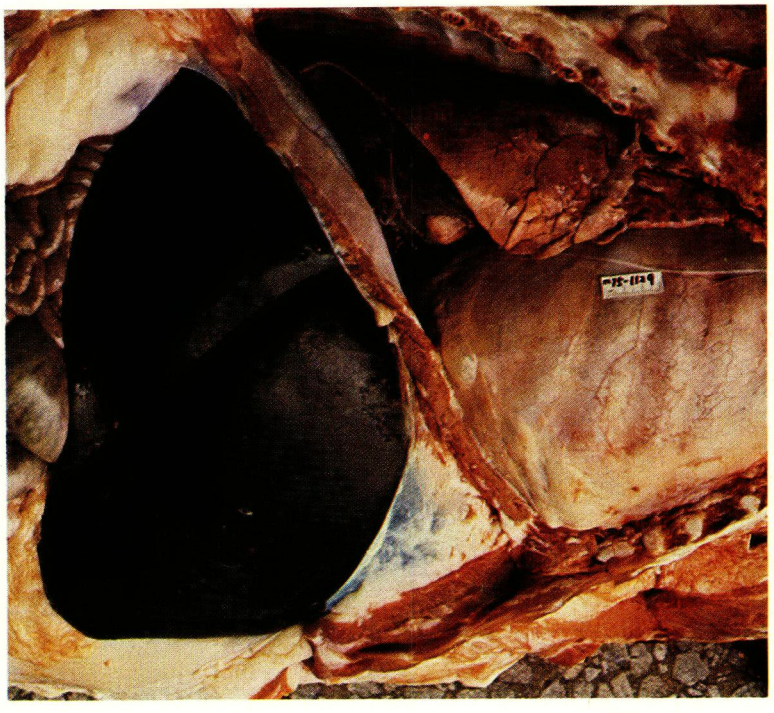

PLATE 357: PURULENT PERICARDITIS

The pericardial sac is dilated 3-4 times normal, is thickened and shows definite rib impressions on its surface. One should consider such diagnoses as a diaphragmatic hernia or cardiac tamponade. This is a case of the heart sac being dilated with fluid, fibrin and purulent debris probably as a sequel to polyserositis or any septicemic infection that localized in the heart sac. Any of numerous organisms may be isolated from such cases. The liver is also enlarged and dark with passive congestion from the increased pericardial pressure decreasing blood return to the right heart from the liver.

PLATE 358: FIBRINOUS PERICARDITIS (ACUTE PERICARDITIS)

The large clumps and granular bits of fibrin are seen attached to both surfaces of the pericardium. This can be pulled off and broken rather easily demonstrating that it is fibrinous tissue. Fibrous tissue is collagen and relatively tough in comparison to fibrin. All similar cases should be cultured. Many organisms as Hemophilus spp. and Pasteurella spp. are commonly isolated. If no specific portal of entry such as an umbilical infection or ear notch wound is found, one should give more weight to the diagnosis of polyserositis (Glasser's disease) caused by Hemophilus spp.. Fibrin takes only seconds to minutes to form, so this is an acute to subacute process as differentiated from a chronic process wherein fibrous tissue is formed.





PLATE 359: FIBROUS PERICARDITIS (CHRONIC PERICARDITIS)

The definite whitish tissue adhesion between these two layers of pericardium is a collagenous (fibrous) connective tissue adhesion which is not easily broken nor torn from the attached areas in contrast to the other bits and strands of debris adherent loosely to the pericardium. Because of the two processes being present at the same time, one should consider this a still active chronic pericarditis to distinguish it from a chronic adhesive process where no acute inflammation or its components, such as fibrin production, are present. Almost all cases of pericarditis are associated with a septicemic infection. One should look for the portal of entry such as an umbilical infection or consider a primary septicemic organism as Hemophilus spp. or Pasteurella spp..

PLATE 360: POSTMORTEM PALLOR (PM PALLOR)

The large pale area (PM pallor) of the left ventricle may be seen on this heart with a slight fibrinous pericarditis. Adjacent organ or tissue pressure has squeezed the blood out of this pale area in an otherwise congested epicardium. The PM pallor can thus be considered an artefact.

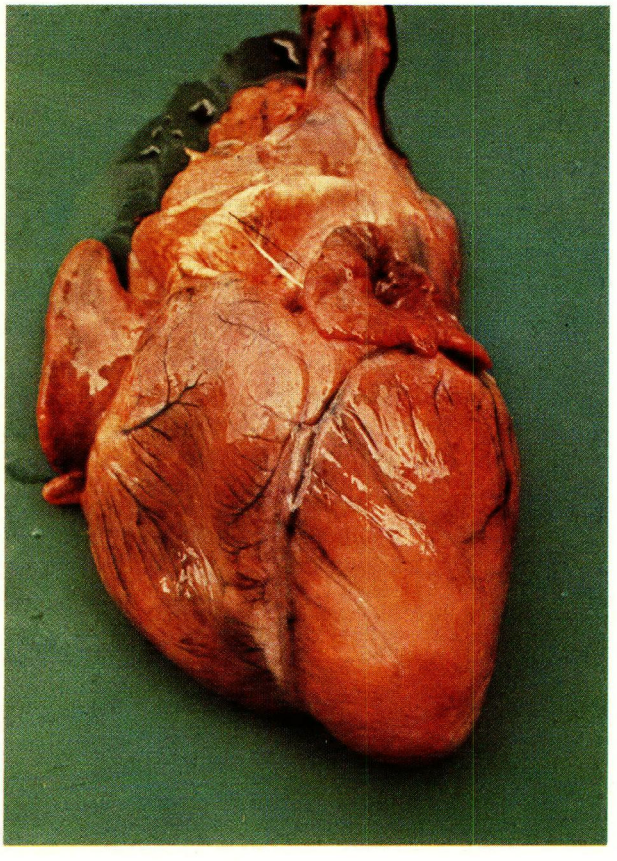

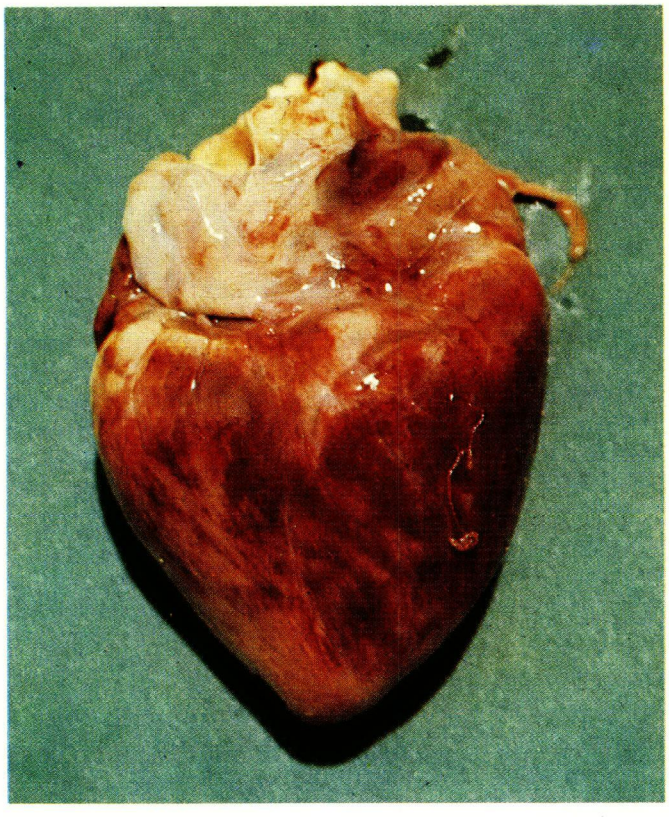

PLATE 361: EPICARDIAL HEMORRHAGES

The large areas of hemorrhages on the epicardium of both ventricles with some over the left auricle are common findings in many animals that die under all types of circumstances, even normal animals killed for necropsy demonstration. They should not be considered diagnostic for any specific disease. On the other hand, if these were large blebs or lakes of blood, we should consider a definite bleeding problem in any species or enterotoxemia in cattle, sheep or pigs.

PLATE 362: ENDOCARDIAL AND MYOCARDIAL HEMORRHAGE

The large areas of endocardial and myocardial hemorrhages scattered in this heart are quite non-specific although others consider them diagnostic for some diseases. They are commonly seen in many species of animals dying from a variety of causes including septicemias and physical stress. This was a case of asphyxiation in a pig. It is probably just a terminal event brought about by unequal pressures within the heart as the animal dies. Large lakes and pockets of hemorrhages on the otherhand, should make one consider a bleeding disease such as a Vit K deficiency.

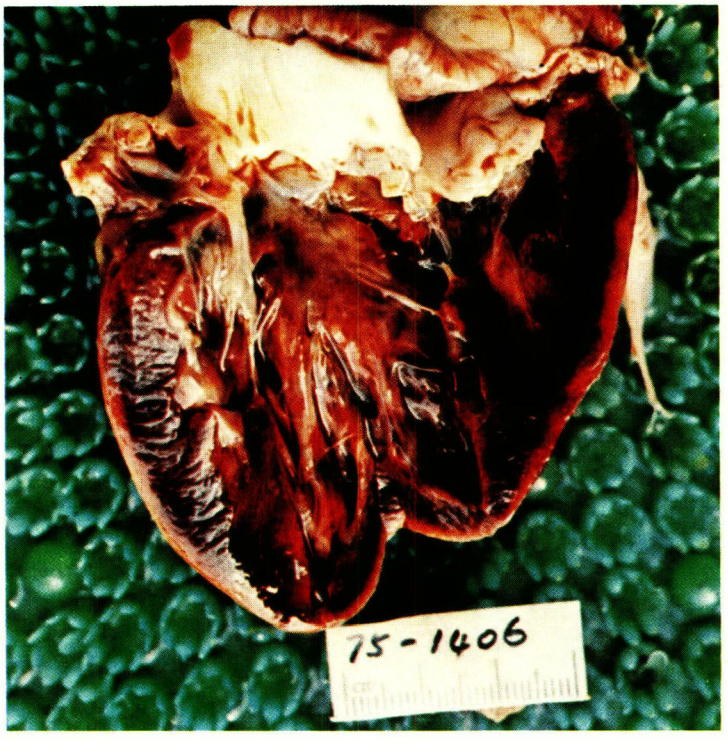

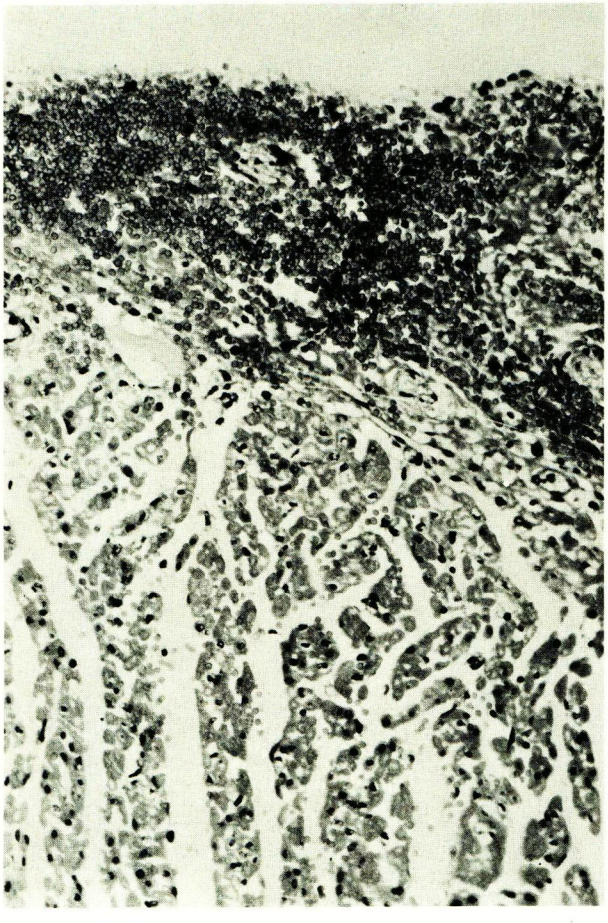

PLATE 363: EPICARDIAL HEMORRHAGE

An area of epicardium has been separated from the muscle by a collection of red blood cells. This could also be an area of the endocardium. It lacks any other reaction to suggest inflammation and thus probably represents an acute terminal episode of bleeding. This is so common in animals dying from a variety of causes that it is quite nondiagnostic by itself.

PLATE 364: MYOCARDIAL HAMARTOMA

This single, discrete, 12x8mm. mass in the left ventricular wall of a day old piglet is a hamartoma of cardiac muscle which is a congenital, redundant amount of tissue, normal to the area in which it is found. Some call it a "fetal tumor". This type in the heart, vascular ones in the broad ligament and ovary and bronchial hamartomas are the most common examples.

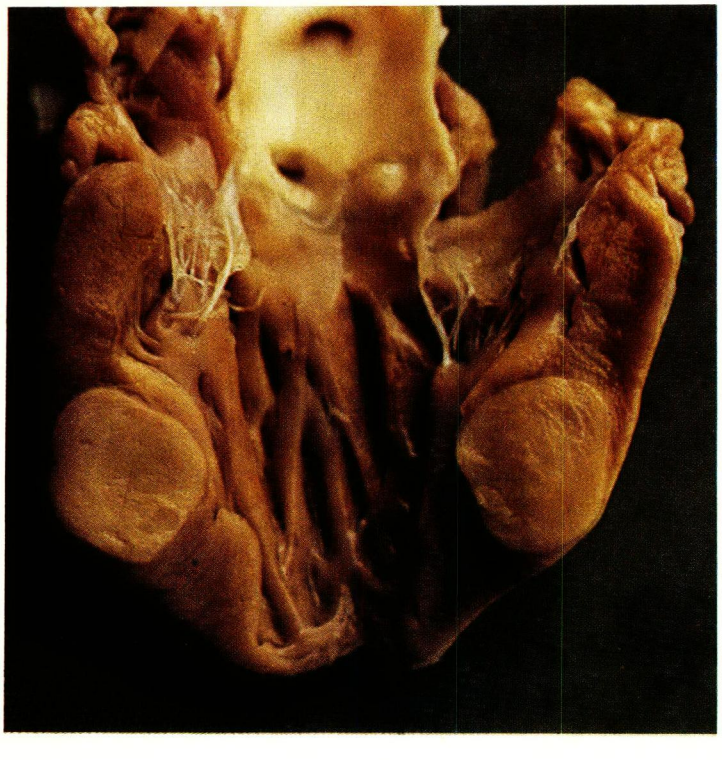

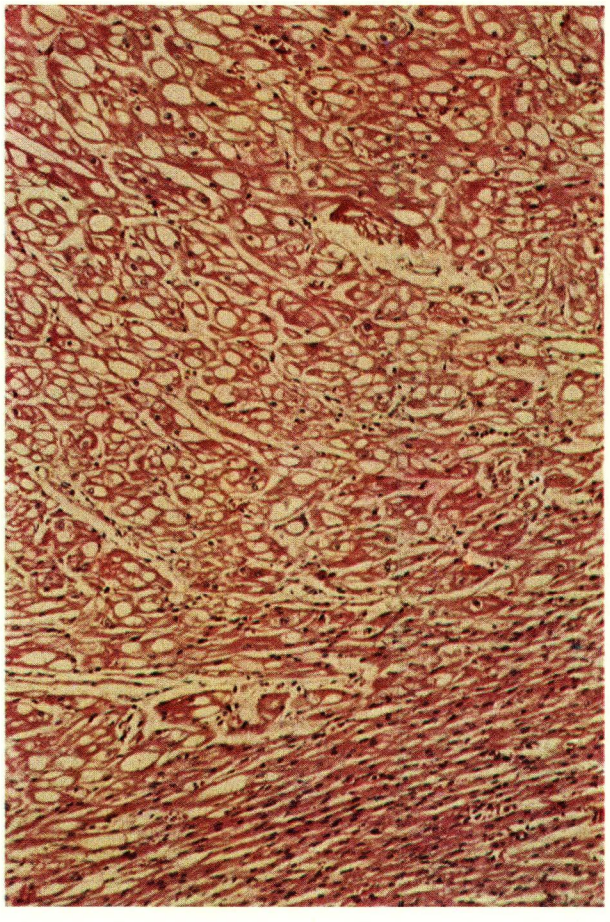

PLATE 365: MYOCARDIAL HAMARTOMA

The bottom fourth of this picture is of normal fetal heart muscle. The remainder is of the rhabdomyomatous proliferation of cardiac muscle found in a discrete focus in a day old piglet. It shows the rather bizarre muscle cells, most of which contain large vacuoles to one side of or surrounding the nucleus. Some pathologists call this an anomaly and others call it a "fetal tumor".

PLATE 366: HEMATOCYST

A 5 mm. blood filled cyst is present near the base of the mitral valve of this perinatal pig. This is a common lesion in many neonates of all species. Some may be serum and not blood filled and most disappear with time. It has been shown that they are caused by defects in capillary development in the embryo.



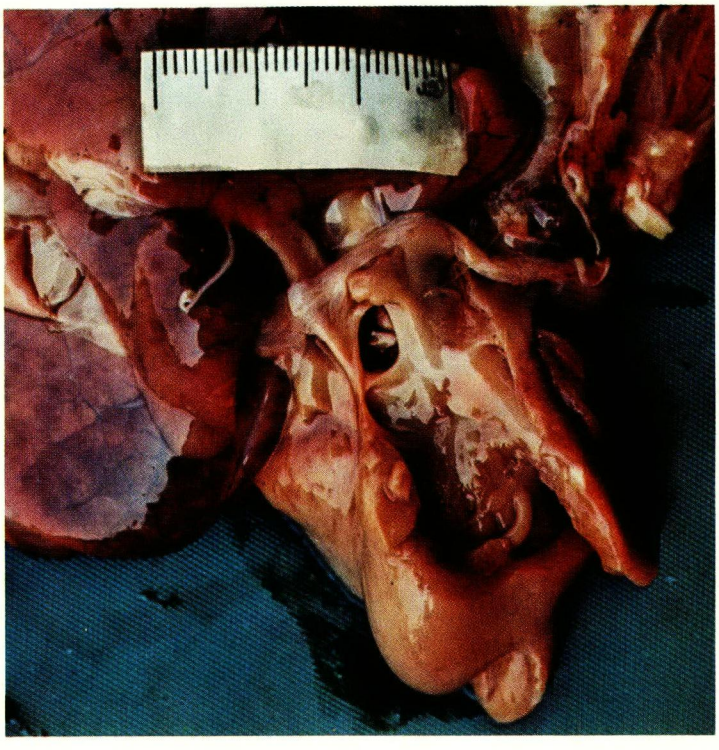

PLATE 367: NORMAL FORAMEN OVALE

The oval opening in the upper part of the opened right heart is the normal foramen ovale of this neonate. It is located at the entrance of the caudal vena cava and above the small ridge separating it from the coronary sinus. In utero this shunts most of the blood coming from the placenta to the left heart from where it is pumped to the rest of the body thus bypassing the nonfunctional lungs. It may remain patently open for days or even weeks in a normal animal, but it functionally closes at birth.

PLATE 368: PERSISTENT FORAMEN OVALE

This 4 mo. old pig's heart was enlarged and the liver showed typical chronic passive congestion (nutmeg). The heart was dilated and when opened, blood could be squeezed easily from the left to the right heart. A one cm. slit like opening is shown here by the needle in the lumen. It had a rough, thickened endothelial border and opened from one atrium to the other. The foramen ovale normally closes at birth, at least functionally, but it may not close morphologically for days to even weeks postpartum. In these normal cases, blood cannot be pressed from heart to heart and the openings in either side are smooth and flat.

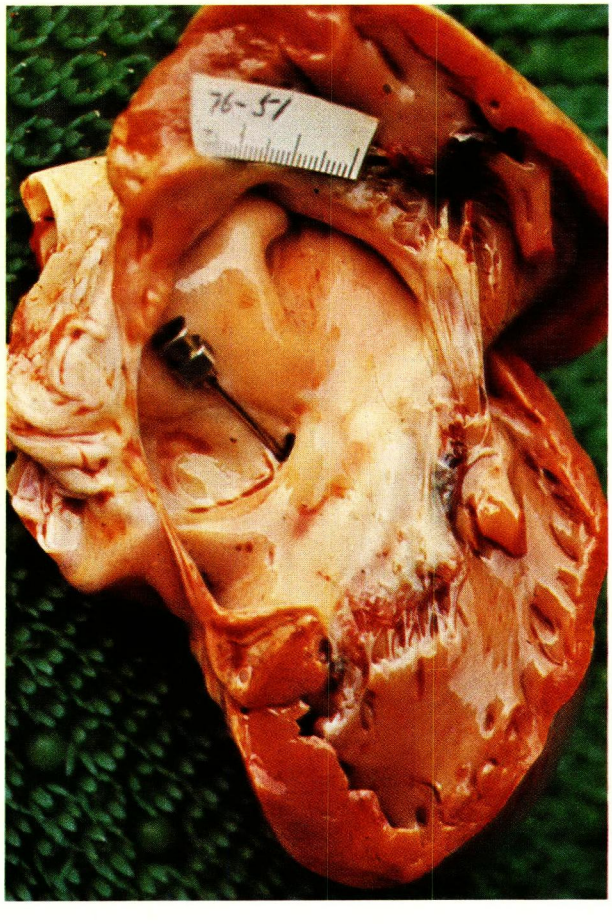

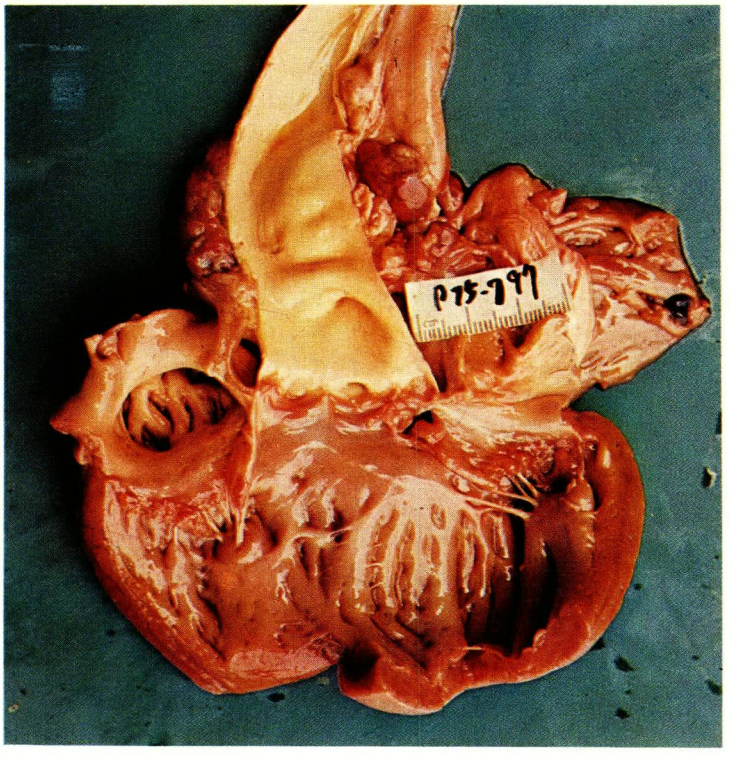

PLATE 369: SUBAORTIC SEPTAL DEFECT

A more precise name for this anomaly is a subaortic interventricular septal defect as it is a defect of the septum under the aorta that opens between both the ventricles. It is recognized here on the left side as an irregular, fibrous ringed opening just under the right cusp of the aortic valve. This is the most common location for this lesion but it may also be found in other nearby areas. The left ventricle is moderately dilated as a result.

PLATE 370: SUBAORTIC SEPTAL DEFECT

Just under the aortic valve cusps, or more correctly stated, between two cusps of the aortic valve, is an irregular, fibrous ringed opening into the right ventricle through which a small stick has been placed. It opens just under the right A V valve in the right ventricle. It is an easily overlooked lesion.

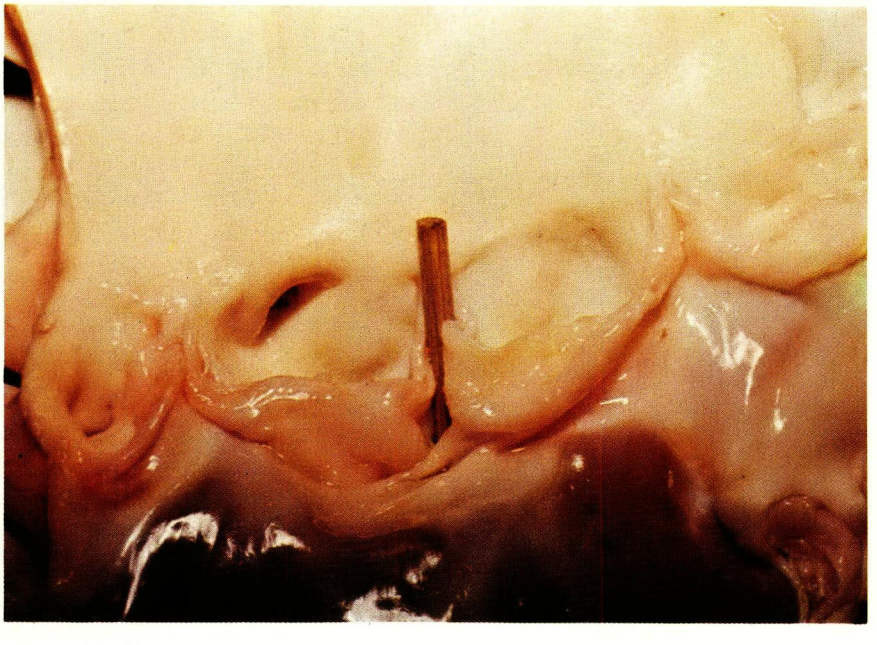

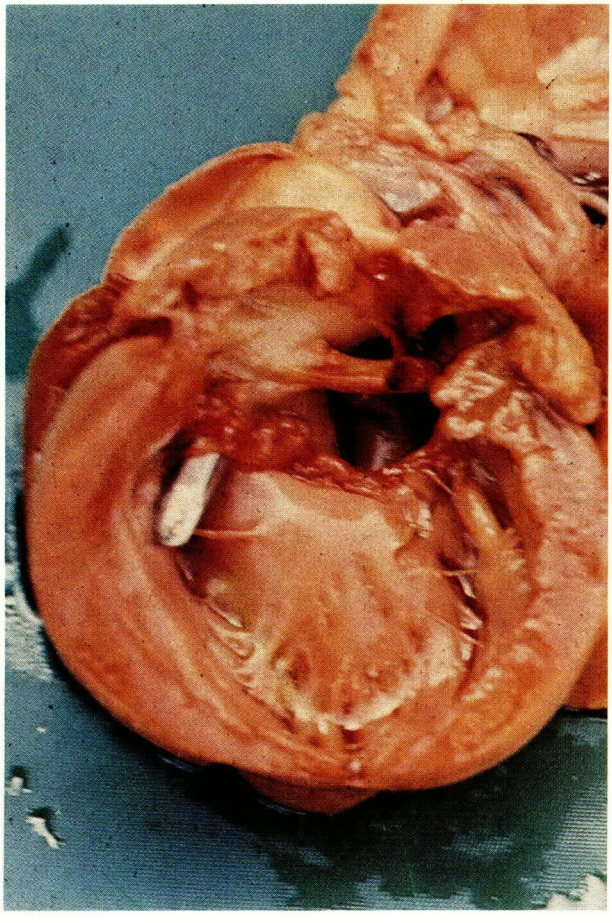

PLATE 371: INTERATRIAL SEPTAL DEFECT

The left heart has been opened to show the compensatory hypertrophy of the ventricular wall. A large opening is in the left atrium above the mitral valve which communicates with the right atrium. A metallic probe was threaded down the aorta and into the left ventricle. It is seen protruding from under the anterior cusp of the mitral valve. The large opening between the atria is the anomaly. It has caused passive congestion of the lungs and liver as well as the hypertrophied left heart.

PLATE 372: SUBAORTIC STENOSIS

The white irregular band or ridge two centimeters under the aortic valve is the anomalous tissue causing the stenosis. It is found in many species, but apparently it is quite common in pigs in certain geographical areas. This lesion interferes with outflow from the left heart and causes the hypertrophy which is seen here. Chronic passive congestion of the lungs (heart failure lungs) and even chronic passive congestion (nutmeg) of the liver, with or without pulmonary congestion, may occur. This latter response is difficult to explain.

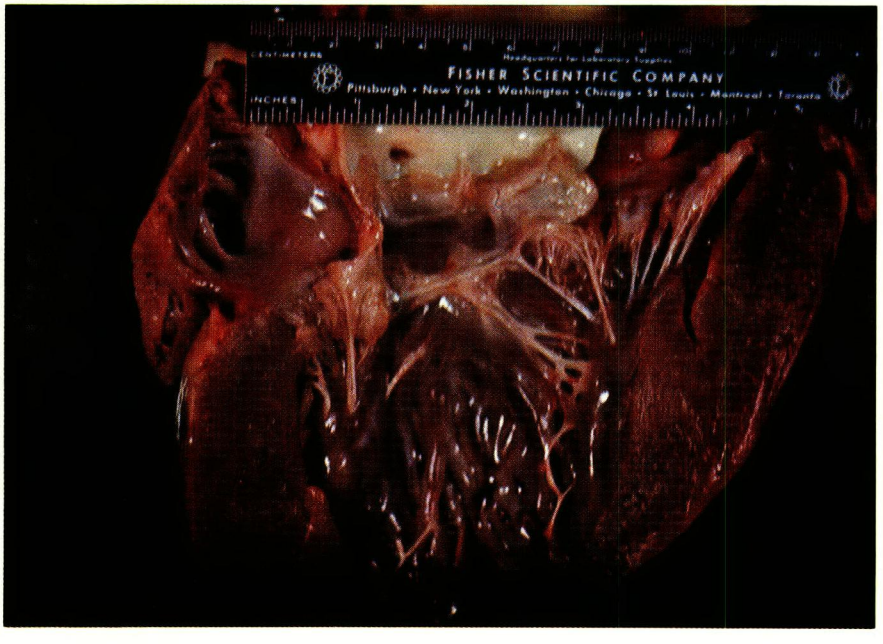

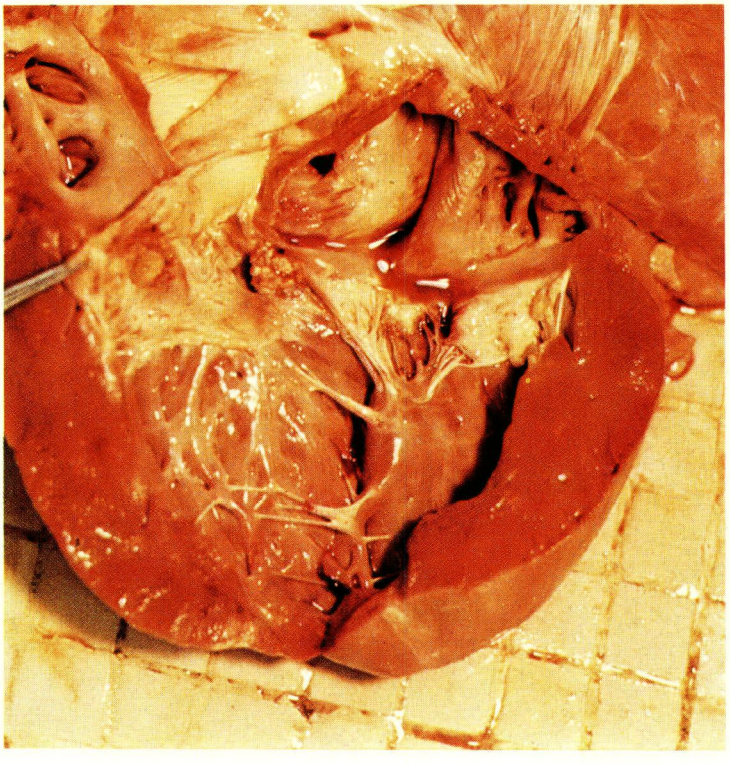

PLATE 373: SUBAORTIC STENOSIS AND VEGETATIVE ENDOCARDITIS

The forceps are holding the fibrous tissue and part of the left AV valve away from the vegetative endocarditis affecting the aortic valve area. The major portion of an anomalous fibrous tissue ring causing the stenosis is the irregular band of tissue on the endocardium about two centimeters below the aortic valve cusps. The cut portion of the anterior cusp of the left AV valve is in line with the cut aortic wall proper, and a small bit of rough irregular vegetative endocarditis is attached to it. The left ventricle is thickened from compensatory hypertrophy as it must work harder to push blood through the stenotic opening. This picture is used to demonstrate that vegetative (bacterial) lesions often develop as a result of anomalies that roughen and damage endothelium allowing infective thrombi to develop.

PLATE 374: MYOCARDIAL DILATATION

The slightly rounded overall appearance of the apex and the sunken wall of the right ventricle demonstrates dilatation. Normally the apex of the pig's heart is relatively pointed, and any roundness should be suspect. Primary heart lesions as myocardial degeneration in Vit E/Se responsive disease, or increased peripheral blood flow resistance as in lung disease for the right heart or aortic stenosis for the left heart may cause dilatation. Passive congestion of the lung or liver may develop. If the animal lives after the primary dilatation occurs, the affected ventricle may hypertrophy (cor pulmonale). If the inciting causes are not removed, a secondary dilatation may occur and is usually fatal.

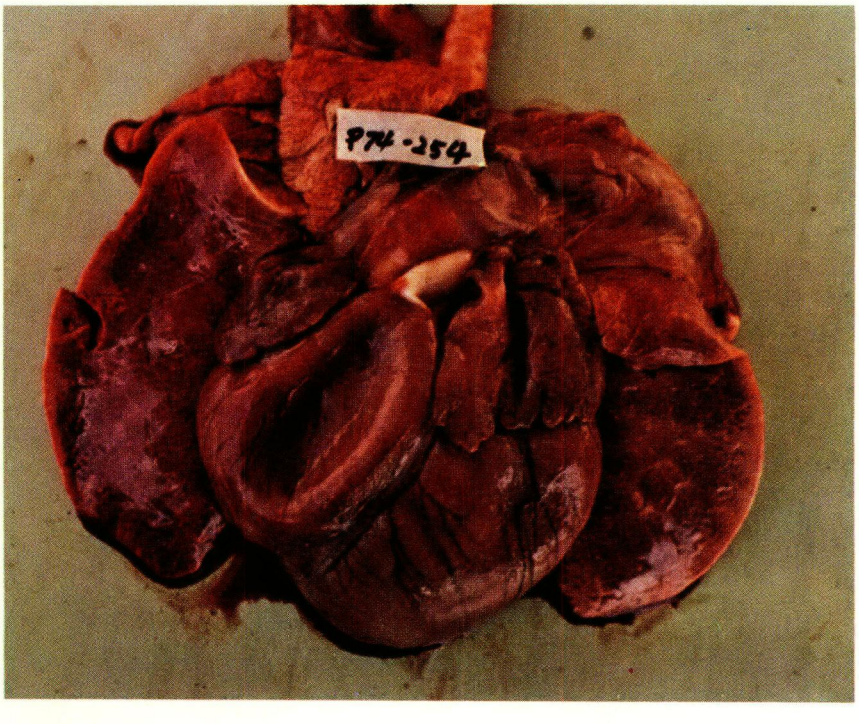

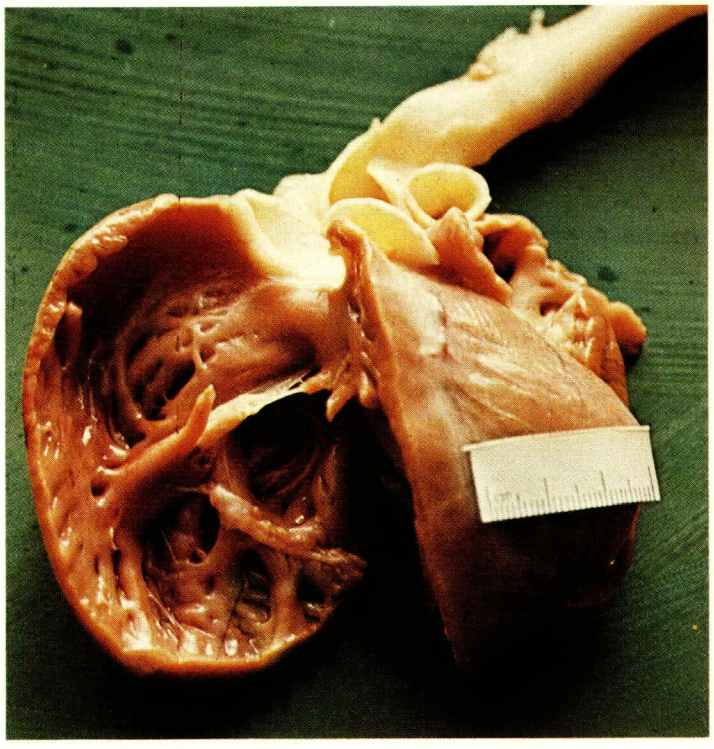

PLATE 375: MYOCARDIAL DILATATION

This opened right heart shows the increased lumen size and the slightly thinned right ventricular wall. This was the result of a chronic resolving bronchopneumonia that increased the resistance of blood flow out of the right heart. Some say it is a purely mechanical effect while others suggest some myocardial hypoxia or a combination of the two.

PLATE 376: HYPERTROPHIED RIGHT HEART

The overall view of this heart shows that it is as broad as it is long giving it a rounded appearance. A normal pig's heart is more pointed with the length being visibly greater than its width. This piglet had a subaortic septal defect, with the high pressure from the left ventricle transferred through the anomalous opening to cause the marked thickening of the right ventricle wall (hypertrophy). This is to be differentiated from cor pulmonale which is hypertrophy as a result of a lung lesion.

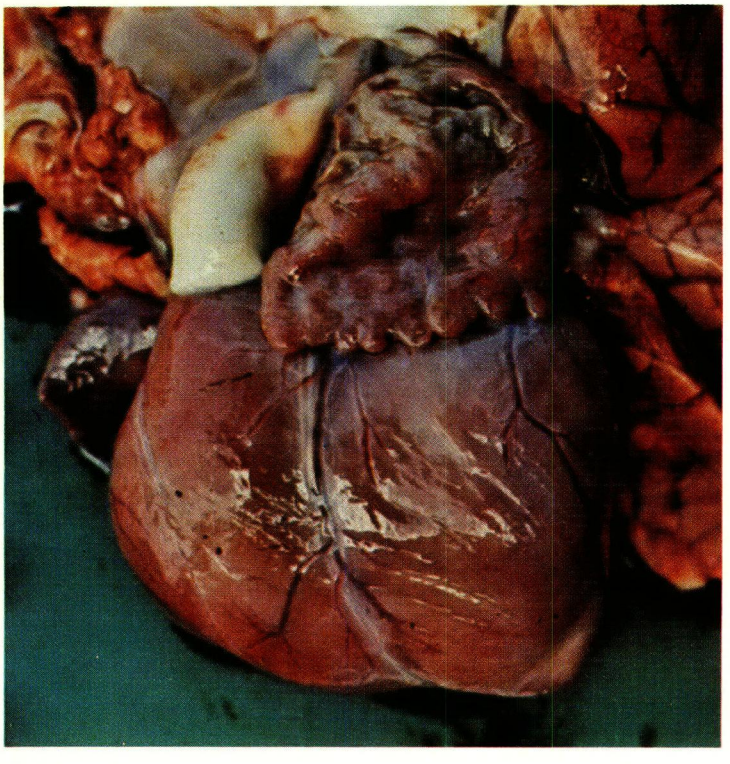

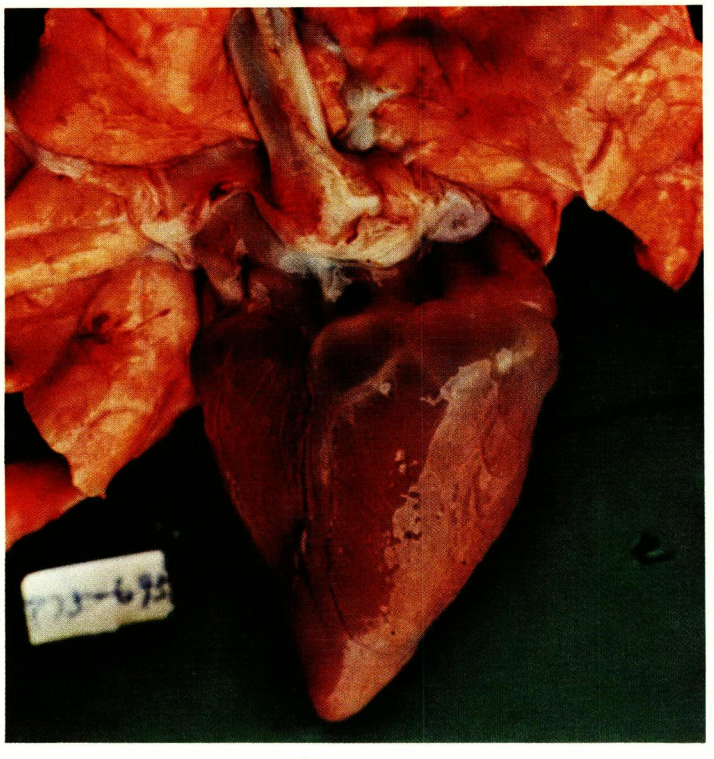

PLATE 377: HYPOPROTEINEMIC EDEMA

The soft connective tissue about this area of the coronary groove over the right ventricle is markedly swollen with a relatively clear fluid. The lungs and heart themselves are pale in this animal that died from exsanguination through a gastric ulcer. The resulting blood loss decreased the intravascular osmotic pressure so much that edema developed. In more chronic cases of hypoproteinemia, other areas as the legs and ventral neck regions tend to be more severely affected than the coronary groove.

PLATE 378: NUTRITIONAL MUSCULAR DYSTROPHY

The cut section of the left ventricle shows the opaque white, affected muscle distinctly separate from the more normal darker muscle. The upper portion of the left ventricle with the three or four transverse cuts show its surface appearance also as being opaque white and distinct from the red grossly unaffected muscle. Some apparent streaks of hemorrhage are associated with the affected fibers. These areas are slightly elevated from the nonaffected areas. In some animals, usually directly related to muscle activity, muscles such as those of the legs in the beef calf may be more affected than other muscles, while the crate raised dairy calf, whose activity is almost limited to sucking, will have the earliest and often the only lesions in its muscles of deglutition. Histologically, the lesion is one of swollen, hyalinized muscle fibers (Zenker's degeneration). This is a Vit E/Se responsive disease and in calves it is usually called white muscle disease. In sheep, it is referred to as stiff lamb disease. White muscle lesions are seen in the pig, but the more common lesion is a unique liver necrosis called hepatosis dietetica which does not occur in the other species.





PLATE 379: NUTRITIONAL MUSCULAR DYSTROPHY

Eighty percent of this calf's left ventricle is opaque white which is seen in both the cut and endocardial surface views. These areas are remarkably distinct from the dark red normal muscle. The left ventricle is dilated from myocardial failure and the lungs are slightly firm, wet and heavy from passive congestion (acute heart failure lung). This is a Vit E/Se responsive disease.

PLATE 380: ZENKER'S NECROSIS (DEGENERATION)

The long pale fibers are essentially normal. Between several of these can be seen many round cells about segments of swollen, hyalinized, degenerating fibers with loss of cross striations (Zenker's necrosis). This is a subacute case as there has been time for inflammatory cells to appear. In some cases, there is a surprising number of neutrophils. In chronic cases, the viable sarcolemmal nuclei may proliferate and with time, even severe cases may completely regenerate the damaged muscle cells. This is the characteristic lesion of nutritional muscular dystrophy of many species and azoturia in horses. It can be seen as a focal lesion in almost any traumatic lesion of muscle. Although this is a picture of skeletal muscle, the lesion is the same for all striated muscle including the heart.

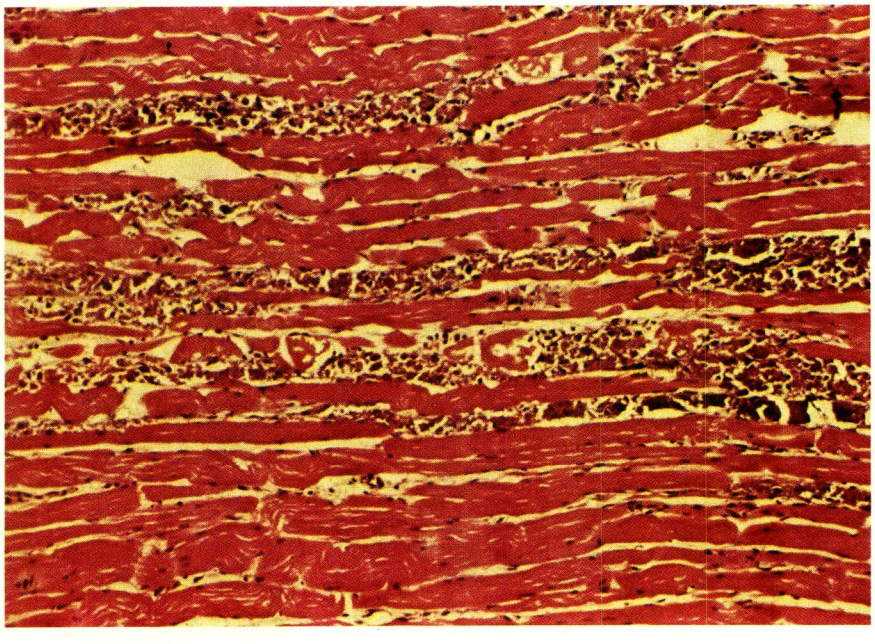

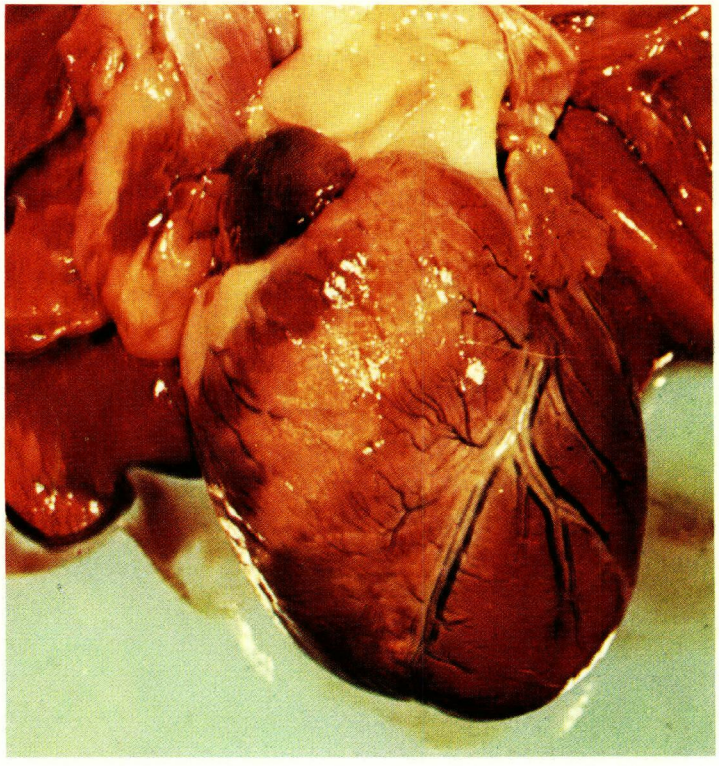

PLATE 381: BRAIN/HEART SYNDROME

The myocardial degeneration of this newly recognized disease is seen here as the large rectangular pale area of the right ventricle with several smaller foci scattered in the remaining ventricular wall. These are classical areas of Zenker's degeneration. Although quite extensive in this dog's heart, the lesion may be of any size and in either heart. Often only a tiny pale focus may be seen just under the endocardium. The name of the disease came about from the fact that the initial cases were in dogs that had suffered traumatic vertebral fractures or head injuries. Numerous subsequent cases have included animals without blunt trauma, such as dogs with prolapsed intervertebral discs and distemper, and dogs and cats with brain tumors and cattle, sheep and goats with acute listeriosis. Experimentally, it has been reproduced by blood injections directly into the brain, probably via a neurogenic hormonal response.

PLATE 382: CHRONIC FOCAL MYOCARDIAL DEGENERATION

This single focus is a fibrous tissue scar without any inflammatory cell response, but it has some mineral deposition, probably calcium, scattered in the lesion. The irregular dark line at the edge of the lesion is an artefact. With such a lesion, one should suspect that it could be the result of an infarct, trauma from a needle wound or even a lesion of the brain/heart syndrome as it was. One of the authors saw many of these in an older serviceman's heart and was told it was from coronary heart disease which incidentally was not present in the individual. No explanation was forthcoming at that time, but it is suggested now that they may have been related to the brain/heart syndrome.

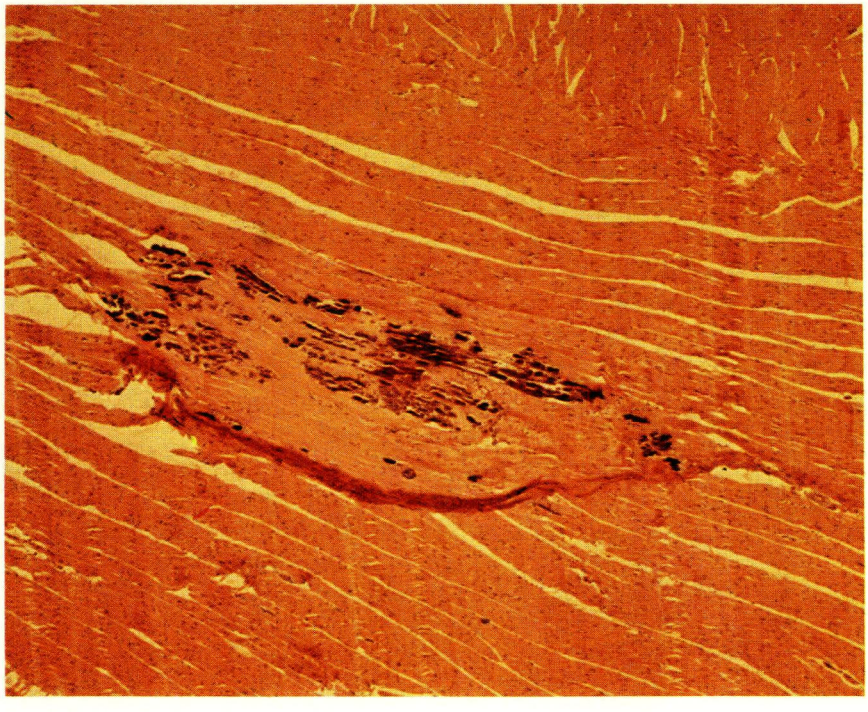

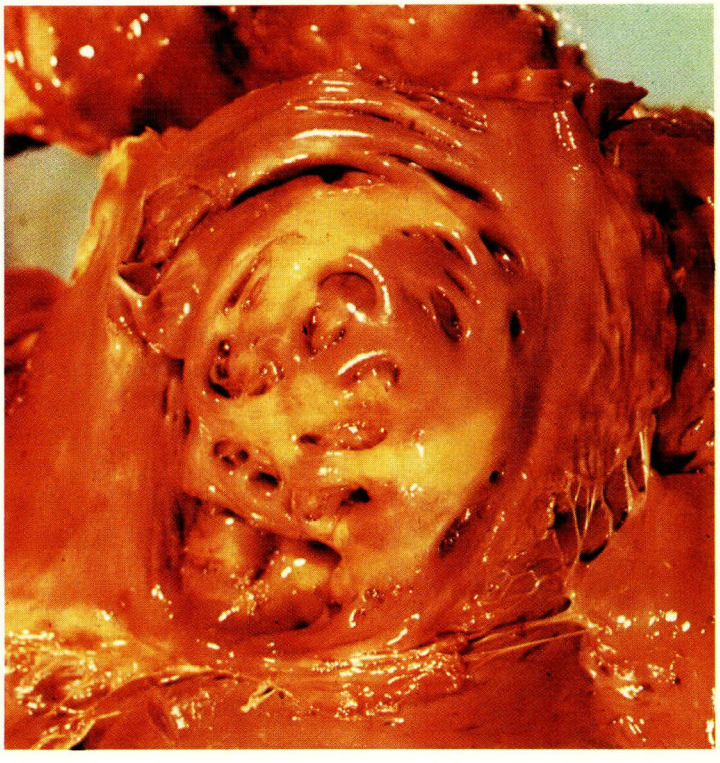

PLATE 383: FATTY INFILTRATION

The right atrium of this horse's heart has been stretched open to show the several large, yellow, irregular areas of adipose tissue replacement of heart muscle. These are areas of healed infarcts which are relatively common in horses with strongyle lesions in the area of the coronary artery openings of the aorta. In cattle, a pale tissue infiltration in this same area is usually lymphoid neoplasia. Why this area is so predisposed in both cases is unknown.

PLATE 384: VEGETATIVE ENDOCARDITIS

Friable, yellowish, irregular masses are attached to the aortic and left A.V. valves. These are intimately attached to the damaged, underlying endocardium and are true thrombi. A smooth, elastic, chicken fat clot is present in the left auricular appendage with a small piece of current jelly clot attached to it. While E. rhusiopathiae is a commonly isolated agent, almost any organism may be isolated as Streptococcus spp. was in this case. Embolic showers to the kidney, spleen, heart and other organs may be found. When vegetative endocarditis is found, heart anomalies should be looked for as a predisposing factor. A chronic infectious process in the body such as chronic septic arthritis may also predispose to vegetative endocarditis.

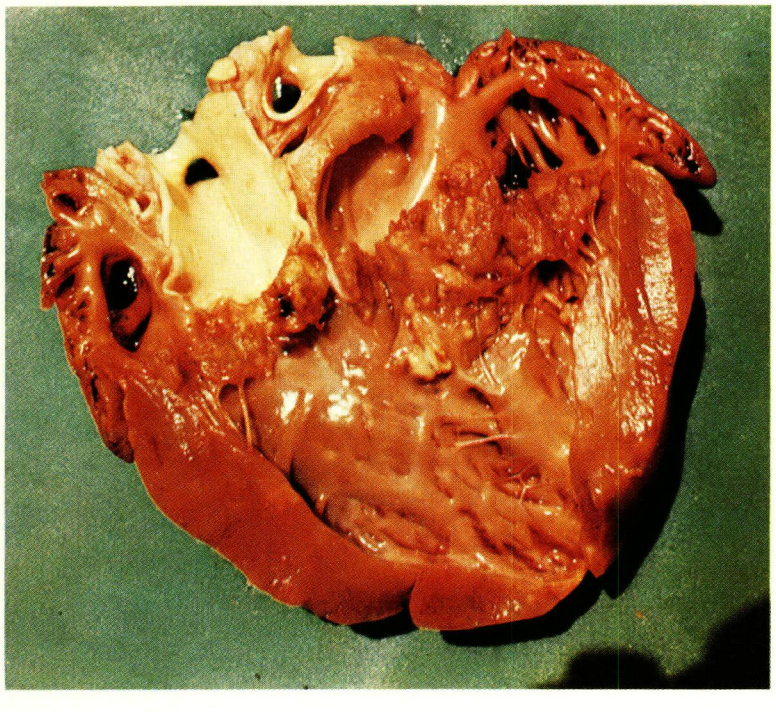

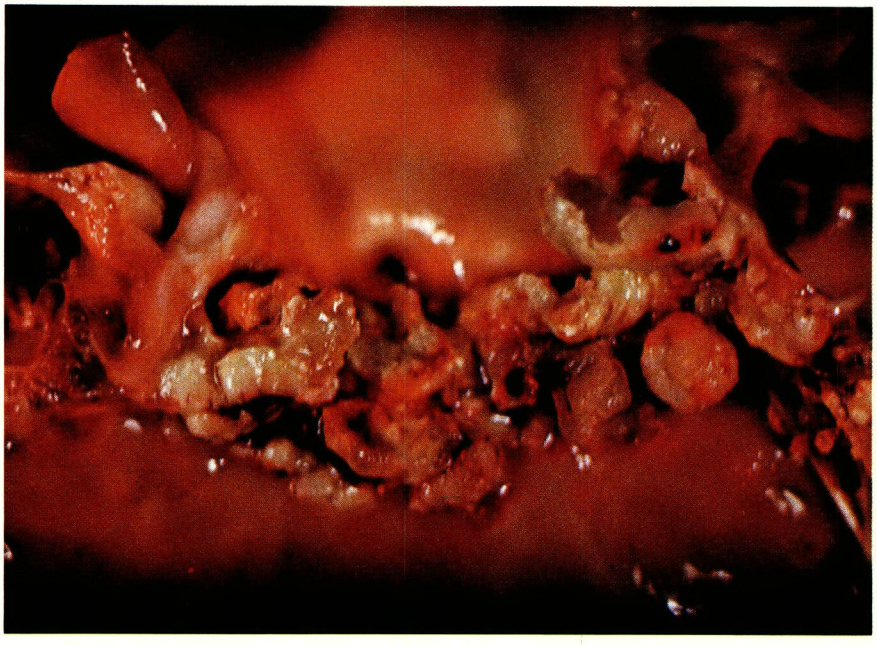

PLATE 385: VEGETATIVE ENDOCARDITIS

This friable, irregular, proliferating mass attached to the aortic valve is a vegetative thrombus associated with a host response to a bacterial infection on the valve. This can be called a valvular endocarditis to distinguish it from a mural endocarditis which would be adherent to the wall proper. These infected thrombi are quite friable and will easily break off to become infected emboli. From this location near the coronary vessels, one of which is seen just above the thrombus, one can see how it can send infected emboli throughout the systemic circulation and also into the coronary circulation itself. A rather consistent clinical feature in fatal cases is the history of a recurring fever. While many organisms can cause this, E. rhusiopathiae should be considered in the pig.

PLATE 386: VEGETATIVE ENDOCARDITIS

This piglet's ear is included to show a possible portal of entry for the organisms that caused the vegetative endocarditis in the left heart. It is quite possible that the ear notch wounds may have been the portal of entry but healed before the sequelae killed the pig. A hemorrhagic infarct is present involving a large area of one kidney and one half of the other kidney. Another area of hemorrhagic infarction is present in the spiral colon. The spleen is swollen with hyperplasia from the chronic infection. E. rhusiopathiae is a commonly isolated agent in endemic areas, but in other geographical areas, many other agents may be isolated.



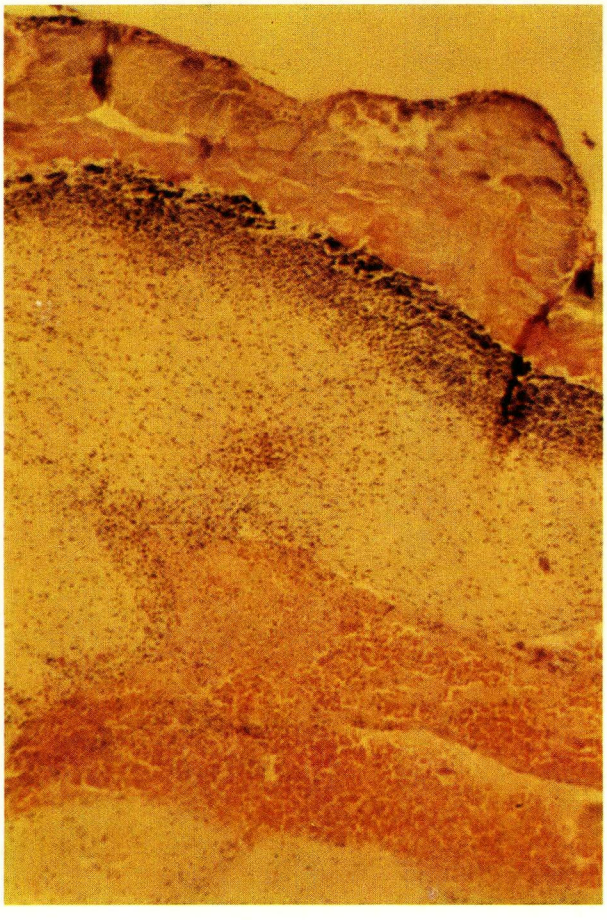

PLATE 387: VEGETATIVE ENDOCARDITIS

This infected thrombus was attached to the aortic valve of a pig. The base of the mass is essentially normal muscle and endocardium. The large areas of blood are areas of lumen under the edematous loose connective tissue of the heart valve which also has numerous inflammatory cells scattered in the valve itself. On the outer valve surface is a dark staining layer of bacteria, cellular debris and neutrophils with a layer of pinkish fibrin attached to it. Its surface has a purplish, finely granular layer of bacteria. Smearing and culturing of such lesions is the only way to arrive at a definitive diagnosis. Chronic infections, such as in the joints, tend to predispose the valves to these lesions.

PLATE 388: EMBOLIC MYOCARDIAL ABSCESS

The rather isolated focus of neutrophils surrounding several elongated dark clumps of necrotic debris and bacteria developed after an embolus had broken off a lesion of vegetative endocarditis on the aortic valve. Vegetative lesions on or near the aortic valve are the most common source for coronary artery emboli especially those in the sinus of Valsalva associated with strongyle lesions in the horse. In diastole, the elastic recoil of the aorta closes the aortic valve, probably with some fluid turbulence which tends to break the friable thrombi. These then pass into the coronary vessels which are receiving blood at this time. A culture would be necessary to identify the causative agent.



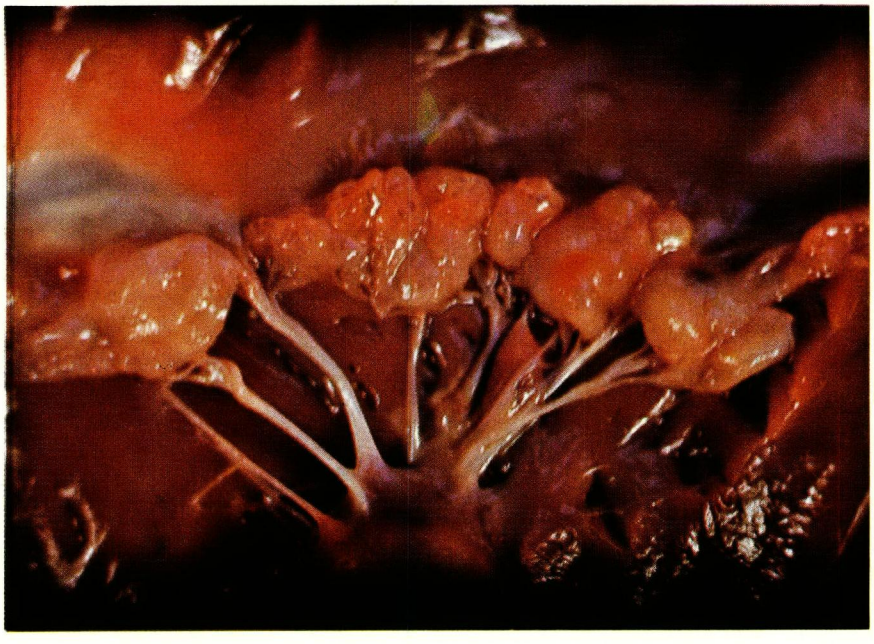

PLATE 389: VERRUCOUS ENDOCARDIOSIS

These irregular wart like (verrucae) thickenings on the heart valve of this dog consist of a fibrous, hyaline, myxomatous tissue associated with aging. Some, like these nearer the base of the valves, show an irregular outpocketing (parachute reaction) into the atrial chamber while others are usually seen as fibrous thickenings (chronic valvular fibrosis) along the free edge of the valves. These smooth, shiny, not friable lesions seen in older animals are to be differentiated from the usually dull, rough, friable lesions (vegetative endocarditis) most commonly seen on the valves of young animals. Vegetative endocarditis can affect older animals also. This lesion of verrucous endocardiosis is the most common cause of heart disease in older dogs.

PLATE 390: RUPTURED CHORDA TENDINA

The left AV valve cusp covering the aortic opening is thick and more opaque than usual, and one of its chordae tendineae has ruptured from its papillary muscle attachment. The ventricle wall is much thickened from compensatory hypertrophy as a result. The cause of such a lesion in this 13 yr. old dog is unknown, but trauma can be suspected.

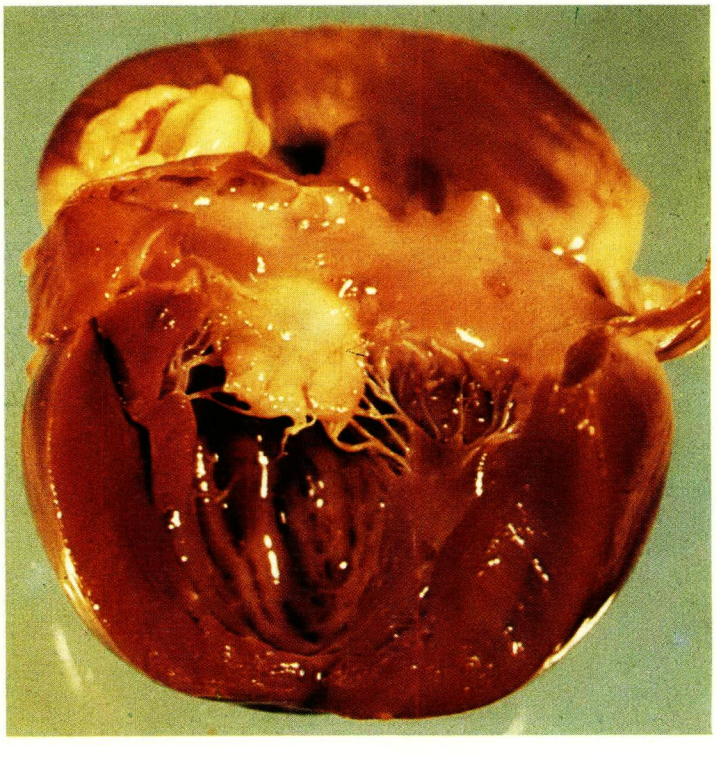

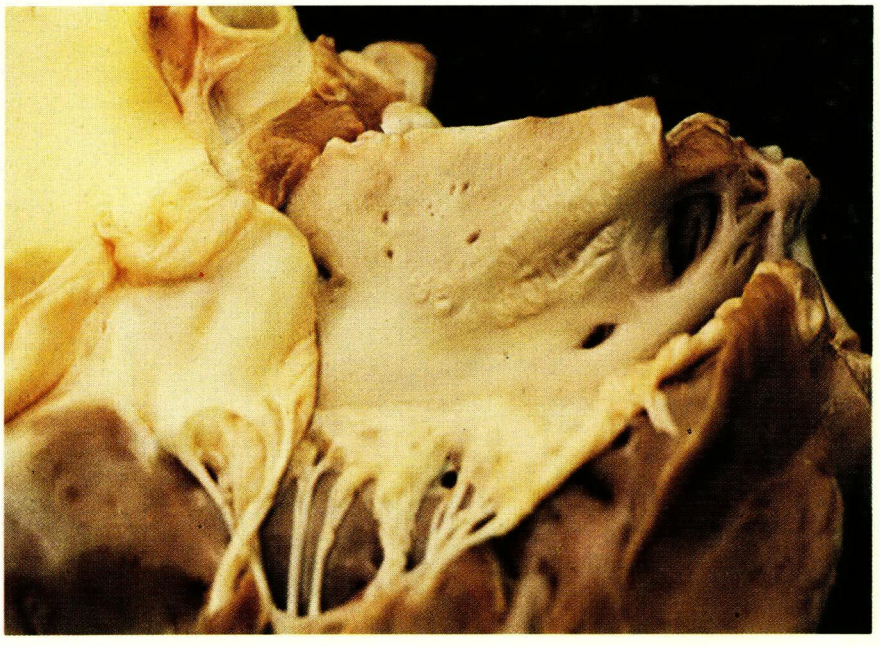

PLATE 391: SPLASH REACTION (JET LESION)

This pale, irregular, roughened lesion of the endocardium in the left atrium is from an abnormal blood flow against the area. A heart anomaly or incompetent heart valves that allow blood to regurgitate (splash) against these areas causes the lesion. Histologically, they are areas of endothelial proliferation and elastic tissue disruption without much inflammatory cell response. This lesion is a common one above incompetent valves in older dogs especially.

PLATE 392: CHICKEN FAT AND CURRANT JELLY CLOT

The yellowish mass (chicken fat clot) is mainly serum mixed with a fibrin clot. The dark red mass (currant jelly clot) consists of red blood cells trapped in a fibrin clot. These postmortem blood clots occurred when the red blood cells settled out after death while the blood was still fluid. Both are shiny, pliable, somewhat elastic, homogeneous and not attached to a damaged endothelium. All of which differentiates them from a thrombus. They are common findings in the heart chambers and major vessels of most dead animals.





PLATE 393: THROMBI

The several pale, yellowish, firm appearing masses lying in the opened splenic vein and one lying on the spleen's surface are clots of blood mostly fibrin. Their grooves and outlines are roughly those of the vein area in which they were found. They are considered to be stagnation thrombi as no evidence of endothelial damage was found to make them the more classical form of thrombi. They are commonly found in the portal vessels in the liver of horses with equine infectious anemia (EIA).

PLATE 394: EMBOLIC THROMBUS

The thrombus is present in the pulmonary artery and has completely obstructed a major portion of it. Its dull, slightly laminated and friable nature is well shown here. The two small pieces extending distally into the vessels are called propagating thrombi. Originally, this started as a bacterial vegetative mass (septic thrombus) attached to the right AV valve. Part of the mass broke off and traveled free as a foreign body (embolus). It lodged in this branch of the pulmonary artery, attached itself to the wall and became a thrombus again. The lung has a competent collateral circulation so infarction is not often seen even when vessels this large are obstructed. This is in contrast to end artery organs as the kidney and spleen.



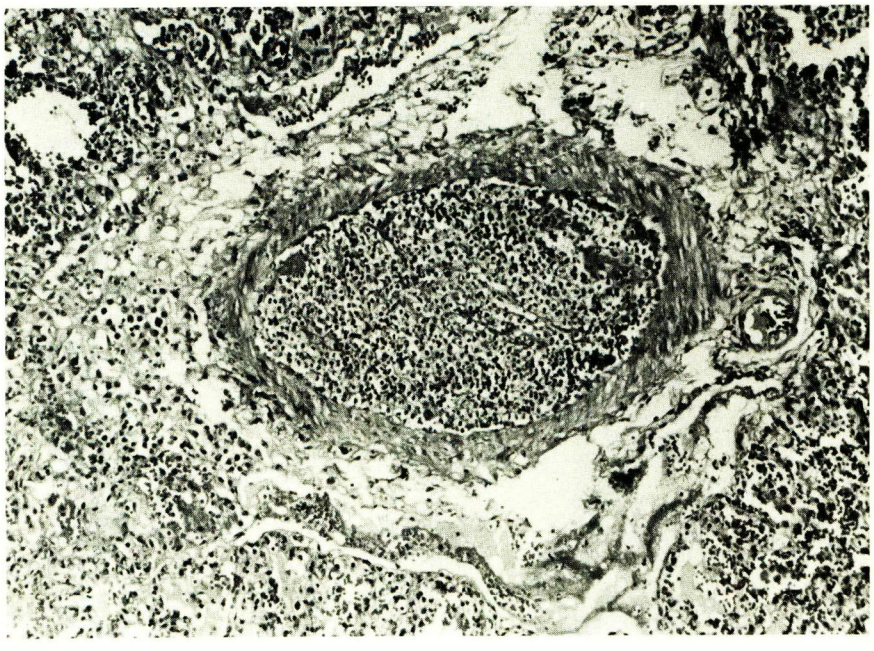

PLATE 395: EMBOLUS

This mass of blood cells (WBC and RBC) trapped in a meshwork of fibrin is a terminal event as shown by the lack of host response in or around the small arteriole involved. Some such as this may actually be a tail of a thrombus. But as the area of endothelial damage is not in the photo, one cannot be sure. This type lesion is often associated with septic processes nearby.

PLATE 396: THROMBUS CANALIZATION

This pulmonary vessel is hardly recognizable as such for a large thrombus has completely blocked its lumen and now consists of much collagen from organization of the thrombus by connective tissue proliferation into the thrombus. In addition, the tiny spaces with blood in them have endothelized and proliferated to invade the mass. They connected with each other to allow blood flow again through the vessel along its longitudinal axis (canalization).

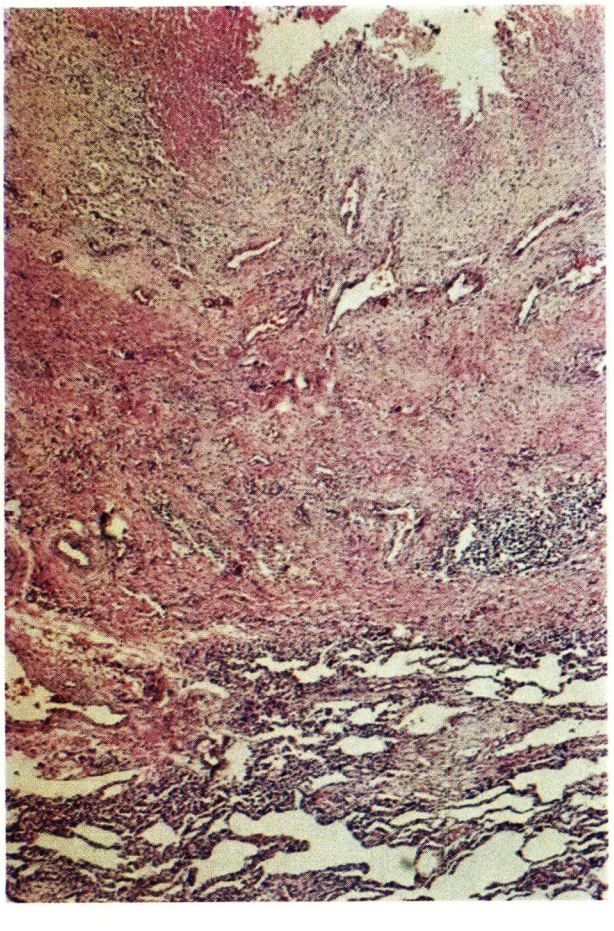

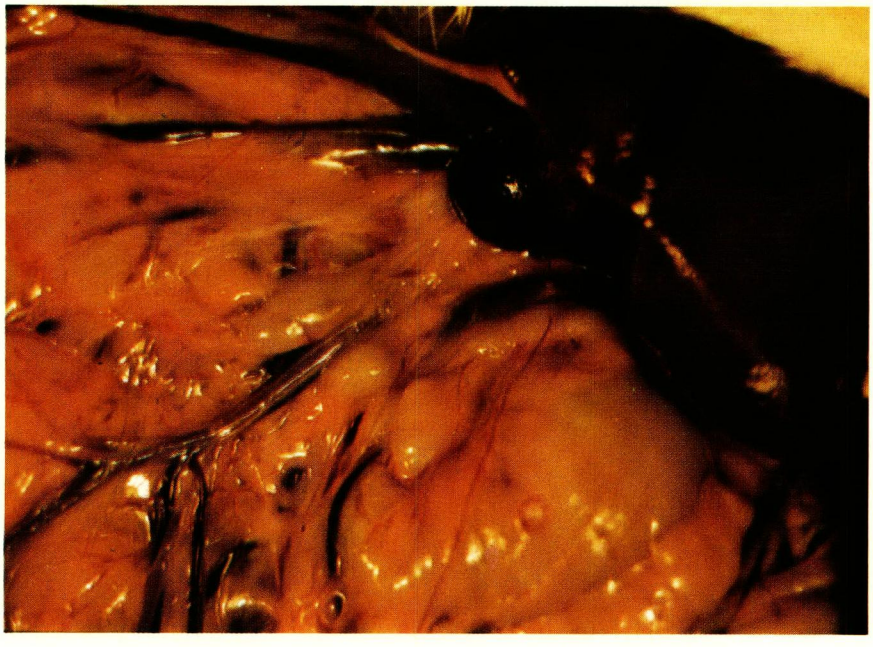

PLATE 397: NORMAL VASCULATURE

In this animal, a normal edge of liver is present along with normal portal vessels and only a few interlacing smaller vessels.

PLATE 398: COLLATERAL CIRCULATION

A small portion of chronic carbon tetrachloride poisoned liver with tiny islands of regeneration can be seen at one edge of the picture and a normal kidney adjacent to it. Entering into the abdominal vena cava just under the kidney are numerous tortuous (medusa head), greatly dilated capillaries from the portal circulation. This is a compensatory attempt to bypass the liver which is preventing normal portal flow because of its diseased state.

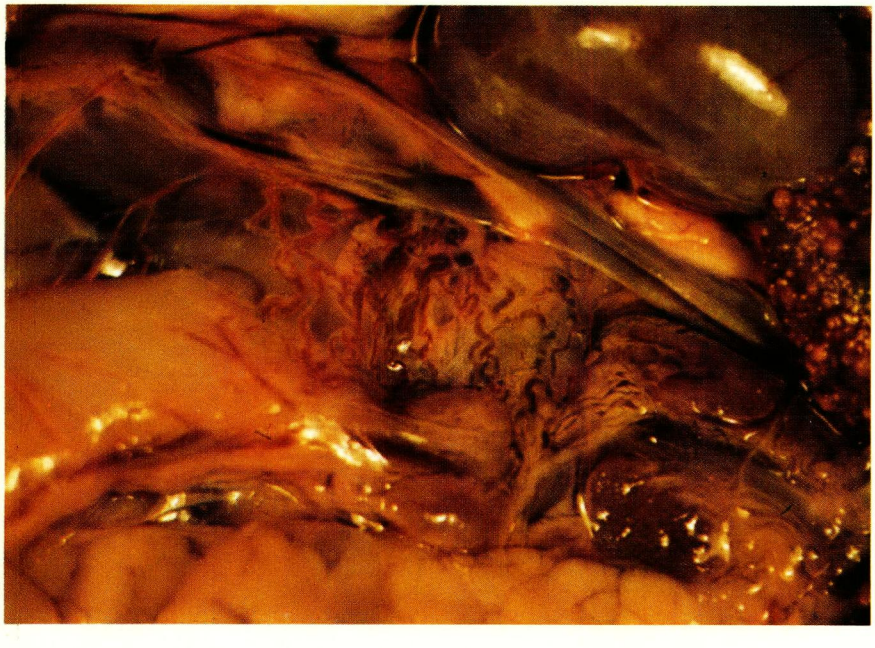

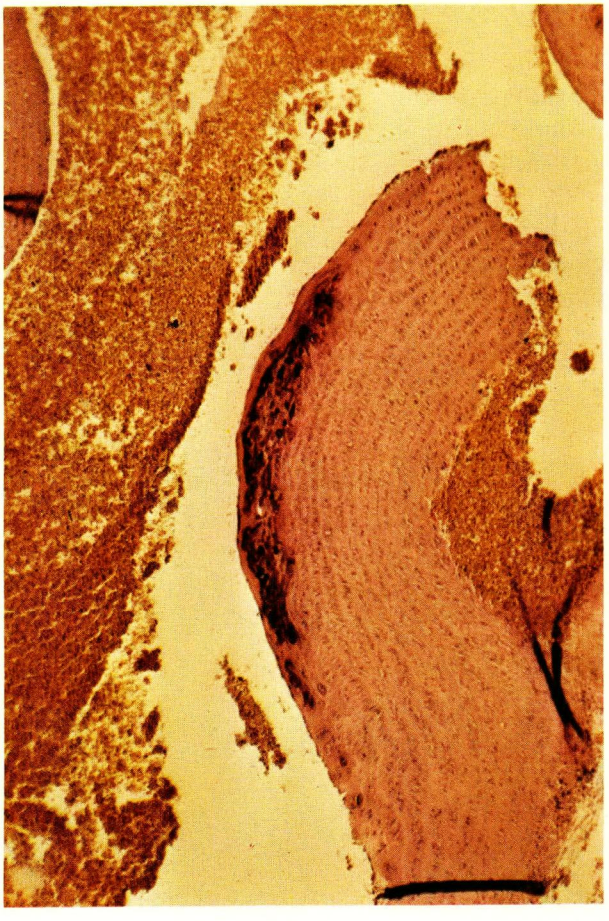

PLATE 399: VASCULAR MINERALIZATION

Just under the endothelium of this large elastic vessel (aorta) is an area of coarsely granular dark staining debris. It is most likely calcium, but other minerals stain similarly. Such a lesion may be seen in cases of renal failure, hypervitaminosis D, hypovitaminosis A and other Vitamin/Mineral imbalances. These mineralized lesions, without known prior damage and related to mineral electrolyte imbalance, are referred to as metastatic while those associated with prior damage in the area are called dystrophic.

PLATE 400: MICROANGIOPATHY (MAP)

The thickening and hyaline degeneration of the small arterioles are hallmarks of this lesion, and most are associated with a Vit E/Se responsive disease. Myocardial and gastrointestinal vessels are some of the more commonly affected vessels.

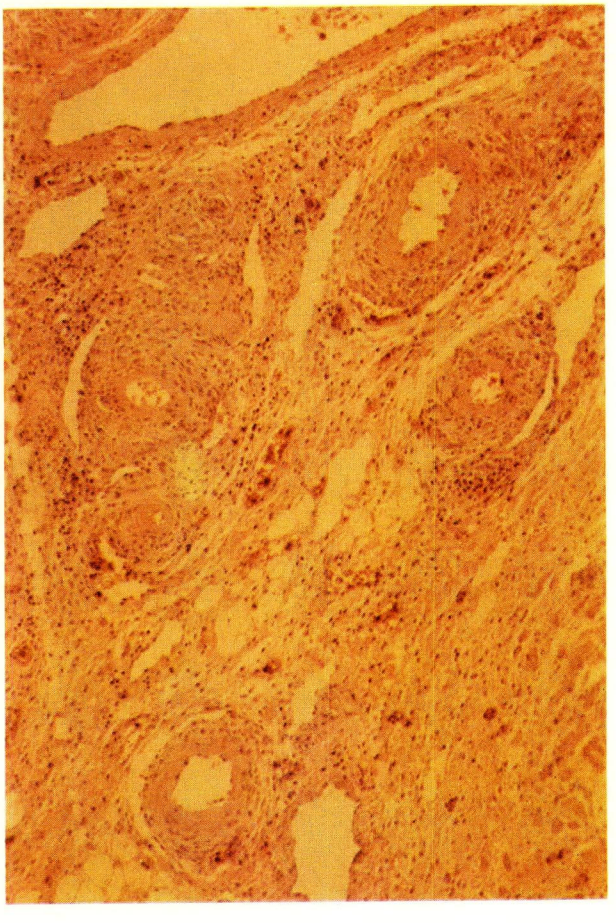

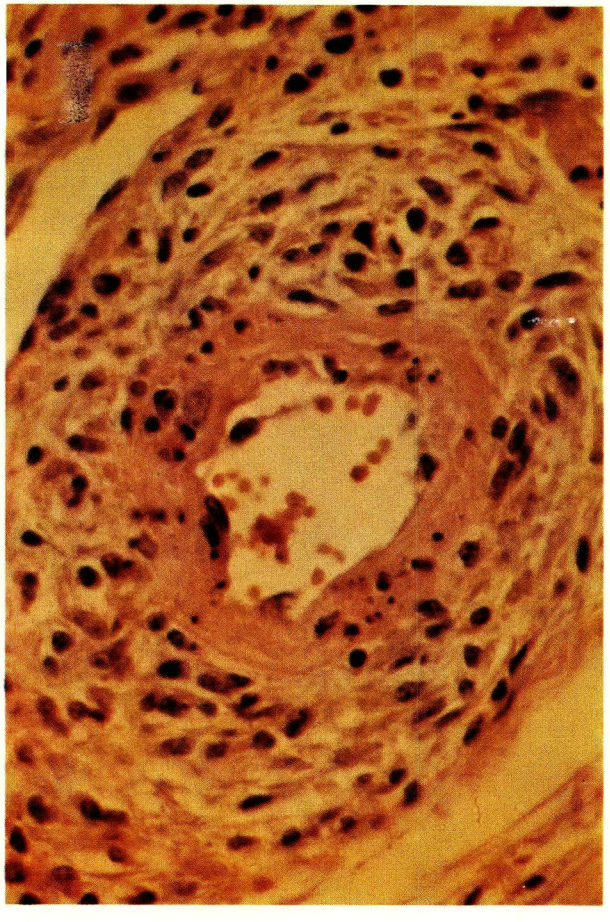

PLATE 401: MICROANGIOPATHY (MAP)

The small arterioles in the heart of this piglet show a well marked pink thickening of the endothelium, a form of fibrinoid degeneration. The lesions seen in these small vessels (microangiopathy) are from a Vit E/Se responsive disease case. Other lesions in pigs include hepatosis dietetica and nutritional muscular dystrophy. Similar lesions may be seen in edema disease of pigs.

PLATE 402: PERIARTERITIS NODOSA

Scattered throughout both kidneys of this pig are many small foci with thickened arterioles, varying numbers of chronic inflammatory cells around each of them, and a varying amount of increased adventitia. As in other animals, the cause is not known. It is a very uncommon lesion in animals.

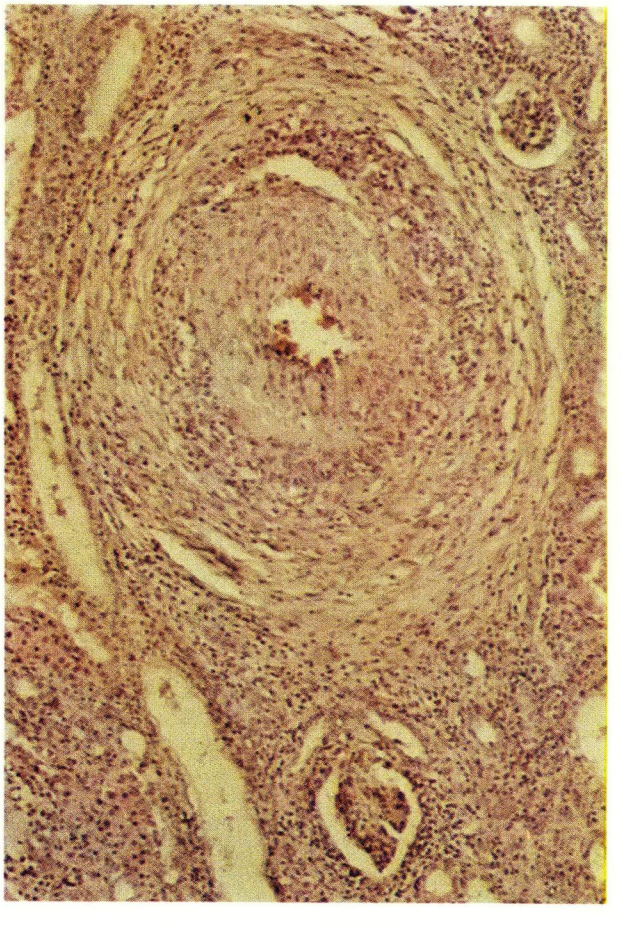

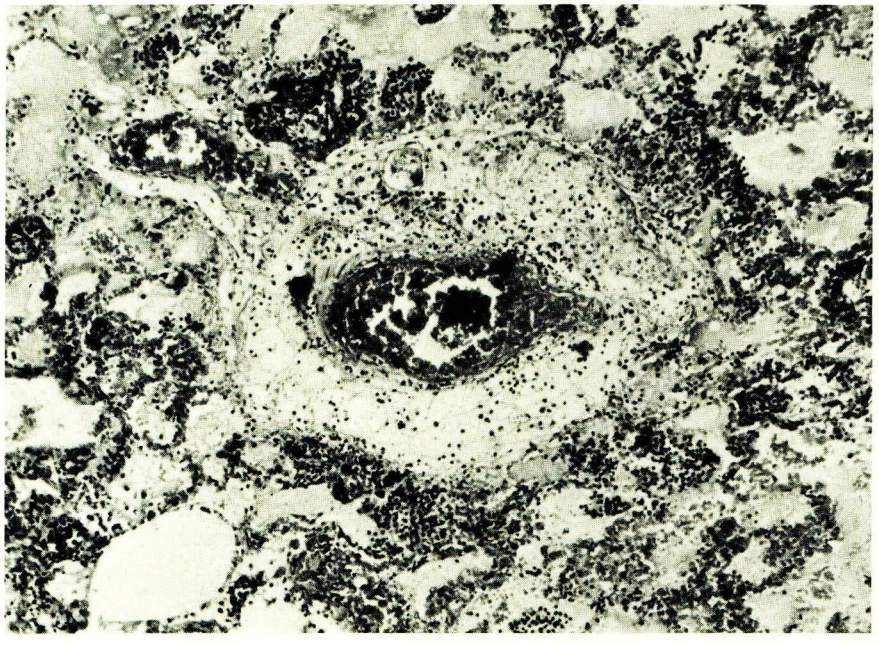

PLATE 403: PERIVASCULAR EDEMA

The large area with fibrin strands and inflammatory cells about this pulmonary vessel is an example of edema. Much clear fluid, also edema, and inflammatory cells are present in the alveoli in this case of Hemophilus parahemolyticus pneumonia. Such a lesion could be seen in almost any pneumonic process.

PLATE 404: VASCULAR HEMORRHAGE

Hemorrhages in the major vessels leaving the heart are diagnostic of bluetongue, a virus disease of sheep and other animals. They may also be found in bleeding diseases such as Vit K deficiency or dicumarol poisoning in many species.

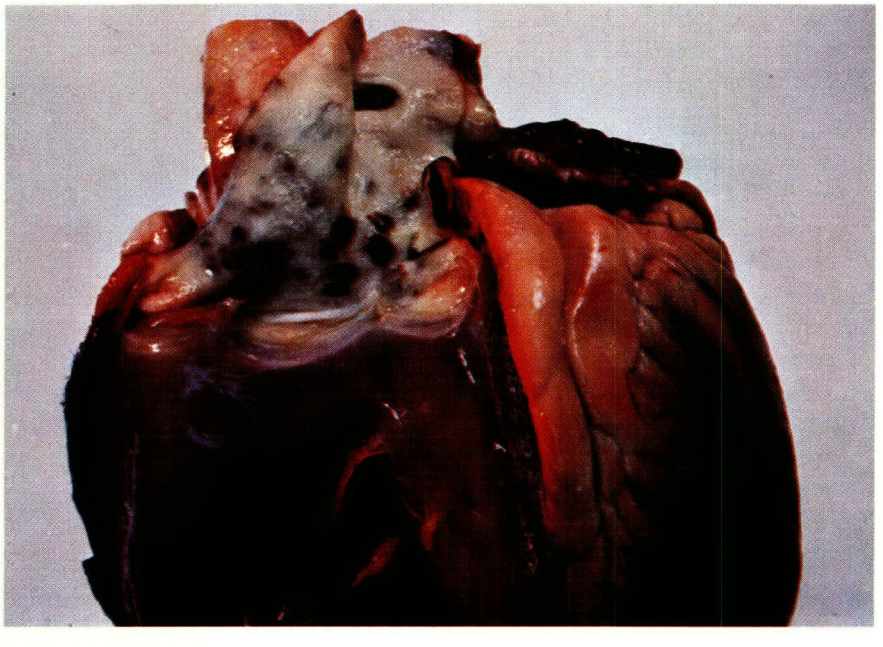

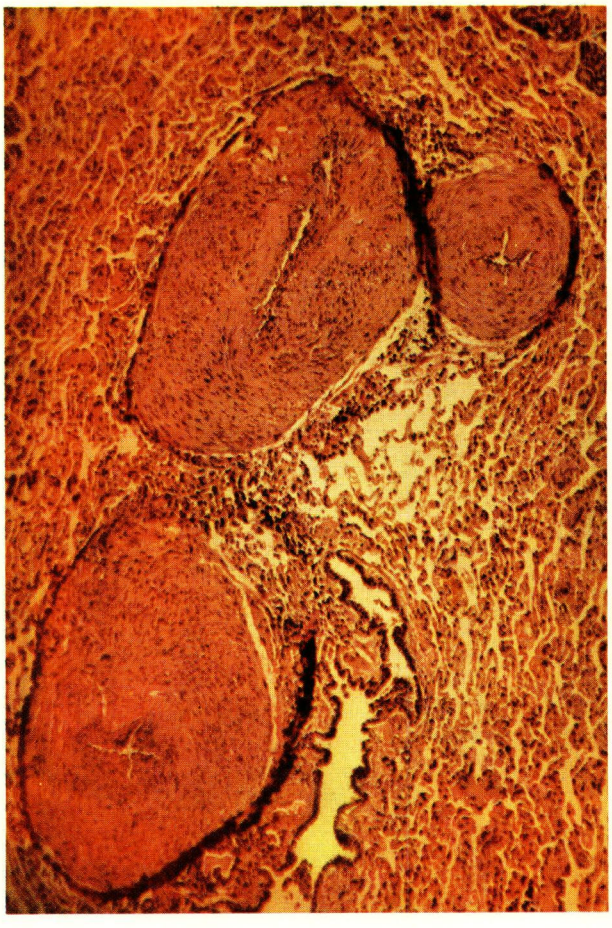

PLATE 405: MEDIAL HYPERTROPHY

The three muscular arteries near a normal bronchiole in this cat's lung are 5-10 times thicker than normal with both hyperplasia and hypertrophy of the tunica media. At one time this lesion was almost considered pathognomonic for the cat lungworm, Aelurostrongylus abstrusus, but it has since been recognized that other parasites can also cause this lesion. It is seen in ferrets, rabbits, rats and other animals.

PLATE 406: VERMINOUS ARTERITIS

The initial portion of this horse's aorta shows three, small, pale grey, shiny surfaced, firm appearing nodules attached to the endothelium. It also shows two slightly larger masses which are redder, and one has been opened to show the granular necrotic center. In time, these two would also be covered by endothelium and would shrink down to look like the other three. These nodules were caused by the strongyle, Strongylus vulgaris. Both openings of the coronary vessels can be seen in the immediate area, and one can understand why the horse has so many infarcts in its heart as a result of these parasites. The vascular lesions caused by this parasite are more common in the cranial mesenteric artery.

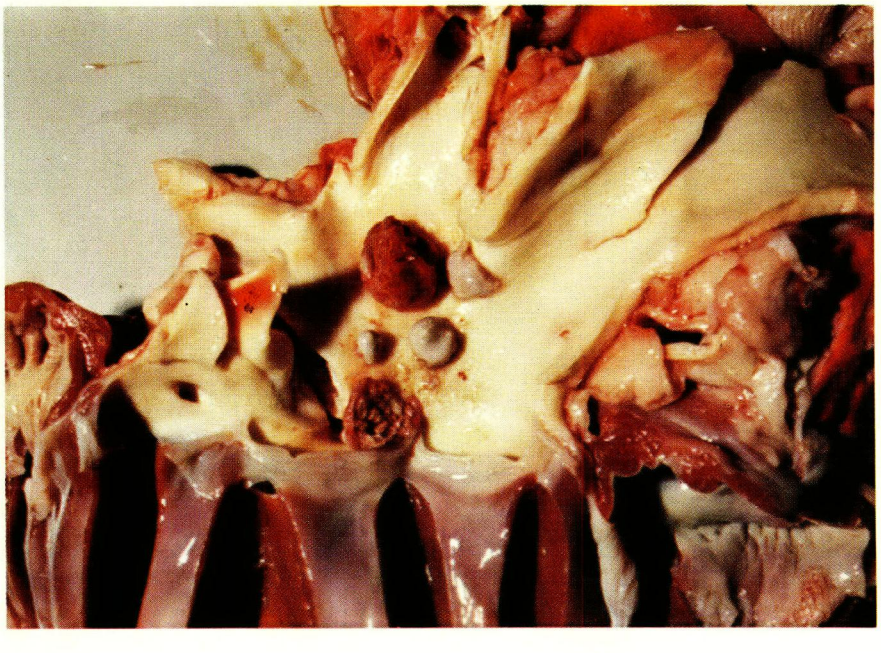

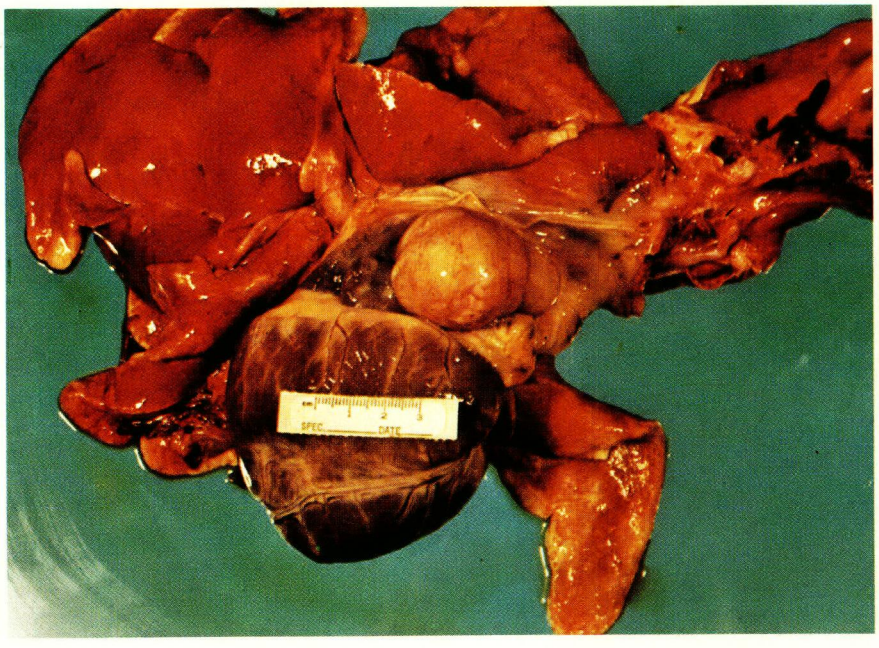

PLATE 407: AORTIC BODY TUMOR

The 3 cm. round mass at the base of this dog's heart is an aortic body tumor. It should not be called a heart base tumor except anatomically for there are several neoplasms that are commonly found in this general vicinity. Smaller tumors of this type are more difficult to see, but will usually be found in the soft tissue between the aorta and pulmonary artery. This tumor and the carotid body tumor, found near the bifurcation of the common carotid artery, belong to the chemoreceptor group of tumors. These neoplasms are often discussed with the adrenal medullary tumors.

PLATE 408: TRYPANOSOMIASIS

Mixed in with many red blood cells and a few smudged white blood cells are numerous flagellated, single celled parasites, Trypanosoma evansi. These may be found in normal animals.

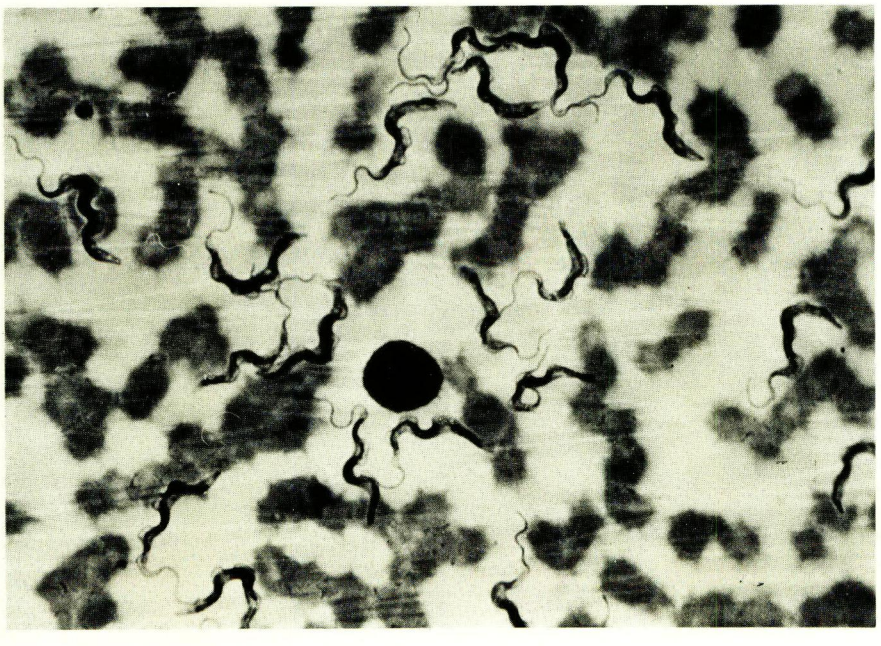

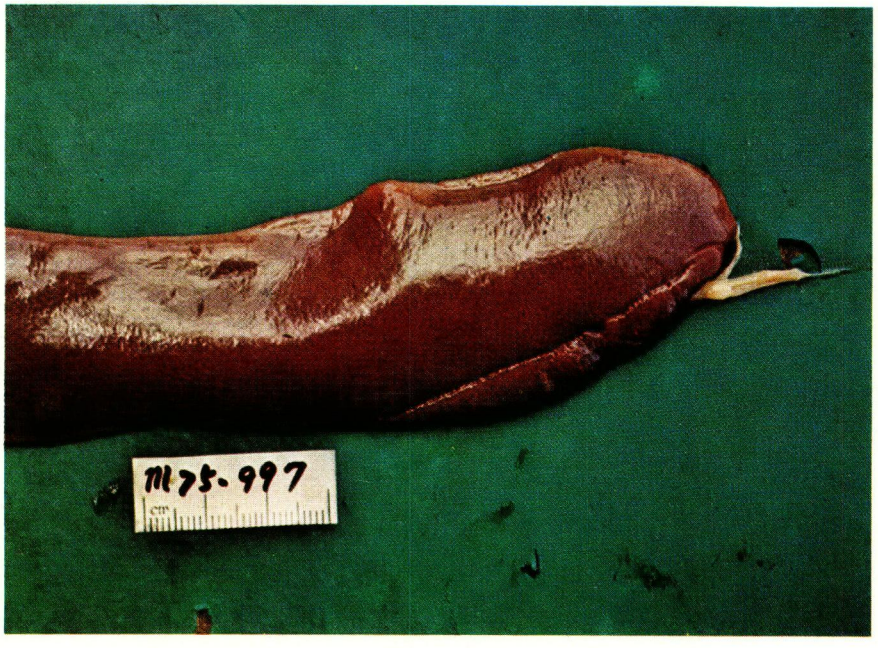

PLATE 409: NORMAL SURFACE FOLD

Along one edge, the spleen has folded upon itself. No reaction is seen to this as it is a normal finding. This is a moderate folding. Others may be much smaller or much larger. Horses often have congenital depressions on their splenic surfaces as well as fibrous tags of unknown etiology.

PLATE 410: SPLENOMEGALY

The enlarged spleen is contrasted with a spleen from a normal, similar sized pig. There are several major causes of an enlarged spleen. The "anesthetic spleen", or more commonly called "nembutal spleen", is swollen with blood which drains from the spleen when cut. Agents other than nembutal can cause this. Severe, acute bacterial infections also cause splenomegaly which is soft and somewhat blood filled, but much blood does not escape from its cut surface. Chronic infections, especially of the blood destructive protozoa, cause a swollen, firm spleen which is not bloody. Neoplasms of the vascular or blood cell types often cause extreme splenomegaly, which may be a leading factor in causing death by exsanguination when they rupture. This was a case of an acute, severe bacterial infection in a piglet.



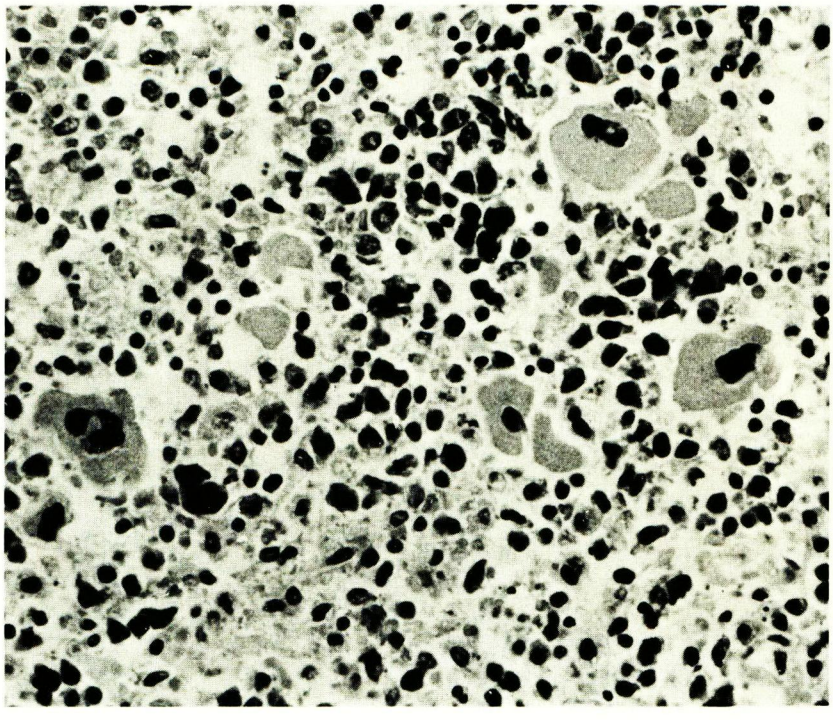

PLATE 411: EXTRAMEDULLARY HEMATOPOIESIS

The several large cells in this section from a swollen spleen suggest that the spleen is compensating for blood loss or destruction. The large cells are megakaryocytes and the compensatory hyperplasia of these and other blood cell precursors are in response to a chronic bleeding ulcer in this pig. Baby pig anemia cases caused by iron deficiency may also have this lesion. While present in the spleen and other tissue in embryonic life, these cells disappear when blood formation is taken over by the bone marrow, which is shortly after birth in most species.

PLATE 412: NODULAR HYPERPLASIA

The cut piece of this weanling pig's spleen shows an essentially normal triangular area of spleen both above and below a bulging, soft fleshy round mass of soft tissue. Several areas of hemorrhage or congestion are in the mass proper. Histologically, the mass is hyperplastic lymphoid tissue. It is a relatively common lesion of the spleen in most young animals. Its differentiation from a benign neoplasm, especially in older animals, is not easy.





PLATE 413: SPLENIC IMPLANTATION

The spleen has been traumatized and is in two distinct pieces but still attached. In the mesentery are many dark foci of tissue similar to the splenic parenchyma and are in fact "daughter spleens" from the subsequent implantation wherever the splenic tissue became attached. This lesion is usually seen in animals such as the dog and cat which are most likely to be subjected to blunt trauma as from an automobile.

PLATE 414: SPLENOMEGALY AND GASTRIC TORSION

The stomach of this pig has been twisted about 360 degrees. The attached spleen is folded towards its hilus and is extremely distended with blood. The splenic and involved omental vessels are also distended as a result of the gastric torsion and interference with blood flow. Sudden whole body movements as tumbling following food ingestion are often considered causative. In dogs, while the same causes are suspect, there is a tendencyto see this in large breed, male dogs. After death, carcass handling may cause mechanical correction of this problem, and this may make the diagnosis more difficult to determine. Gastric torsion is more common in pregnant sows than other pigs.





PLATE 415: SPLENOMEGALY

The spleen is enlarged, firm and meaty on palpation. The edges are more rounded than normal and the splenic pulp bulges from the cut surface. Acute and chronic infections can cause this especially those affecting the blood itself. Some tumors as the myeloid or lymphoid series of blood cells may cause this. An enlarged, bloody spleen is often just a terminal event, notably when the animal is killed with an overdose of an anesthetic, but the enlargement would be due to blood engorgement and not parenchymal hyperplasia as in this case of trypanosomiasis in a pig.

PLATE 416: PSEUDOINFARCT AND SIDEROTIC PLAQUES

The two dark blebs (pseudoinfarcts) of one dog's spleen are areas of congestion associated with the blood trapped at this site when the blood from the rest of the spleen was differentially expelled by splenic contraction. This is commonly seen when animals, especially dogs, are anesthetized for euthanasia. Along the edge of the other spleen are several yellowish green, firm, plaques (siderotic plaques). These yellowish green deposits are also common in the hilar area in and around the major veins of the spleen. It is thought that the siderotic plaques are the sequelae of the pseudoinfarcts with hematoidin, hemosiderin, minerals and other degenerate products of chronic blood stasis deposited in these areas along with some reactive fibrosis.



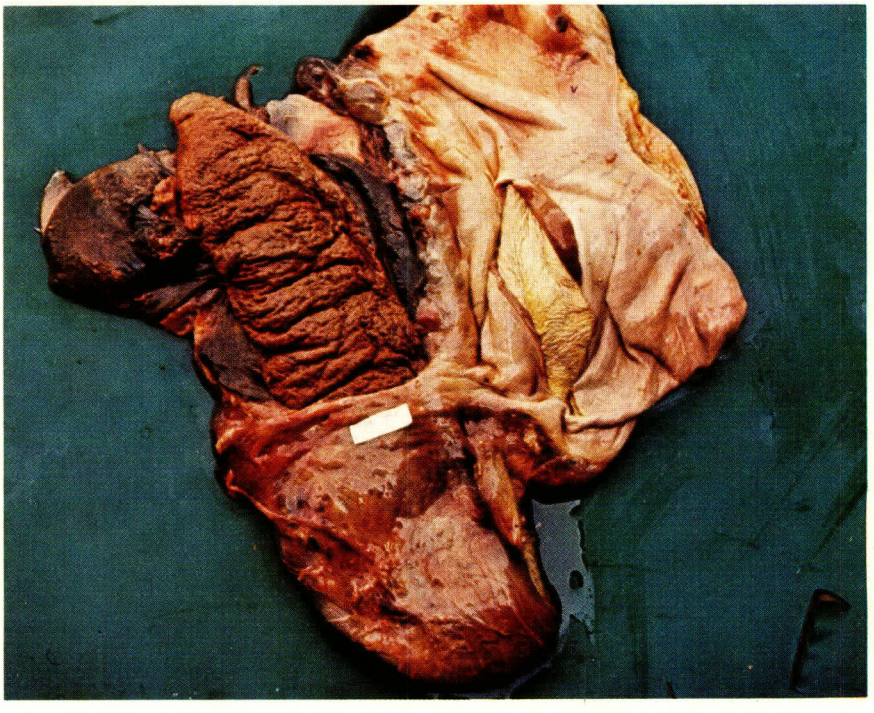

PLATE 417: SPLENIC INFARCTION

The brown splenic shaped mass is indeed the spleen itself, and it is completely infarcted. It is in a pocket of a greatly thickened serosal capsule of which one half has been opened to show the necrotic spleen. The large soft tissue mass to one side is the attached stomach. Much bloody debris was in this sac with the necrotic spleen and has stained the lining dark red. One can suppose the cause of this lesion to be one of splenic torsion at the time of sudden body turnover.

PLATE 418: SPLENIC INFARCTION

A completely necrotic spleen has been removed from and placed beside a partially opened pocket of a greatly thickened serosal capsule attached to the stomach which has a clean cut into its lumen as seen here. Much bloody fluid and debris was also in this sac holding the spleen. Sudden whole body movement with splenic inertia may be involved in its pathogenesis.

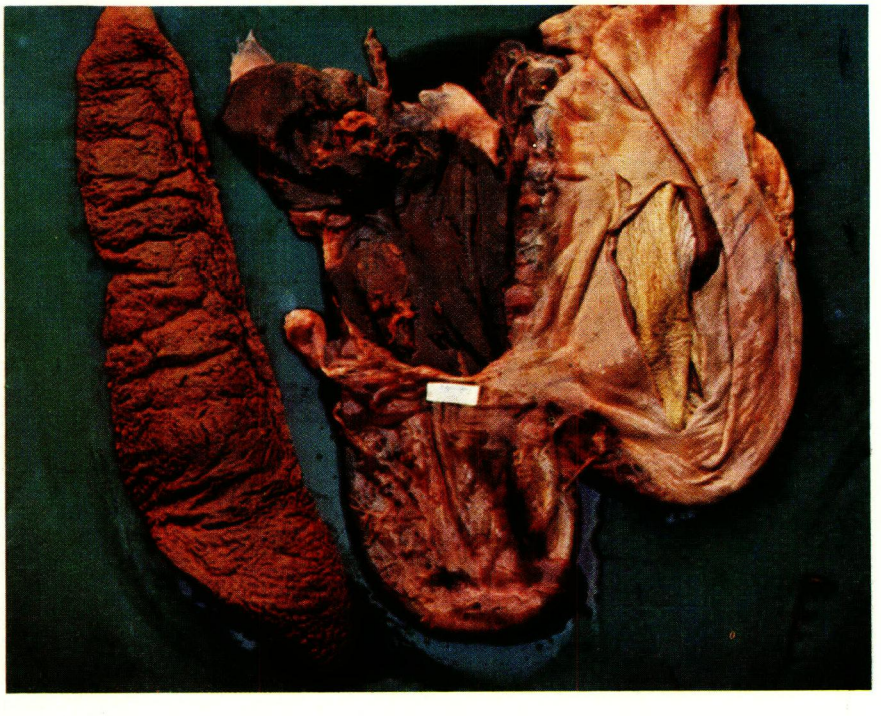



PLATE 419: SPLENIC INFARCTION

The tannish tip of one spleen is completely contracted and devoid of blood. It also has a normal surface fold commonly seen in pigs. The remaining major portion of spleen is swollen, firm and has a dull appearance on its cut surface. This is the infarcted area. A knife cut is present through it and a small hematoma is on its concave edge. The other spleen is from a much larger normal pig to show the difference in spleen size. This normal spleen has a dark area of pseudomelanosis just opposite the knife cut. The cause of the hematoma and the infarction is unknown, but the pig also had a gastric ulcer.

PLATE 420: SPLENIC INFARCT

The cellular area is essentially normal splenic tissue with the bloody area being markedly dilated with ruptured, sinusoid walls in the area of infarction. The pink amorphous area is an accumulation of fibrin around some stromal tissue. A vascular lesion, as from an embolic shower, should be a prime suspect.

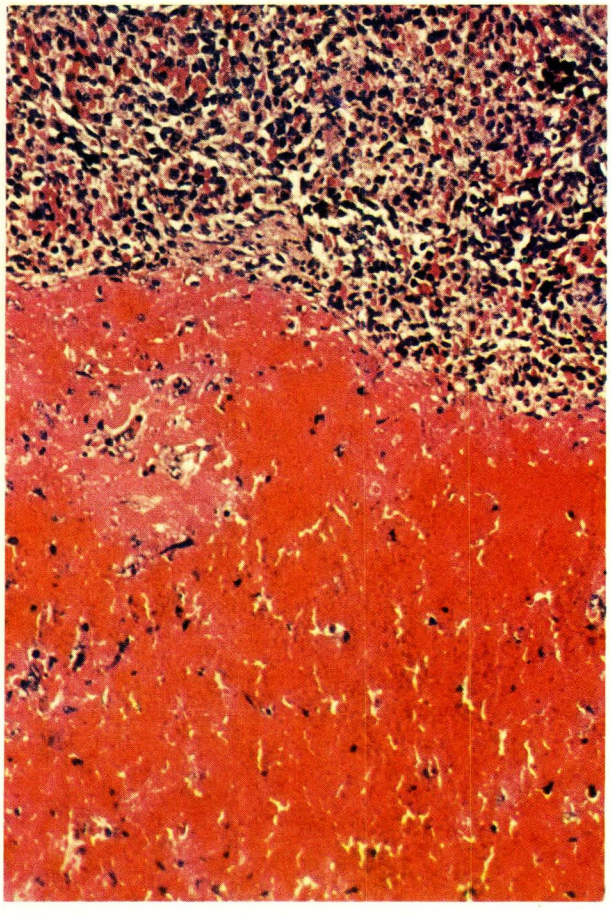

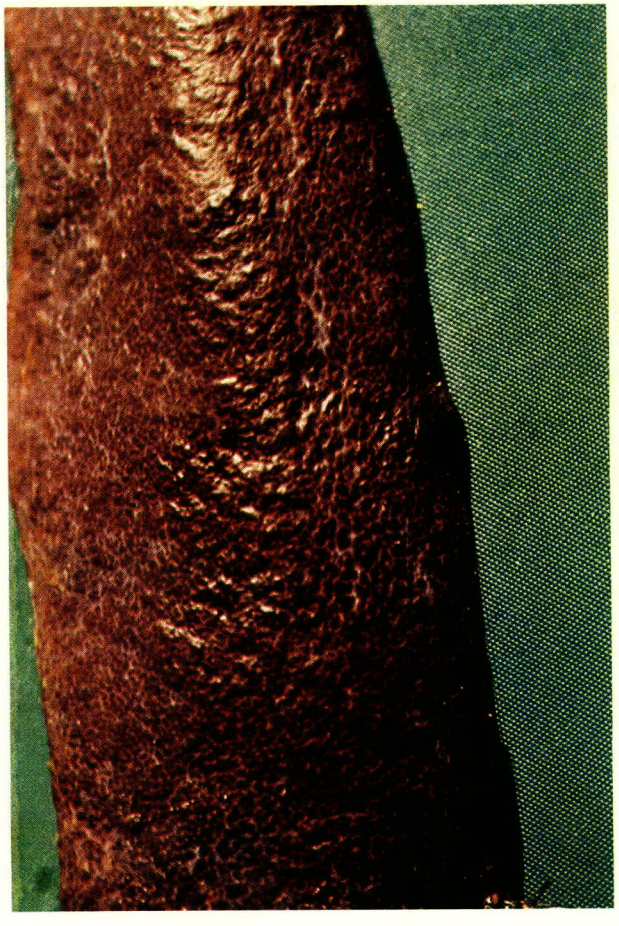

PLATE 421: SPLENIC INFARCT

The 5 mm. dark focus about midway on the edge of this spleen is a typical infarct of hog cholera. Often they are multiple and large, but this was the only one in this spleen. Its pathogenesis is partially explained by the virus causing endothelial damage leading to thrombosis and thus infarction. These must be differentiated from infarcts of swine erysipelas in which an embolic shower from a vegetative endocarditis causes the infarcts.

PLATE 422: ENDOTHELIAL PROLIFERATION

This splenic vessel shows well marked endothelial proliferation. When seen, this lesion is helpful in making a diagnosis of hog cholera.

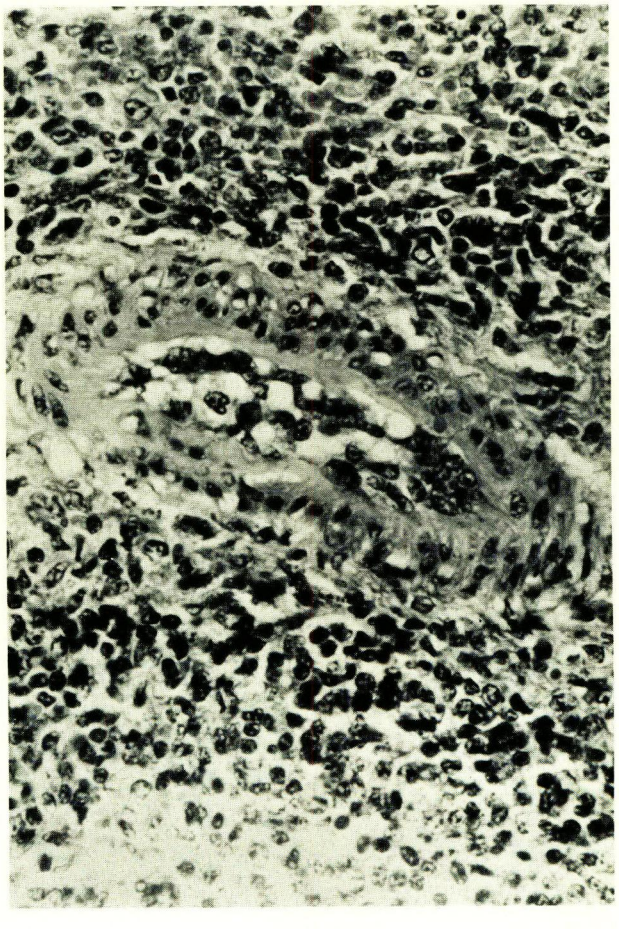



PLATE 423: HEMATOGENOUS ABSCESSATION

These multiple, elevated, yellowish red nodules are abscesses associated with a showering of the spleen with organisms and their subsequent growth there to grossly visible abscesses. While some might call these infarcts, it is doubtful if they should be called that as there is no evidence of necrosis in these areas prior to the abscess formation. Numerous organisms such as Streptococcus spp. Staphylococci spp. and C. pyogenes may be isolated from such cases.

PLATE 424: RETICULOENDOTHELIAL PROLIFERATION

The half round area with many small dark round cells is a germinal center in this spleen. The two other concentric areas of small cells with finely granular cytoplasm are foci of reticuloendothelial (RE) proliferation in the red pulp areas. Many other RE cells are scattered around these nodules. This is a case of splenomegaly caused by chronic trypanosomiasis. These nodules are also called "immune sites" as apparently they are seen frequently in chronic cases of many infectious diseases.

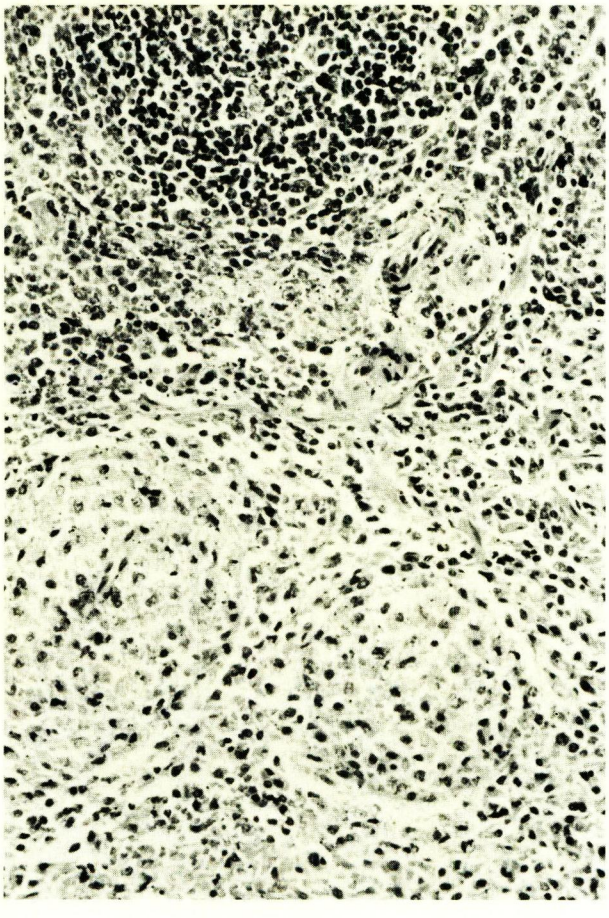



PLATE 425: THYMOMA

This 6-8 cm. firm, multilobular mass was located in the anterior dorsal mediastinum at the base of the heart. No other related lesions were seen in this five month old pig. Histologically, it was a small round cell tumor, with the cells similar to, if not actually, lymphocytes. Several Hassal's corpuscles were found in these sections. Disagreement exists, but cannot be resolved here, that this could be lymphomatosis affecting the thymus. This should probably not be called a "heart base tumor" any more than a tumor at the base of tail should be called a "tail base tumor".

PLATE 426: THYMOMA

This was part of a large mass in the region of the thymus. It consists mainly of small round cells of the lymphoid series mostly mature lymphocytes. A single Hassal's corpuscle is also shown, but by itself, it does not prove it is a thymic tumor. It could be a remnant of the original normal tissue. This tumor could also be called lymphomatosis of the thymus. Much discussion often is involved in such a case.

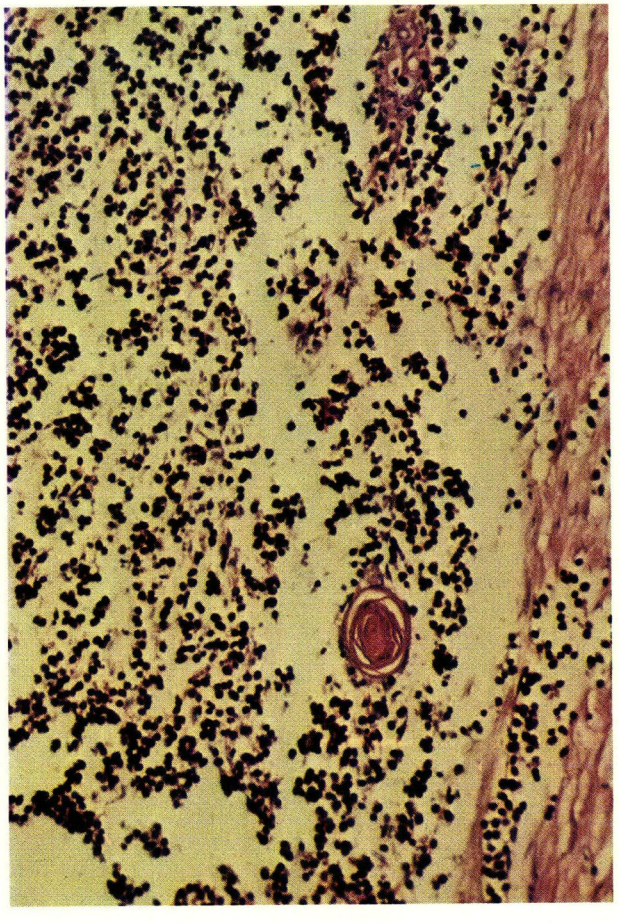

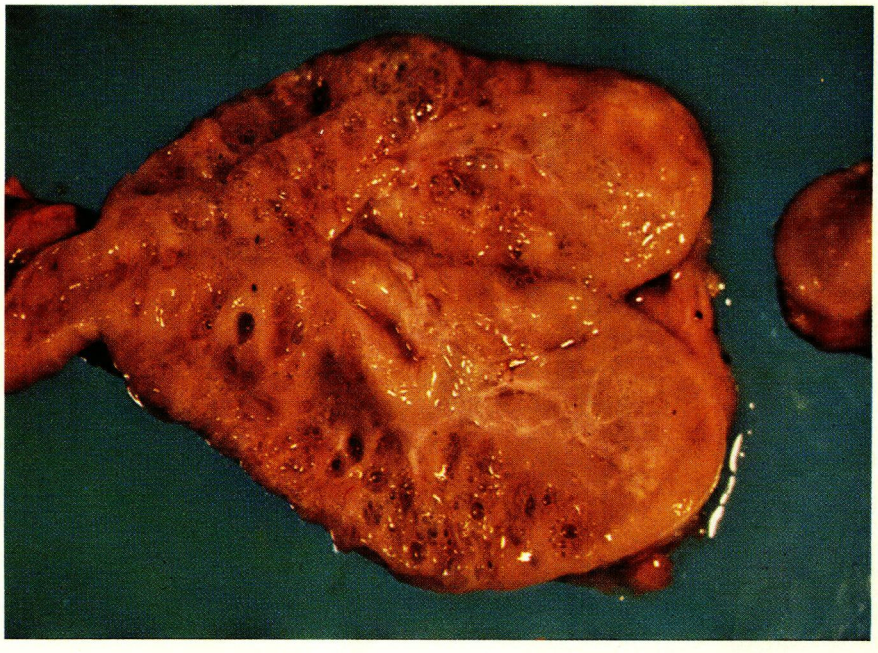

PLATE 427: EMPHYSEMA

The cut surface of this node shows numerous gas pockets with no appreciable host response. This is a bronchial lymph node draining a lung with marked chronic pneumonia and emphysema. While most such cases of node emphysema are associated with chronic pneumonia and emphysema, it also occurs in cases of terminal pulmonary emphysema, especially in cattle.

PLATE 428: EMPHYSEMA

Bubbles of gas without appreciable host reaction are scattered in the sinusoids of this node. In many cases, the bubbles may be within giant cells (foreign body giant cells) as they are indeed foreign bodies. Those in the bronchial nodes and other nearby nodes in cases of pulmonary emphysema have probably migrated there via lymphatics after the air bubbles escaped from the ruptured alveoli into the interstitial tissue proper. The source of the bubbles in cases of intestinal emphysema is not definitely known.





PLATE 429: PERIPHERAL HEMORRHAGE

The dark red peripheral zone of this lymph node is often the basis for the misdiagnosis of hog cholera. While seen in hog cholera, it is not diagnostic for it alone. In this case, a severe septicemia was present, but not hog cholera. Any acute area of hemorrhage draining to these nodes could cause such a lesion. Even a terminal traumatic lesion could be causal.

PLATE 430: AMYLOIDOSIS

This hyaline material, amyloid, in scattered deposits in this node, or in any organ, often near the basement membrane of vessels, is pink and homogeneous in H & E stained sections. While many cases of amyloidosis are secondary to chronic infectious or inflammatory processes (secondary amyloidosis), this case can be considered "primary amyloidosis" as no other chronic or even acute disease process was present in the carcass.

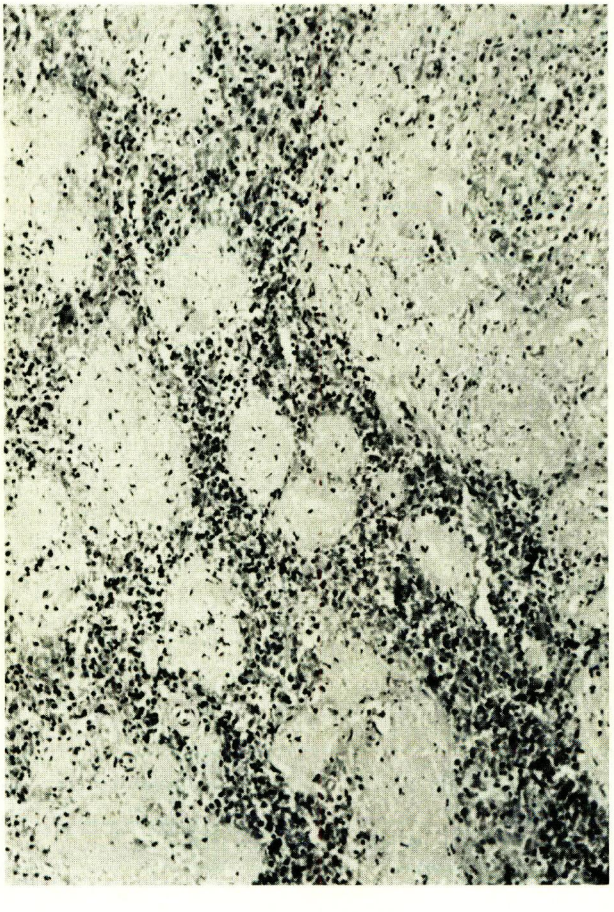

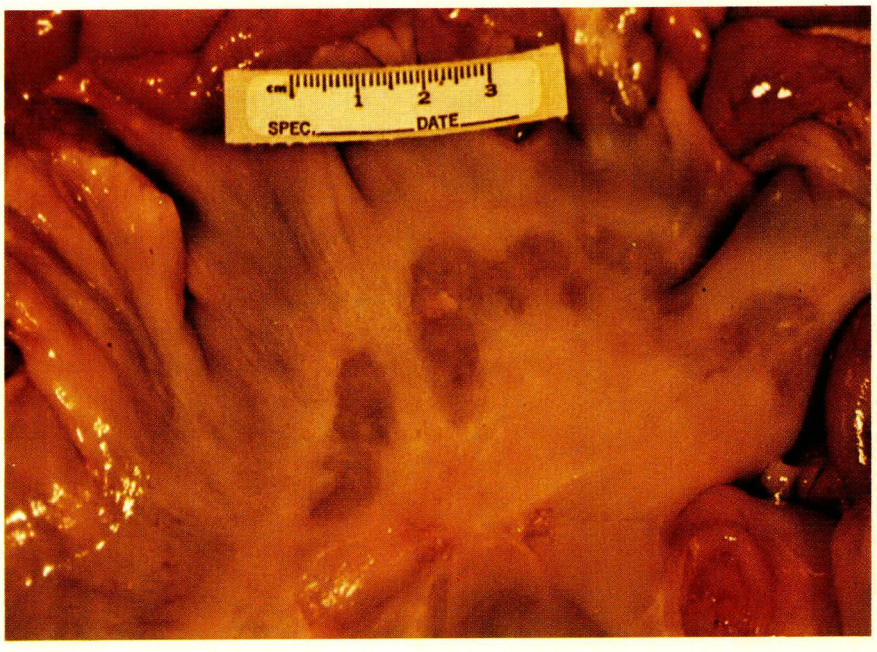

PLATE 431: FOCAL NECROSIS

This single, just visible, yellow focus in a mesenteric node was firm on palpation and was the only lesion in this tuberculosis (TB) positive pig. By itself, it is just an area of focal necrosis and abscessation. Many organisms and even wandering parasites might make such a lesion. Typical giant cells and acid fast organisms were found histologically.

PLATE 432: MULTIFOCAL NECROSIS

These multiple yellowish foci in a node are firm. Some debris can be expressed from them when cut. They are the only lesions in this TB positive sow. Other bacterial agents and even wandering parasites can cause such a lesion. There were typical giant cells and acid fast organisms found histologically.

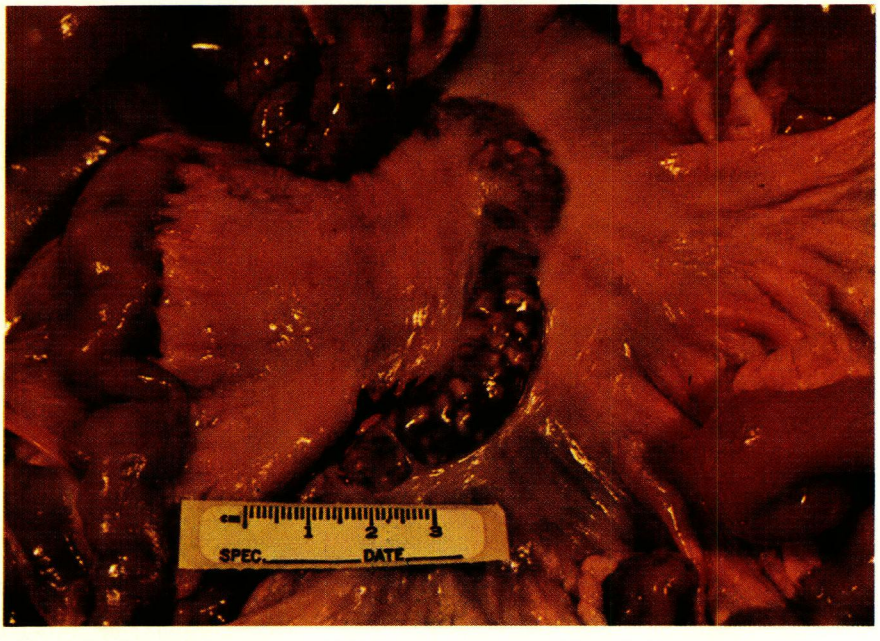

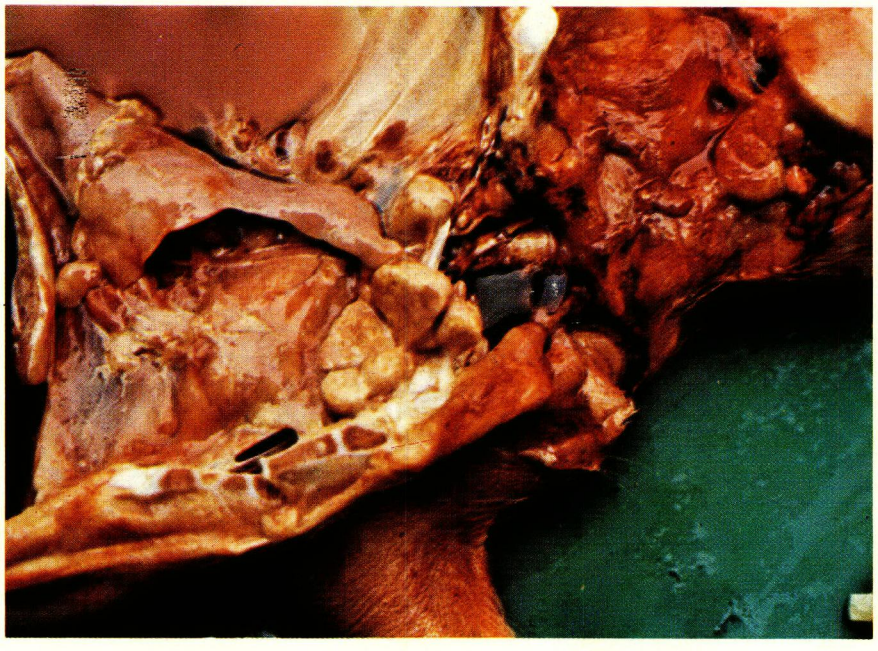

PLATE 433: LYMPHADENOPATHY

The greatly enlarged mediastinal nodes are similar to those scattered throughout the body. Some nodes were abscessed. This pig also had pleuritis and peritonitis. The enlarged nodes are reactive with both lymphoid elements and neutrophils, as a response to a severe septicemia and bacteremia. Such a case, if extremely prolonged, may result in atrophy secondary to exhaustion or chronic abscessation of the nodes. Any one of many agents may be involved including toxoplasmosis. The term lymphadenopathy is nonspecific just indicating that some disease process is present, but not designating any specific type.

PLATE 434: LYMPHADENOPATHY

The dorsal mediastinal and bronchial nodes of this piglet are markedly enlarged with hypertrophy and hyperplasia. The animal had a virulent infection causing pleuritis with sheets of fibrin on the lungs. Other processes such as a neoplastic process can also make enlarged nodes (lymphadenopathy). The term is not diagnostic by itself. While this was a bacterial disease, enlarged nodes are also common in the many chronic granulomatous infections caused by protozoa and fungi.



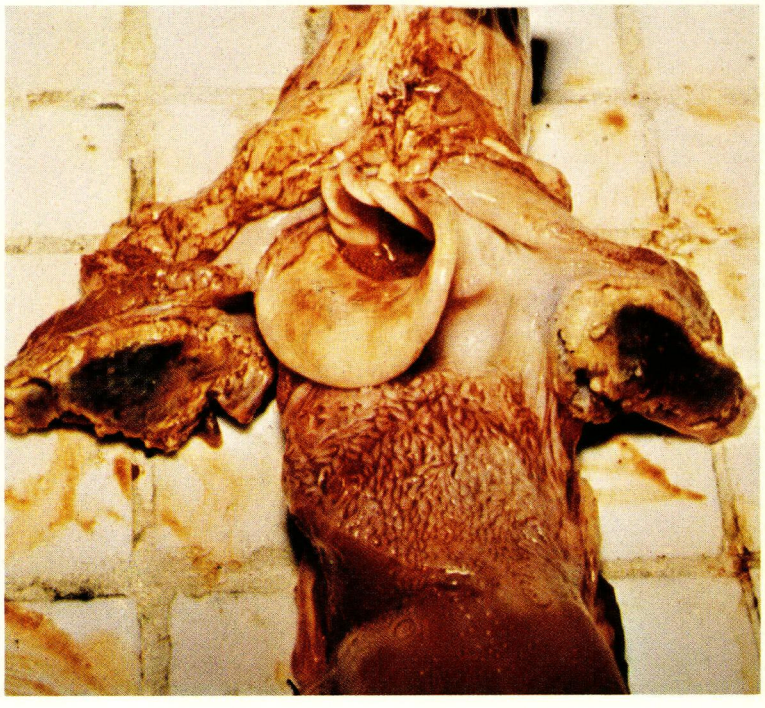

PLATE 435: TONSILLAR NECROSIS

The two, large, yellowish masses with a flat greenish surface are the tonsils with marked enlargement caused in this case by Pasteurella spp.. The appearance here suggests that a core like structure could almost be peeled out of these tonsillar crypts. Other organisms as S. necrophorus are also likely candidates to cause such a necrotic lesion.

PLATE 436: MYCOTIC TONSILLITIS

Several hyphae are present in this necrotic focus of tonsillar tissue. The hyphae are septate and branching. While not seen here, thrombosis is a common finding in mycotic infections. Aspergillus spp. was isolated from this case. Often it is confused with Mucor spp., another mold commonly found in animals. One should consider carefully if such a finding is a real infection or a contaminant. In animals, many cases are associated with heavy antibiotic use especially in feeds.

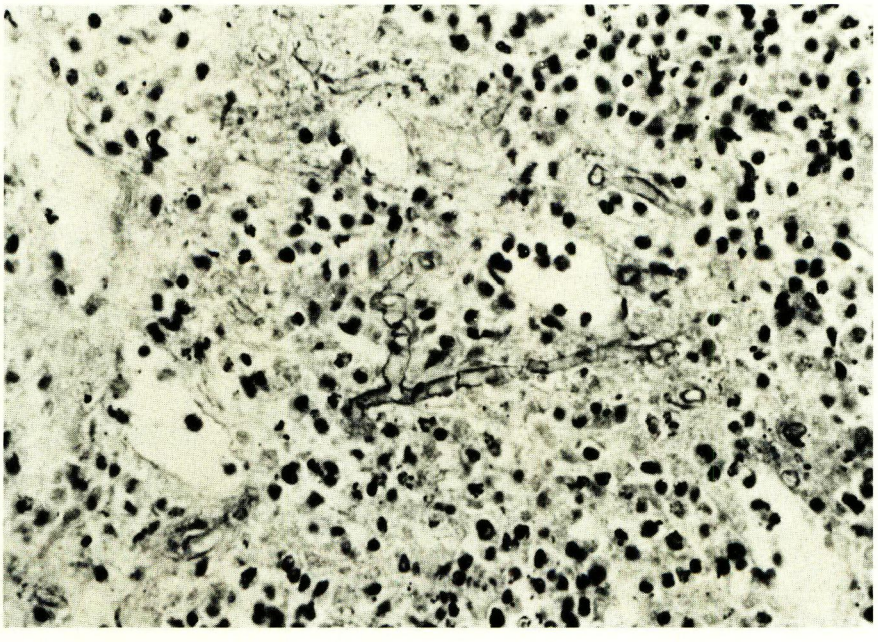



PLATE 437: TOXOPLASMOSIS

This enlarged, firm, mottled, pale and red hepatic lymph node has lost its normal cortex-medullary architecture. It is about 4 times normal size as a result of necrosis from toxoplasmosis. It represents a type of "lymphadenopathy" which is a term for a nonspecific reaction of a lymph node to inflammation. Histologically, it consisted of coagulation necrosis with many Toxoplasma gondii organisms. Other infectious processes could also cause this lesion, but along with a diffuse pneumonia in a pig or any species, one should first suspect toxoplasmosis.

PLATE 438: COAGULATION NECROSIS

This lymph node was about four times normal size and associated tissues were edematous from lymphatic blockage. The liver had typical areas of focal necrosis grossly that apparently showered the draining lymph nodes with toxic debris and Toxoplasma gondii organisms.

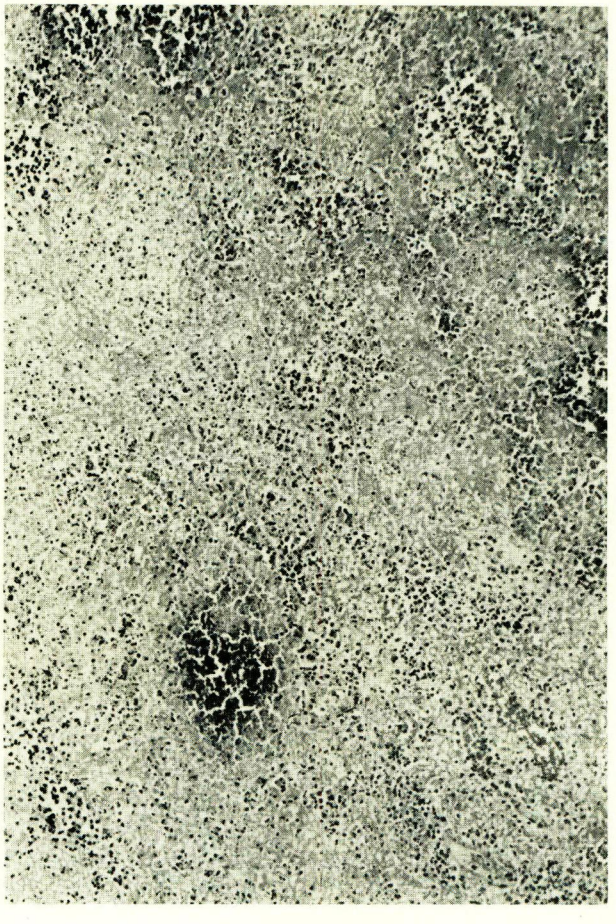

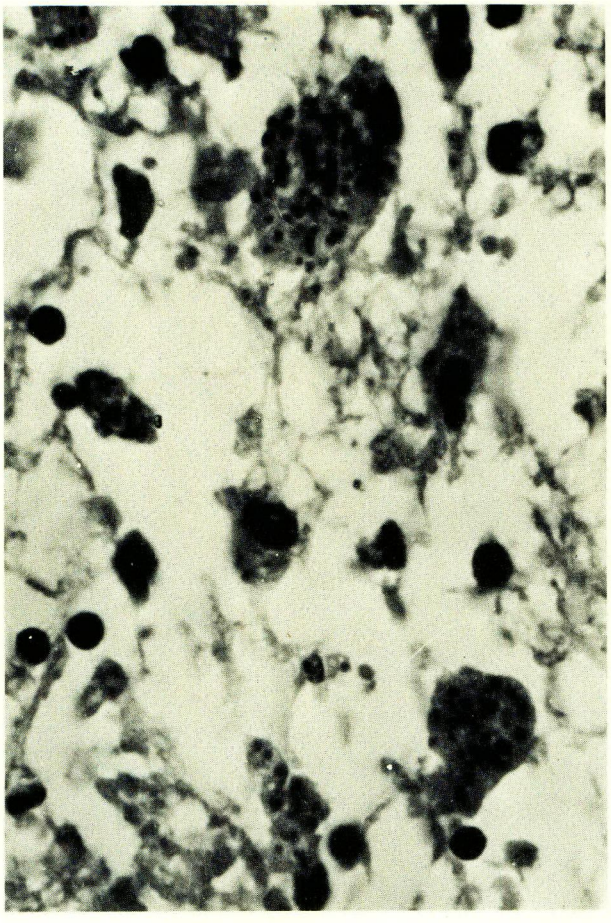

PLATE 439: TOXOPLASMA PSEUDOCYSTS

The two large masses and several small ones with dark bodies in them, with each small dark body separated from each other by lighter material, are pseudocysts containing the smaller dark individual organisms of Toxoplasma gondii in this section of lymph node.

PLATE 440: LYMPHOMATOSIS

The uniform, round, bulging masses protruding from the tonsillar crypts in this dog are areas of lymphoid neoplasia. Other nodes were also involved. With smooth enlarged tonsils, one should think of this disease, but if the surface is rough and ulcerated, in addition to being enlarged, one should also consider a squamous cell carcinoma.



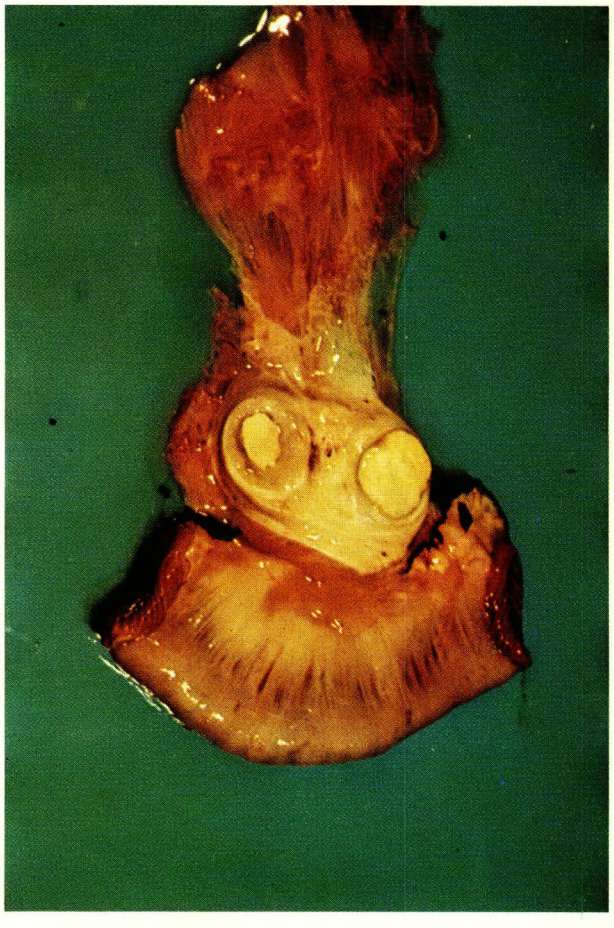

PLATE 441: TUMOR NECROSIS

The two dull yellowish areas in these swollen lymph nodes in the mesentery near this cow's intestine are areas of tumor necrosis. The lymph nodes are swollen as a result of lymphoid neoplasia (lymphomatosis). The neoplasm has grown so fast that it outgrew its blood supply and the central portions became infarcted. Compression of nutrient vessels may also have played a part in causing the death of the tumor cells. The normal paired nature of the mesenteric nodes is demonstrated here.



PLATE 442: NORMAL FIMBRIA

One tongue is what is usually considered normal and the other has many finger like, fleshy projections (fimbria) along its side and anterior border. These are seen in a number of normal piglets and apparently wear off soon after birth leaving no residual evidence of their once being present.

PLATE 443: SUPERFICIAL MYCOTIC GLOSSITIS (THRUSH)

The dorsal surface of this tongue has a thickened, rough, dry appearance. No inflammatory reaction is apparent. While this is a horse tongue, it is common in other species. It is especially common in the esophagus. Species of Aspergillus spp. or Candida spp. can most often be isolated. Animals off feed for a period of time are most prone to this condition.

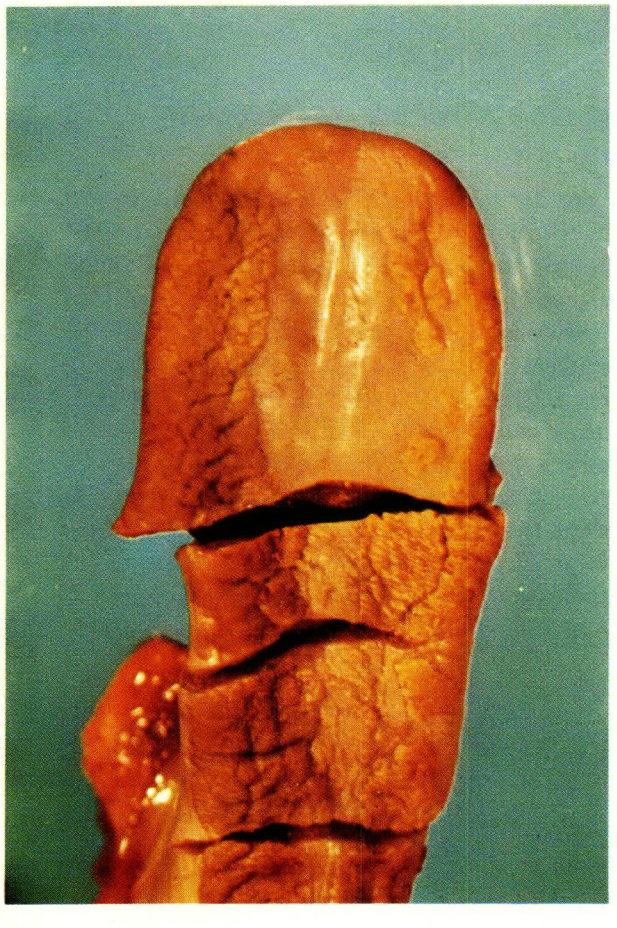

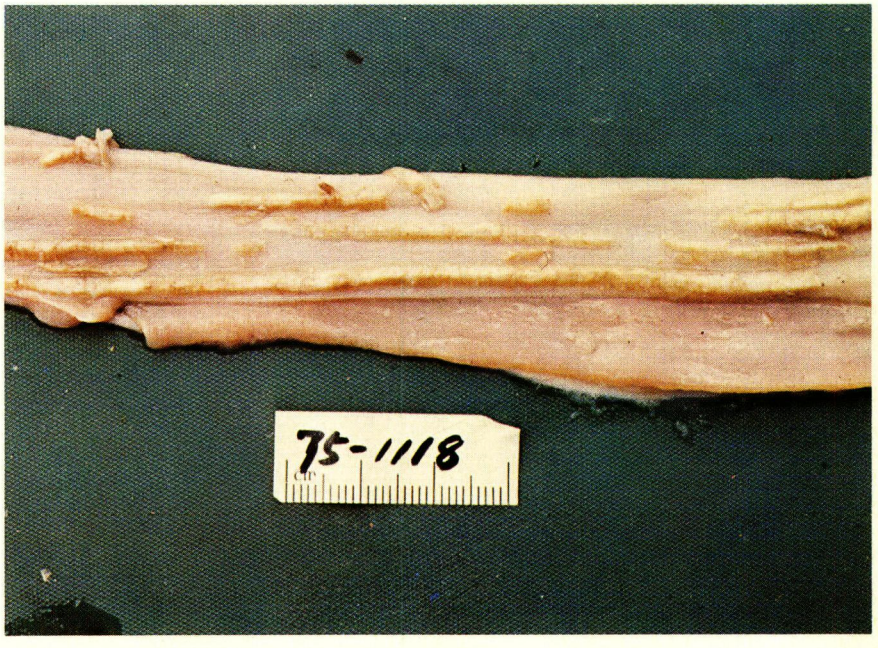

PLATE 444: THRUSH (CANDIDIASIS, MONILIASIS)

The esophagus of this piglet has several linear, rough, dry plaques of material attached to the mucosa. They can be scraped off with ease and no inflammatory response is apparent. In some cases, the entire surface of the mucosa is covered, especially at its distal end. It is also a common lesion on the dorsal surface of the tongue. It is usually associated with an animal that has been sick and off feed for some time.

PLATE 445: THRUSH (CANDIDIASIS, MONILIASIS)

Large numbers of small round bodies (blastospores) of the mold are present, scattered individually or in clumps in the outer layers of the epithelium, especially the keratin layer of this pig's esophagus. While most of the large bodies are nuclei of the epithelial cells, some may be inflammatory cell nuclei. This infection is on the surface without much host reaction. Grossly, it is a thick dry deposit (pseudomembrane) adherent to the tongue or esophagus. The lesion varies from a dull, pale white to ingesta or even the bile stained color from vomition. Many cases are associated with prolonged anorexia often with antibiotics involved.

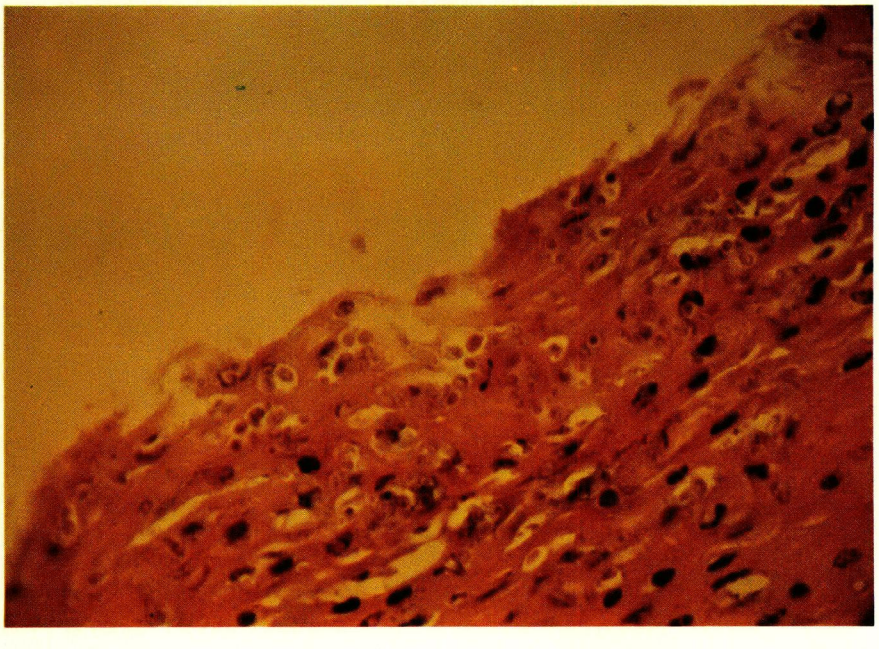



PLATE 446: ESOPHAGEAL RUPTURE

The distal portion of this pig's esophagus has a linear tear with food leakage into the surrounding soft tissues. The gastric mucosa is bile stained. Only a moderate inflammatory response is present in the surrounding tissues suggesting that this had ruptured only a short time before death. As no biological cause was found, a search for a mechanical one such as a piece of glass was made, but none was found. This is a separate disease entity different from that of gastric ulcers.

PLATE 447: FOREIGN BODY PERFORATION

The incriminating piece of wire, its ragged hole and the attached clot of blood and debris that formed about the wire in the lumen of the esophagus is pictured here. The sharp, not curved end of the wire, had penetrated the esophageal wall and formed a large abscess with a 3 mm. connective tissue capsule under the esophagus. The wire and abscess then proceeded to erode the wall of the left carotid artery. This subsequently ruptured into and out of the abscess pocket and finally into the esophagus proper actually bleeding the pig to death. With foreign bodies, as with trauma, the most unexpected may happen. Cats and dogs often ingest sewing needles with thread still attached, which have a tendency to penetrate the bowel and exit the body near the kidneys. In cattle, 8-12 cm. pieces of slightly curved wire or wirelike pieces of metal often penetrate the reticulum to cause hardware disease.





PLATE 448: ESOPHAGEAL RUPTURE

The extensive, brownish green, coarse granular area is necrosis and partial digestion in the periesophageal soft tissues. It is mostly on the right side with a small area on the left side. The irregular jagged surface at the distal end of the esophagus shows where the ingesta and retrograde gastric fluid escaped. The large area of stratified squamous epithelium of the stomach was also ulcerated in this pig, and probably was the main predisposing factor in the perforation into this area. Although gastric digestion of this tissue is evident, there is a lack of localized tissue response in the form of edema and hemorrhage which suggests it had ruptured only recently.

PLATE 449: GONGYLONEMA spp.

A single worm is seen entwined in a vermiform pattern in the epithelium of this cow's esophagus. It is also seen in the esophagus of sheep and alongside the tongue of pigs. No reaction is usually associated with these. In this picture, we can also see numerous plaques of apparently swollen, raised, stratified epithelium which may represent early epithelial degeneration caused by a viral disease such as BVD (bovine virus diarrhea).



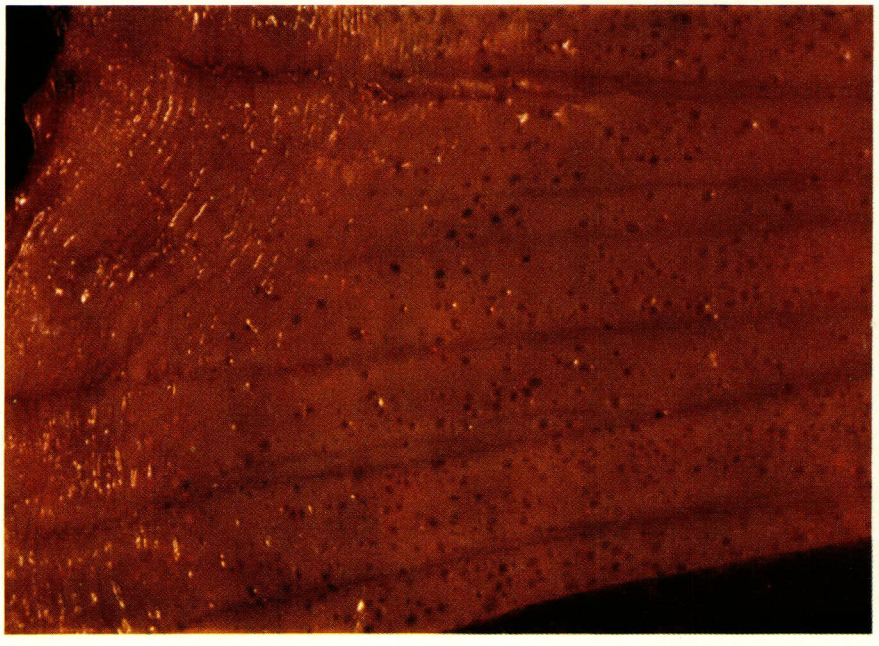

PLATE 450: CYSTIC ESOPHAGEAL GLAND DUCTS

The large number of 1-2 mm. cysts seen in the distal end of this dog's esophagus are dilated ducts of the numerous esophageal glands. They are seen primarily in older dogs and are without known significance. A few are to be seen in most old dogs. In severe cases they will be found in the proximal portion of the esophagus also.

PLATE 451: PHYSIOLOGICAL HYPEREMIA

The dark, tannish epithelium of this cow's rumen is sloughing from autolysis revealing the congested but normal underlying subcutaneous tissues. The animal was not bled out at death and the blood in the capillaries remained. There is no exudate, edema or hemorrhage present to suggest inflammation. This is commonly found in the G.I. tract and urinary bladder of most animals and is often mistakenly called a hemorrhagic inflammation. Epithelial sloughing of the rumen may occur in less than an hour after death.

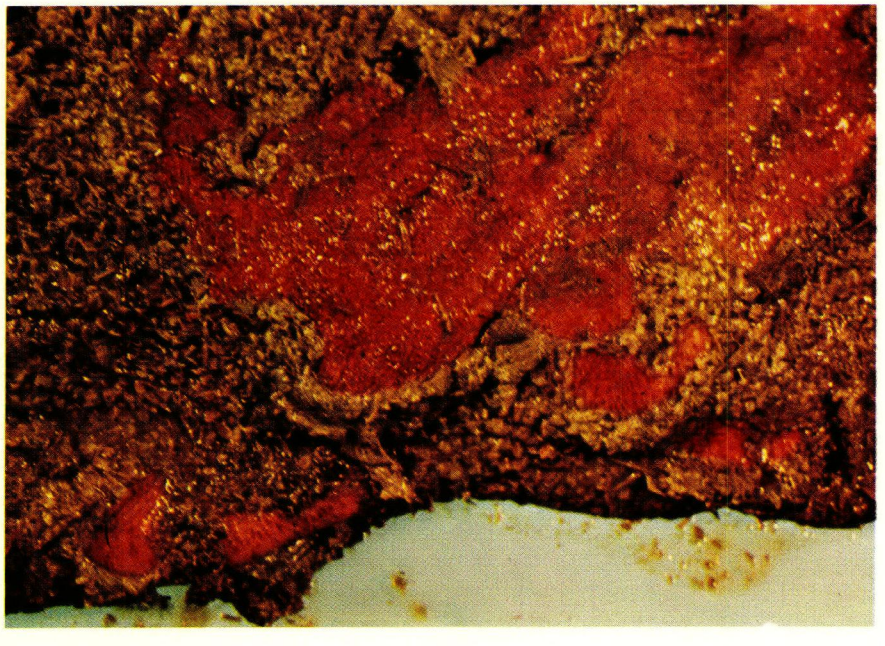



PLATE 452: PHYSIOLOGICAL HYPEREMIA

The well marked reddening of the major portion of this stomach is an example of normal physiological hyperemia. There is no free blood in the lumen or other evidence of inflammation. This is a very common finding in many species and is often mistaken for hemorrhagic gastritis.

PLATE 453: TORUS PYLORICUS

This pale, tongue shaped bulge of tissue at the junction of the stomach and duodenum is a normal anatomical feature in the pig. It is included in this atlas along with several other "nonlesions" as it is so often considered a lesion.

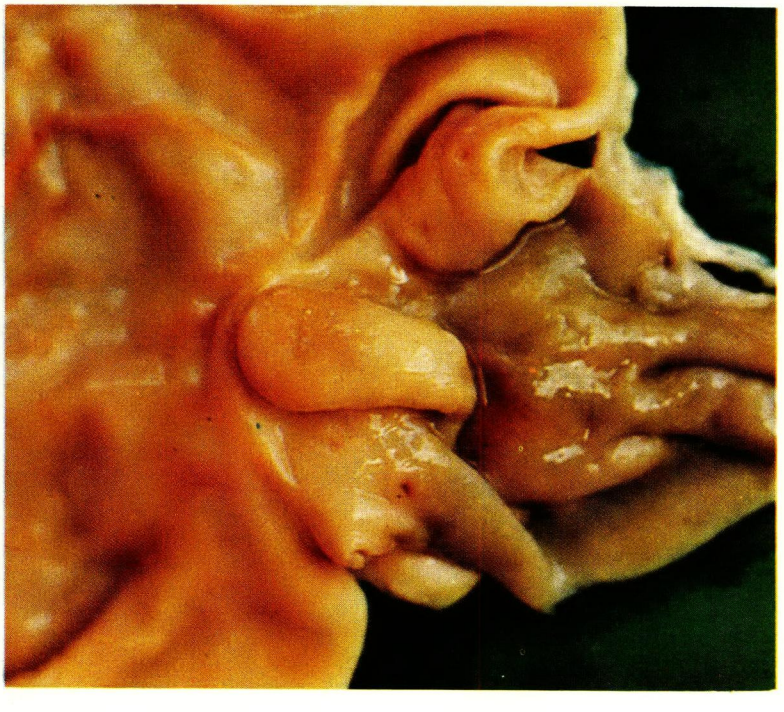

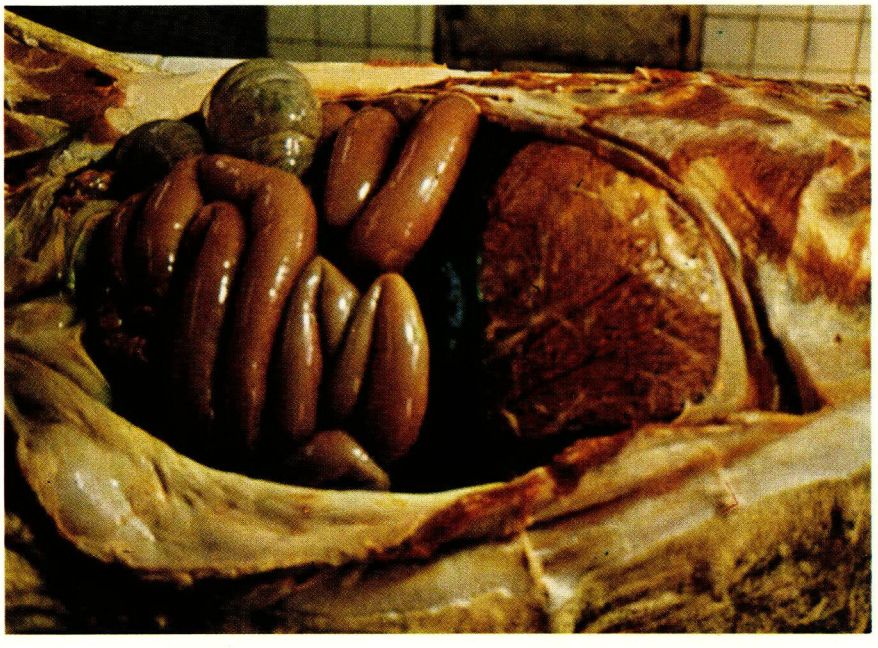

PLATE 454: GASTRIC TORSION

The abdomen was well distended and tense prior to being opened in this freshly dead pig. The spleen is seen here on the right side which is abnormal and the intestine and stomach are gas filled. The greater omentum is stretched over the stomach which has twisted about 360° out of position. It was replaced to its normal position along with the spleen by untwisting it from caudal to cranial 360°. Its greater curvature lies under the greater omentum. The spleen is distended with blood (splenomegaly) as is common in this process. Many of these occur in pregnant sows. They are common in large breed male dogs and tend to occur shortly after eating. Abomasal torsion in cattle is more common in pregnant cows also.

PLATE 455: GASTRIC TORSION

While the exact anatomical features of this stomach twisting can not be seen in this photograph, the severely congested vessels on its surface, the distinctly pale (anemic) tissues at the twist area itself, the congested segments of duodenum on both sides of the twist and the markedly congested portion of liver just under the thumb with a very pale liver on the other side are all features of such a lesion. Most of these occur shortly after eating, at least in large, male dogs. A greatly distended abdomen is of clinical and postmortem significance. Rough handling of the carcass may replace these structures prior to necropsy and make the diagnosis less definite. In pigs, it is more common in pregnant sows.

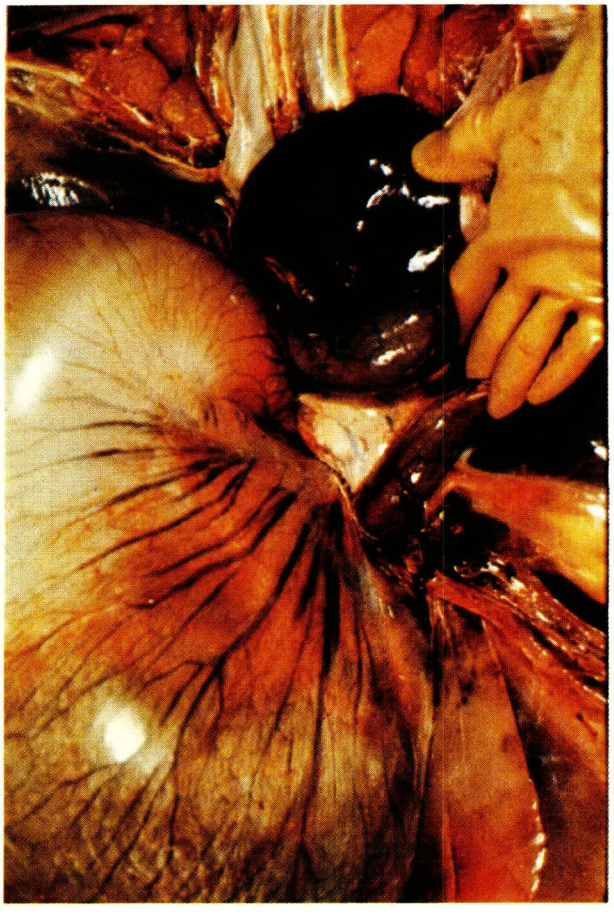

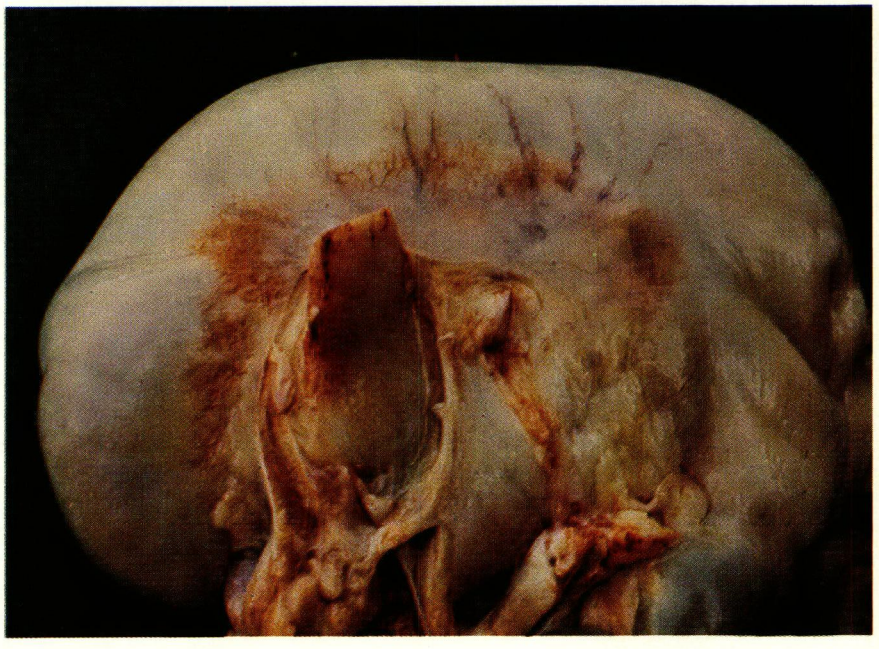

PLATE 456: MEDUSA HEAD VASCULARIZATION

The outline of the esophageal portion of the stomach is seen by the fine interlacing network of small blood vessels (compensatory vascularization) in a rectangular pattern related to the underlying gastric ulcer. This area on palpation is firmer and thicker than normal.

PLATE 457: GASTRIC ULCERATION

The large whitish area is the esophageal portion of the pig's stomach and in its approximate center is the esophageal opening. On both sides, an elongated ulcer is present with some necrotic debris attached at the wider end. A much larger ulcer is present at the end of the opening with more necrotic epithelium on its surface. The glandular epithelial lining is bile stained, but otherwise normal. This ulcer had not hurt this animal clinically, but it is only a question of time before such lesions erode a deep vessel to bleed the animal to death. Histologically, mycotic infections are sometimes seen but their relationship to the cause of the ulcers is not known.



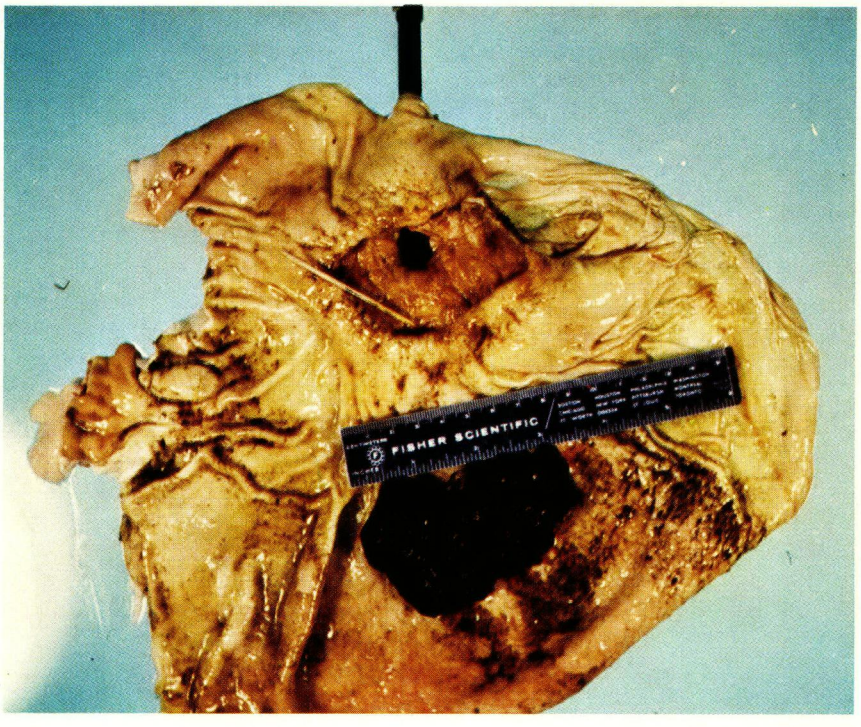

PLATE 458: BLEEDING ESOPHAGOGASTRIC (GASTRIC) ULCER

The rectangular patch of the esophageal region of the stomach is completely denuded of epithelium. A dark rod has been inserted down the esophagus and into the stomach lumen. A tooth pick is pointing to the area of eroded vessel at the edge of the ulcer and a large brown blood clot is on the other side of the ruler. Much free blood and smaller clots were present in the lumen and throughout the entire G.I. tract. This ulcer killed this pig by exsanguination which is a common cause of death in these cases. Others may cause gastric perforation and peritonitis. This type of ulcer is to be differentiated from others in the stomach. Many early cases of these begin as erosions and ulcers at the junction of the glandular mucosa with the stratified squamous mucosa.

PLATE 459: BLOOD CLOT

This large, soft, red blood clot completely filled this pig's stomach and made an almost perfect cast of its lumen. A bleeding gastric ulcer was the cause. Most of these cases may have some blood clots in the stomach, but this is larger than normal as most of the blood passes down the GI tract. Such a large clot as this suggests a rapid bleeding out process into the stomach. The gastric content in these cases with much blood has a distinct odor of fermentation if the animal has been dead for at least a few hours.

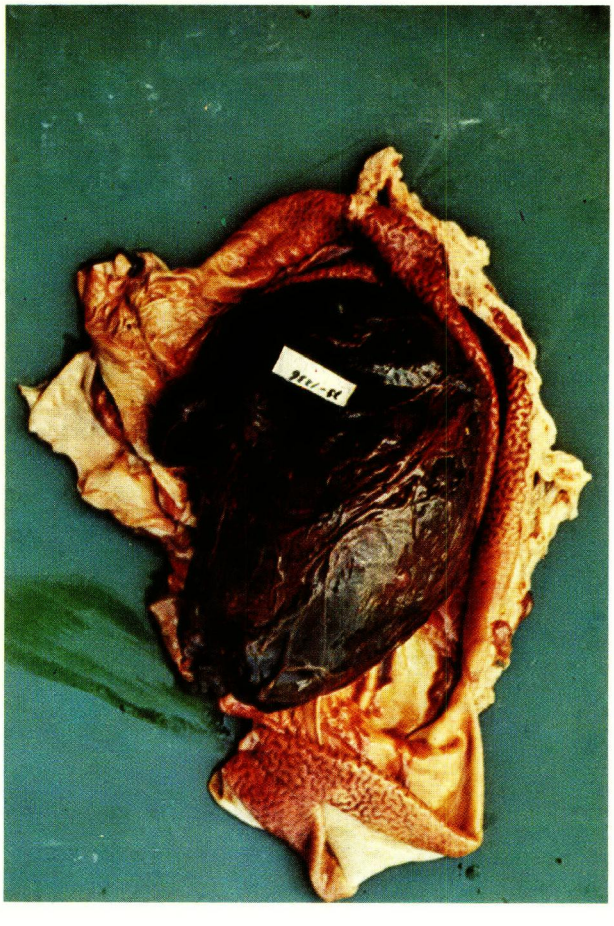



PLATE 460: SUPERFICIAL HEMORRHAGIC ULCERS

Along the free edges of the gastric folds are scattered brownish spots and elongated areas which are acute hemorrhagic ulcers. Some bile stained epithelium is present in the pyloric region and the keratinized rough area of the esophageal region is also bile stained. The actual cause of these relatively common hemorrhagic ulcers in all species is not known, but they are more likely to be seen following severe stress than in cases of instant death.

PLATE 461: ESOPHAGEAL HYPERKERATOSIS AND PARAKERATOSIS

This area is markedly bile stained and shows the grooves and folds caused by these epithelial changes. The deeper grooves are not as involved nor stained as apparently when the pig was alive the constricted space prevented the material from getting down deep into the grooves. The actual cause is not known for this lesion.





PLATE 462: MODIFICATION OF RUMEN PAPILLAE

The rumen section with the small papillae is normal, but the other section has markedly elongated and broadened papillae. They were both normal animals, but one was fed a normal diet of regular feed while the one with large papillae was fed pelleted feed only. This caused a change in the character of the papillae in order to facilitate rumen digestion. It is for this reason that the type and consistency of diet can not be changed drastically over a short period of time in a ruminant without expecting some type of digestive disturbance.

PLATE 463: GASTRIC EDEMA

The wall of this stomach is markedly thickened with a clear watery material lifting the mucosa. This is a case of edema disease. Some edema, although probably not to this extent, may be seen in cases of hypoproteinemic edema as from a bleeding ulcer.

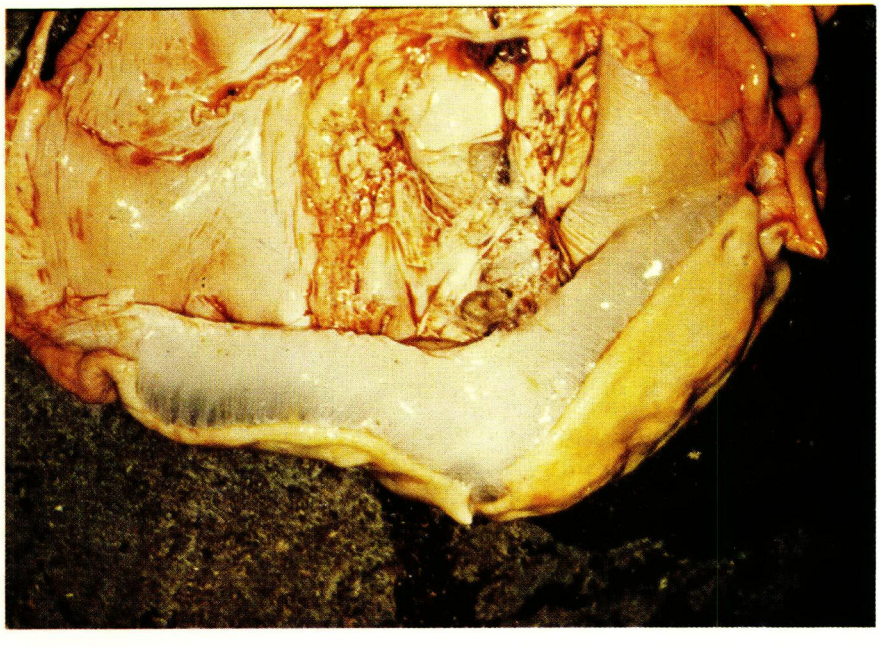



PLATE 464: SUBMUCOSAL EDEMA

The thin layer of mucosa at one edge, with a congested vessel adjacent, is separated from the muscle coat by a massive zone of finely granular edema with a large capillary running diagonally through it. This is a case of edema disease.

PLATE 465: UREMIC MINERALIZATION

This dark staining material along the basement membranes of the gastric epithelium and capillaries is a mineral, most likely calcium. It is in the most characteristic location in the stomach, the midepithelial zone. In marked cases, a gritty sensation can be felt when the mucosa is cut and this can even be palpated if the stomach is allowed to stiffen first at cold temperatures. Renal lesions, parathyroid hyperplasia and uremic frosting of the pleura are often concomitantly seen.

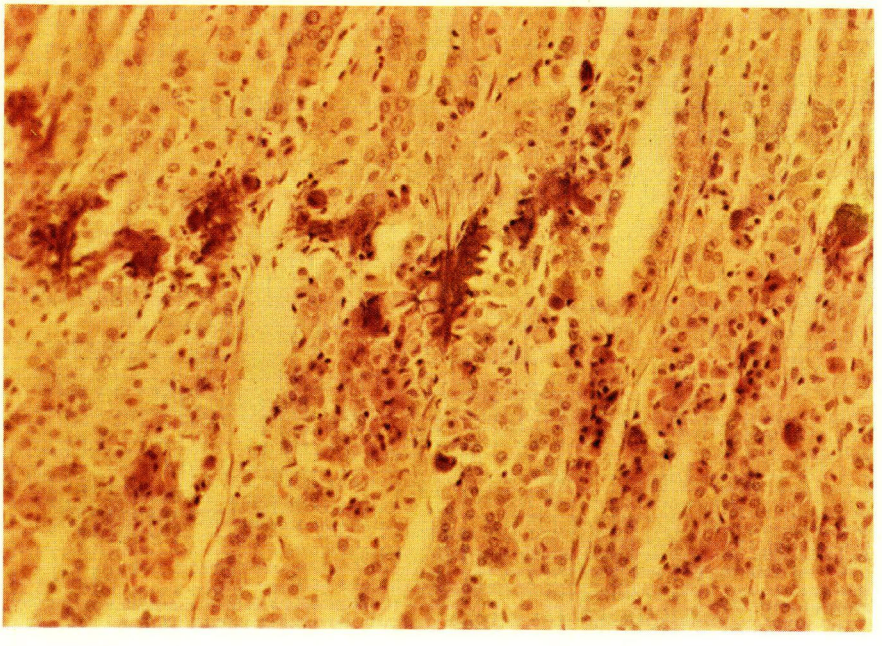

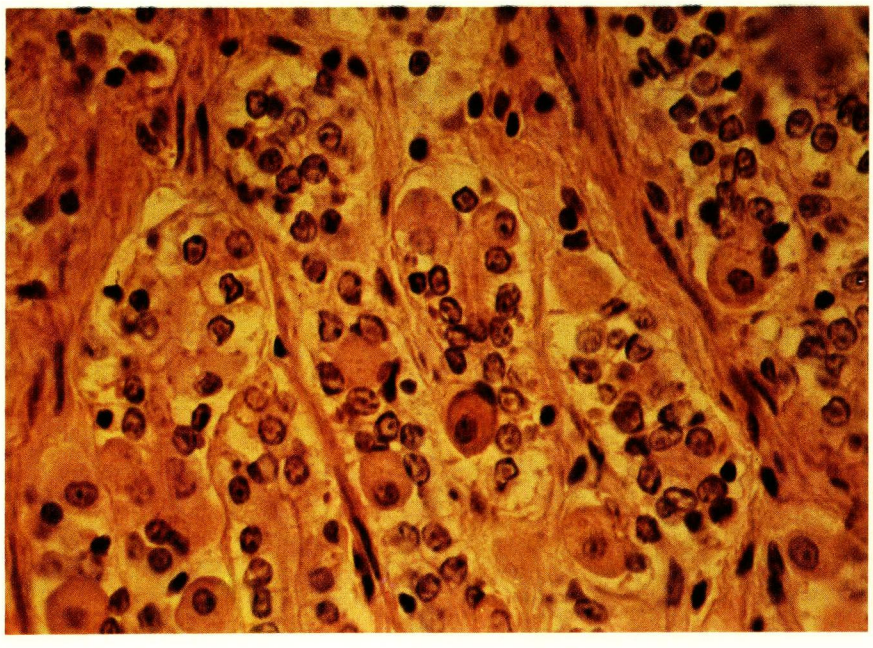

PLATE 466: INCLUSION BODIES

This is a section of the stomach from a dog. Scattered in the glandular cells are many nuclei that show a marked margination of their chromatin. In these nuclei, many red to purple bodies of various sizes and shapes can be seen. A few similar bodies can be seen in the cytoplasm of the gastric cells. All of these bodies are the inclusion bodies of canine distemper. They can also be seen in many other cells throughout the body. The several large red cells in the mucosa are normal parietal cells.

PLATE 467: MYCOTIC GASTRITIS

Characteristically, the gastrointestinal lesions appear like this in most species. They have a depressed center with a pale zone around them and a thin zone of imflammation about that. The pale central zone is usually flat without much necrotic debris attached, so that one thinks of it as an area of infarction. Most of the lesions are a form of surface infarction. The diagnostic lesion histologically is a mycotic thrombosis. In most cases, antibiotic therapy, especially oral, is in the history. Mucor spp. or Aspergillus spp. are commonly isolated. Some caution should be exercised to rule out the common surface contaminants both during cultural techniques and histological examination.

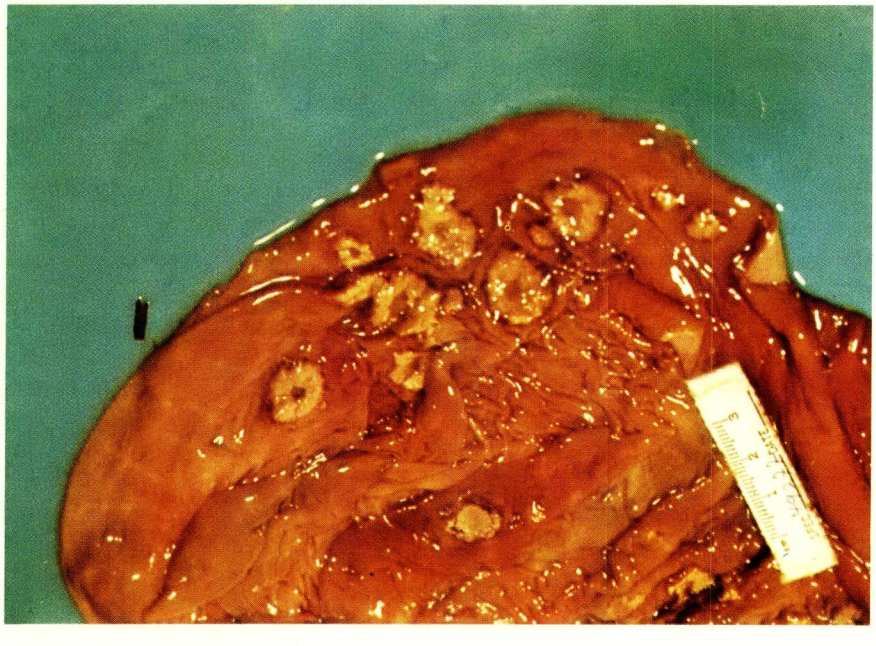

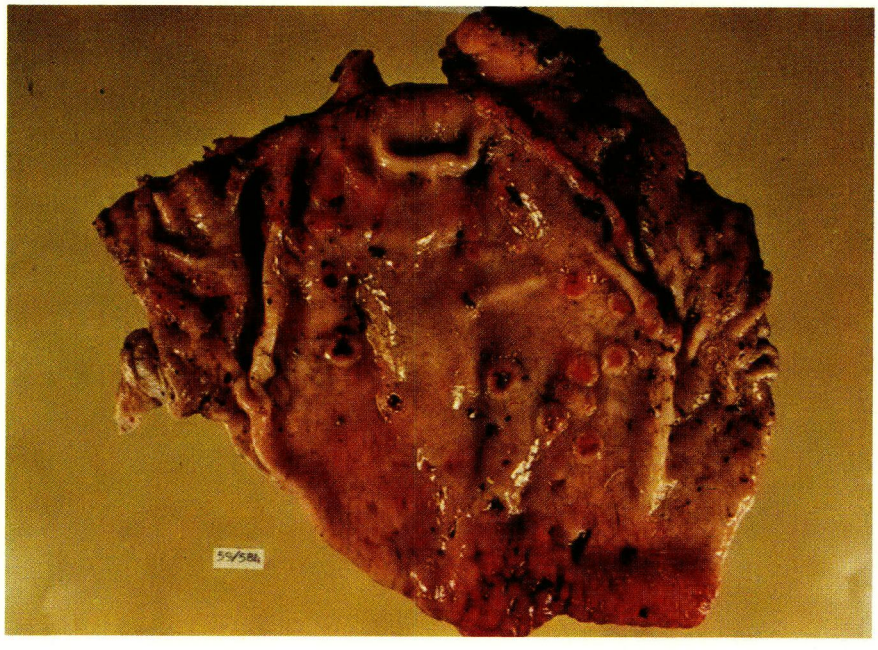

PLATE 468: ULCERATIVE GASTRITIS (PARASITIC GASTRITIS)

These multiple, crateriform lesions scattered in the fundic portion of this pig's stomach were caused by the red hair stomach worm, Hyostrongylus rubidus. With an increase in time or severity, these lesions may coalesce to form large, undermined ulcers in this region.

PLATE 469: BESNOITIOSIS

A single section of a parasite, suspected to be Besnoitia (Globidium) leuckarti, is present in this portion of sheep's abomasum. It was noted grossly, and mistakenly considered to be a slightly smaller than normal lesion of ostertagiosis. Related parasites cause skin lesions in cattle, and they are commonly seen in the intestine of horses as well as sheep.

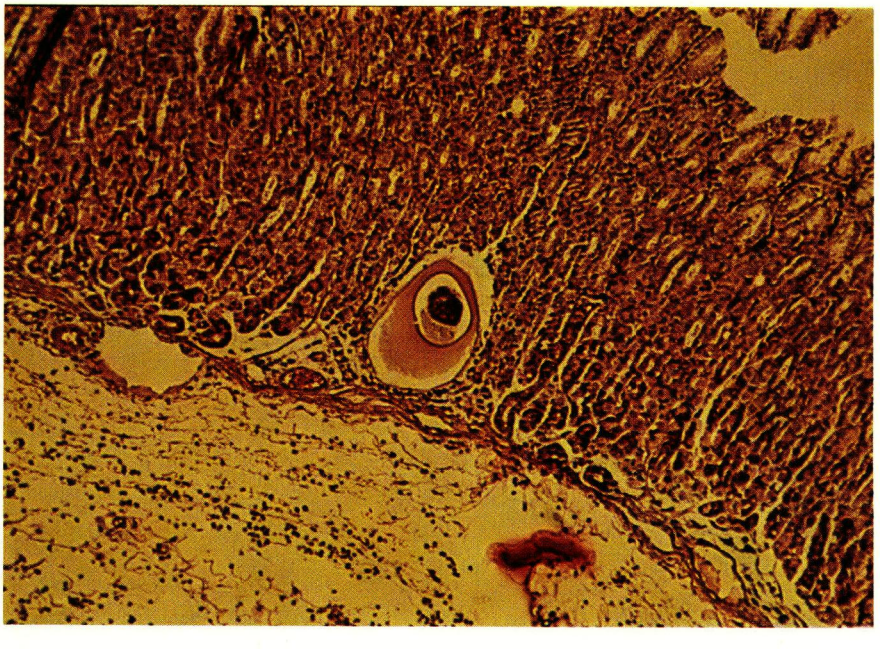

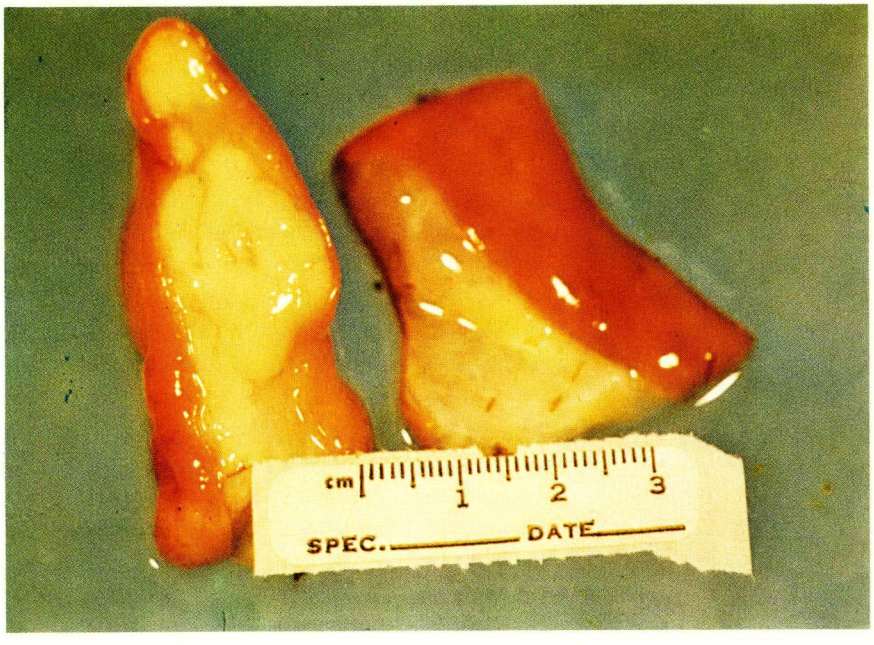

PLATE 470: SUBMUCOSAL EDEMA AND LYMPHOID NEOPLASIA

These two pieces of abomasal fold clearly demonstrate these processes. The neoplastic lymphoid tissue invading the abomasum are the several pale, opaque white tissue foci in the one fold, while the watery like thickening of the other fold is due to edema. In this instance, the edema was caused by a hypoproteinemia that was in turn related to lymphoid neoplasia which had caused several bleeding ulcers in other areas of the abomasum. The abomasum, uterus and right heart are three nonlymphoid tissues commonly affected by this disease in cattle. The appearance of the edema here is no different than one may see in other hypoproteinemias as from stomach worms (H. contortus) or starvation.

PLATE 471: EMPHYSEMATOUS RUMINITIS

This large, slightly reddened portion of rumen mucosa was gas filled on palpation, and histologically, only a minimal inflammatory reaction is seen to accompany the massive submucosal gas bubble infiltration. A similar lesion can be seen in the abomasum and the urinary bladder following intensive therapy with sugar solutions either orally or intravenously.





PLATE 472: TOXIC RUMINITIS

The serosal surface of the forestomachs, mainly the rumen, is shown here with large patches of hemorrhagic inflammation and fibrin deposition. The mucosal surface of these areas is dull with necrosis and is easily pulled away in some areas and more firmly adherent in others. A large concentration of corn was admixed with the grass ingesta. This animal had overeaten on concentrates (corn) a short time previously. In cases where the animal lives for a longer period of time, the grain may have already been broken down and the affected areas of wall have a secondary, mycotic infection present. This is one form of "overeating disease". Another is "lactic acid indigestion" without specific lesions but with a history of overeating, lowered rumen pH, and an elevated blood lactate. A third and more common form is "enterotoxemia, Clostridium perfringens type D " with fluid and fibrin in the heart sac and splotchy hemorrhages in the abdominal wall and viscera. A fourth type is that of "C. perfringens type C enterotoxemia" in piglets, calves and lambs, and in which, one usually finds large splotchy hemorrhages in the viscera. The first two types are found in adult cattle and sheep, while the third is more common in growing ruminants.

PLATE 473: GASTRIC HAIRBALL (TRICHOBEZOAR, TRICHOCONCRETION)

This 7 cm. long mass of hair fibers was found as an incidental finding in an otherwise normal stomach of a pig. In the calf where they are more commonly found, they are usually associated with lice, pica or just boredom, especially in crated calves.



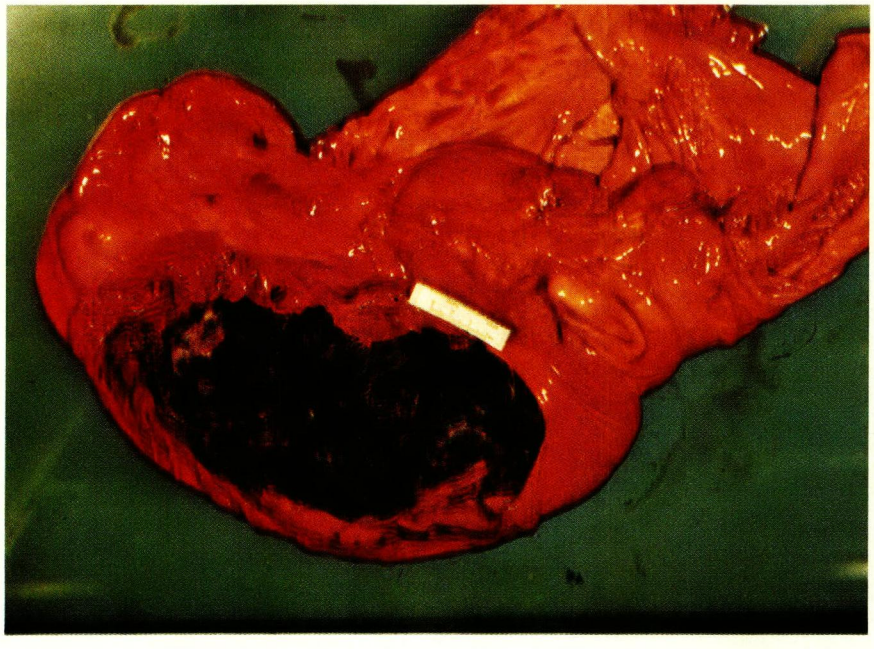

PLATE 474: HAIRBALLS (TRICHOBEZOARS, TRICHOCONCRETIONS)

The four dark masses in the abomasum of this aborted calf are matted balls of hair (hairballs). One or many may be found in an animal, but rarely do they cause death. In calves, the cause is usually associated with lice infestation, boredom or pica, a craving for abnormal food. The presence of these in a fetus however does not fit these categories. They have concentrated in this fetus by the swallowing of amniotic fluid which contained much loose fetal hair.

PLATE 475: DUODENAL ULCER

There is a 2 cm. perforated ulcer in the first part of the duodenum just as it leaves the stomach and under one lobe of the liver. It is open directly into the lumen of the duodenum. Bile is staining the peritoneum which also has a slight amount of fibrin scattered on it. Duodenal ulcers are not too common in animals and when seen, other related lesions should be looked for. This was a case of cutaneous mastocytosis in a cat. They have been seen in animal cases of granulocytic myeloid tumors and extreme eosinophilias.

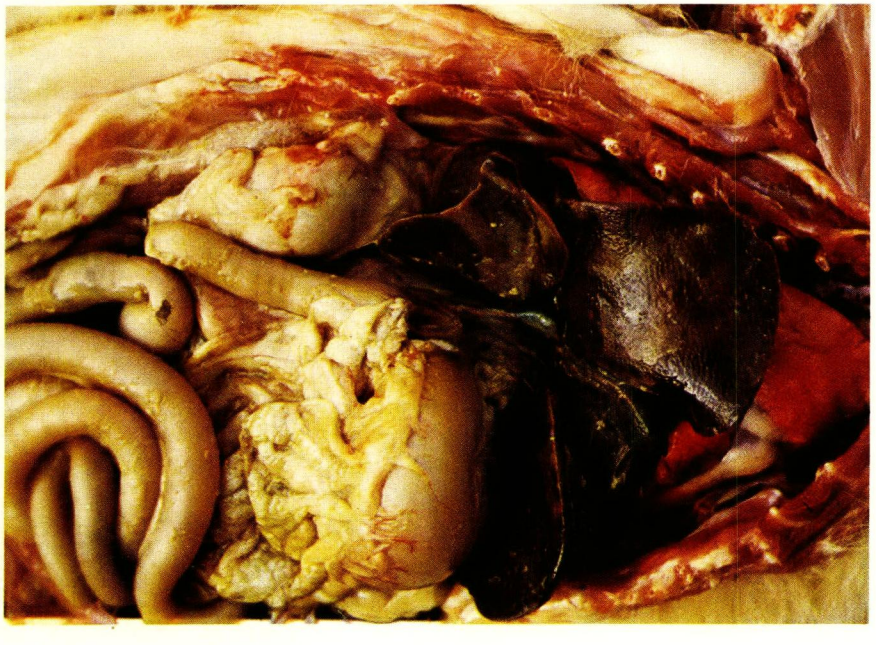



PLATE 476: TERMINAL INTUSSUSCEPTION

The accordion, pleated, slightly darkened, angled portion of intestine is the intussuscipiens into which a smaller portion of intestine, the intussusceptum, has invaginated. As there is no vascular response such as edema or congestion, this is considered a terminal or even a postmortem event. These are relatively common in many species and probably occur as a result of peristalsis which continues even after death.

PLATE 477: INTESTINAL TORSION

The stomach and first part of the duodenum are essentially normal, but the remaining intestinal mass is markedly congested with a few small strands of fibrin on its serosa. The root of the mesentery is twisted from left to right (in this view) 180 degrees. A distinct line separated the pale tissue in the dorsal part of this mesenteric root from the markedly congested ventral portion. Often such a lesion may involve a 360 degree twist. Externally, this pig's pale skin and mucous membranes, from shock, made one think that a bleeding gastric ulcer may have been involved. Torsions of the intestine are common in several species, especially the horse, which may trap or fall unexpectedly without chance to utilize "abdominal press" to immobilize their viscera as they would normally do in "rolling" or "fighting".





PLATE 478: ILEAL HYPERTROPHY (MUSCLE FORM)

The ileum of this pig as it enters the cecum is about 3-4 times thicker than normal. This increased thickness extends cranially about 20 cm.. The thickened muscle coat is recognized as the grey layer in the opened section of ileum. The cause is not known. The histological appearance is that of smooth muscle hypertrophy. A mucosal form may also be seen in pigs in which the mucosa is markedly hypertrophic grossly with hyperplasia microscopically. The mucosal form often suggests an inflammatory process as the cellular proliferation is mainly of chronic inflammatory cells. Both forms may result in obstruction and subsequent perforation and peritonitis. This is a common lesion in horses. A similar lesion, idiopathic hypertrophy of the distal esophagus, is very common in the horse also.

PLATE 479: ILEAL HYPERTROPHY

In this pig, both the inner circular and the outer, longitudinal muscle coats are thickened at least 5 times more than normal. The mucosa and submucosa are essentially normal. The serosal surface is roughened with fibrinous exudate. As is common with this lesion, a perforation of the wall occurred with subsequent peritonitis developing. The cause of this hypertrophy is not known. It sometimes occurs in epizootic proportions. It occasionally occurs in the horse and dog.





PLATE 480: LEIOMYOMETAPLASIA

The dog's cecum in the middle of this picture is essentially normal. The darkest brown colored small intestine is the jejunum. The ileum, as it joins the colon, and the duodenum, attached to the stomach near the liver, are less intensely colored. This brown discoloration is called "leiomyometaplasia" and is due to the presence of small PAS (periodic acid Schiff) positive granules called leiomyometaplasts in the smooth muscle cells. If only a relatively few cells are affected, a gross change may not be noticed. The outer fibers of the inner muscle layer are affected first. This change was initially reported early in this century in dogs with experimental biliary fistulae. It has been shown to be related to lipid metabolism including a Vit E deficiency. It may also be seen in the bladder, colon and stomach, and has been seen in other species. This is also referred to as lipofuscinosis.

PLATE 481: LEIOMYOMETAPLASIA

The wider portion of bowel is the normal colored bowel and the tan section of bowel is affected with leiomyometaplasia (brown dog gut). The tan color is due to pigmented granules (leiomyometaplasts) in the smooth muscle cells. The granules are mostly concentrated in the outer fibers of the inner muscle layer of the muscle coat. The disease is seen in dogs primarily. The gross lesion was originally described in dogs with experimentally produced biliary fistulae. They had a "maple sugar" colored intestine. It has since been reproduced in animals with a Vit E deficient diet.

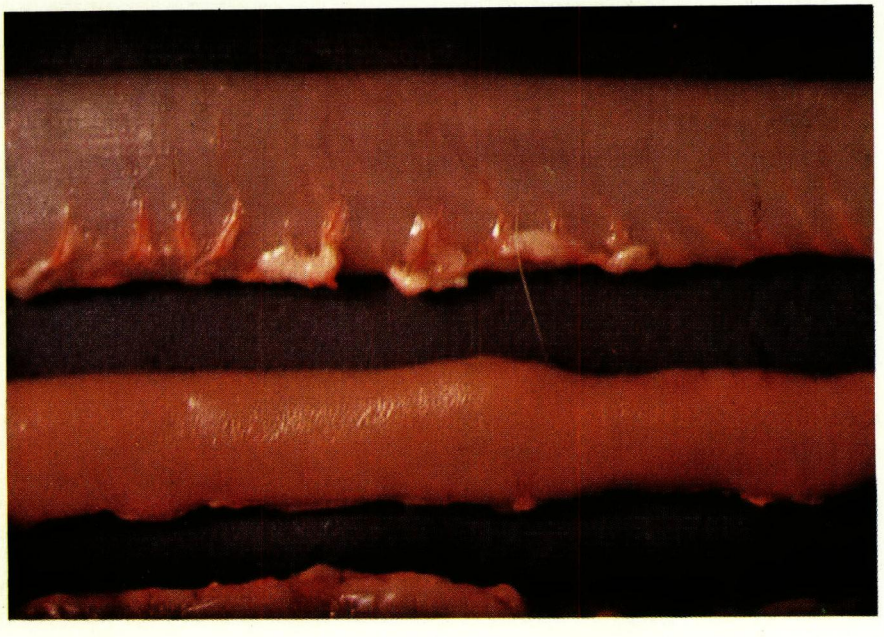

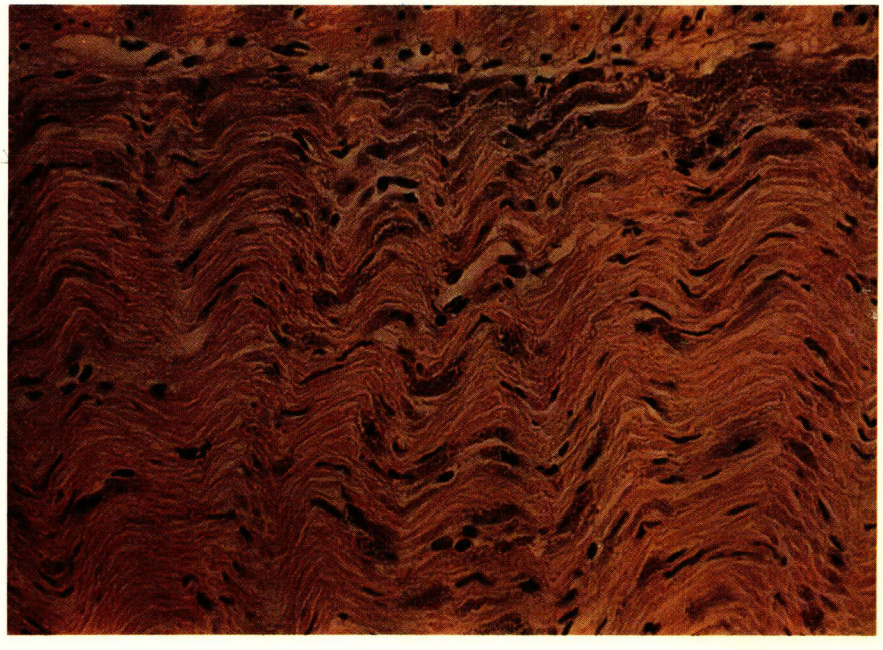

PLATE 482: LEIOMYOMETAPLASTS

The major area in the picture is the outer portion of the inner muscle layer of a dog's intestine. This H & E (hematoxylin and eosin) stained section shows the small granules, leiomyometaplasts, mostly concentrated in the outer smooth muscle cells of this layer that gave the brown discoloration to this dog's intestine. They are less concentrated centrally. They weaken the cells physically. With time, much of this material may be coalesced near the ends of the nuclei. In chronic cases, they may be found in local macrophages. They are probably related to abnormal lipid metabolism. Although most common in mature animals, they can be found in young dogs.

PLATE 483: SALMONELLOSIS

The gastrointestinal tract in this dog shows the characteristic segmental lesion of salmonellosis. It does not affect any one section of bowel completely. One portion in the picture is tied off for future bacterial isolation. Salmonella paratyphi was isolated from this case. The intestinal content has a typical septic tank odor.

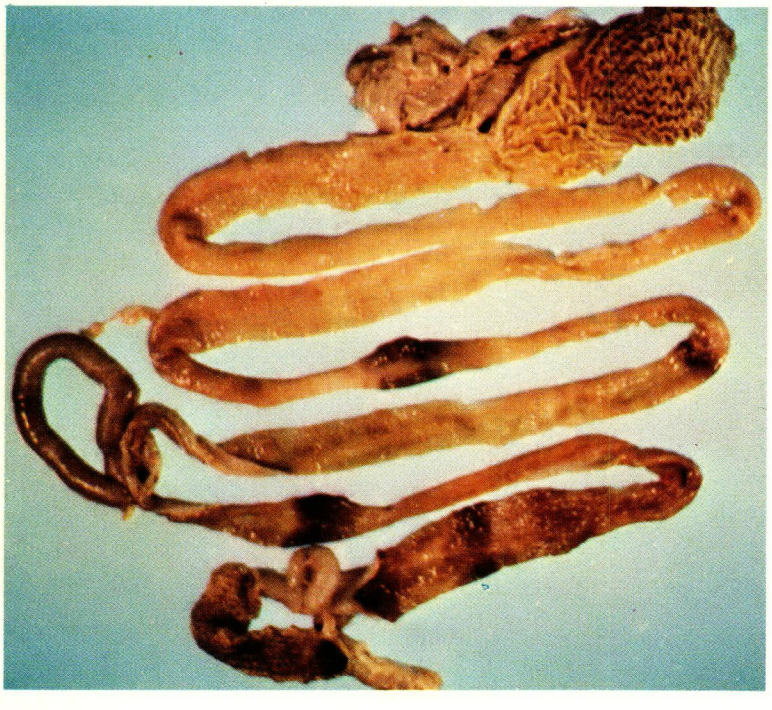



PLATE 484: HEMORRHAGIC BOWEL SYNDROME (HBS)

The small bowel, mostly the ileum, appears thicker than normal and the regional nodes are enlarged. When opened, the mucosa was thickened very much like the corrugated bowel seen in Johne's disease in cattle and much clotted blood was in the lumen. The colon content as seen through the wall is dark from the blood coming from the ileum. In most cases, so much blood is lost that the animal actually bleeds to death. Often this is just a segmental lesion involving only scattered segments of small intestine and not a whole region of bowel. Many cases have only the blood and blood clots in the lumen with no appreciable lesion in the wall grossly (hemorrhage by diapedesis). This is usually seen in pigs under six months of age.

PLATE 485: HEMORRHAGIC BOWEL SYNDROME (HBS)

A blood clot is present in the opened lumen with a thickened, blood stained, small intestine mucosa. This lesion may affect only a segment of the small intestine as the ileum and not the jejunum. A few cases have only the blood and bloody content without any thickening of the intestinal wall.

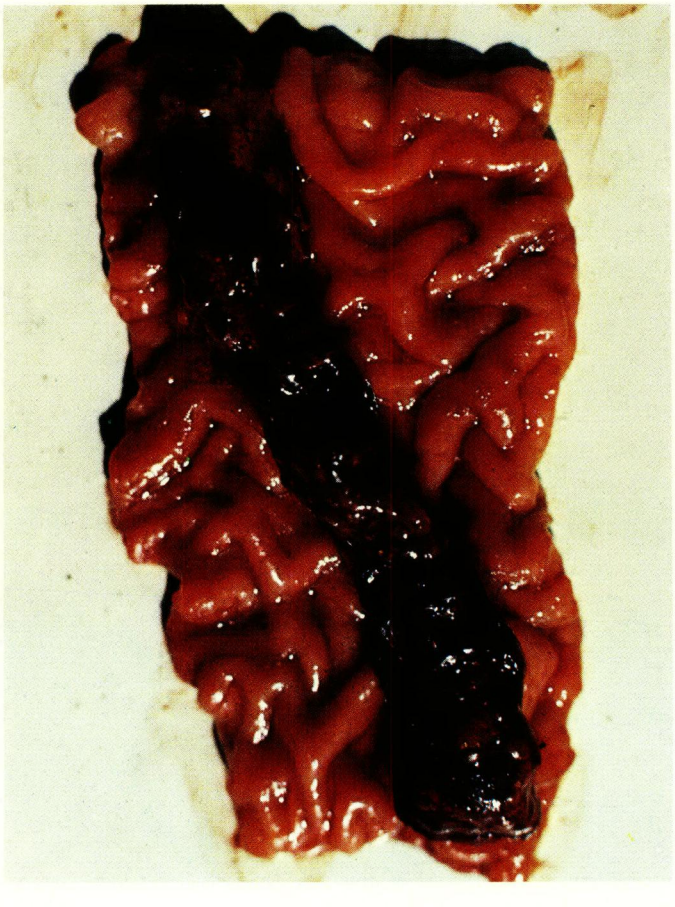

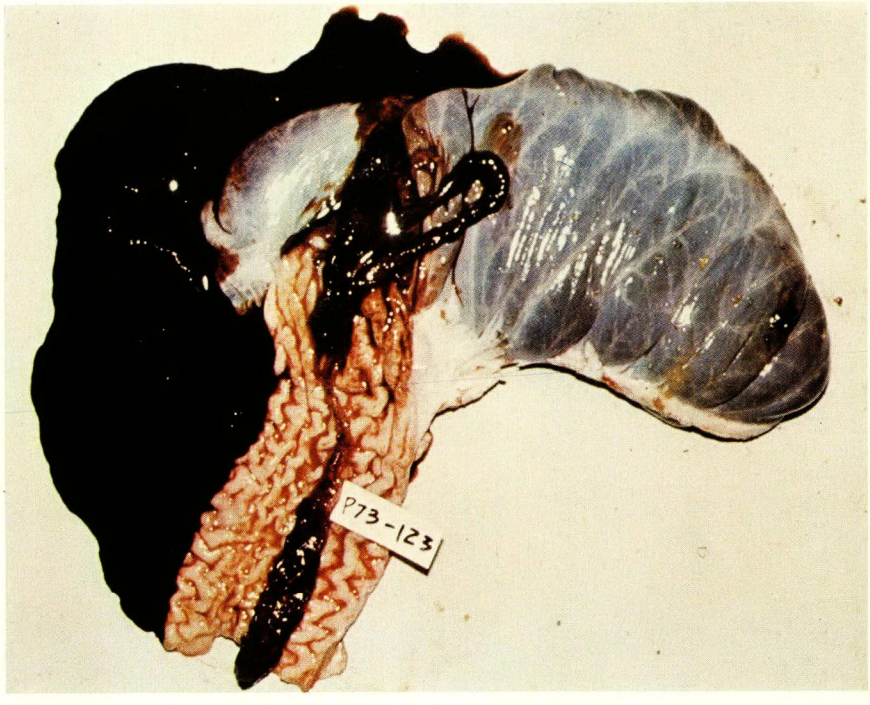

PLATE 486: HEMORRHAGIC BOWEL SYNDROME (HBS)

The opened ileum of this pig is seen with its slightly thickened mucosa and some clots of blood in its lumen. The cecum is filled with bloody material and much of it has spilled out. This suspected viral disease affects the small bowel causing much hemorrhage into the lumen which then passes into the uninvolved cecum and large intestine. The hemorrhage is usually severe enough to exsanguinate the pig. The histological lesion is characterized by dilated intestinal crypts often filled with necrotic debris. In any case of gastrointestinal (GI) hemorrhage, the source should be established. Blood in the colon can come from three areas; the colon itself as in cases of swine dysentery in pigs, the small intestine as in cases of the hemorrhagic bowel syndrome (HBS) or from the stomach in animals with a bleeding gastric ulcer. If blood is found in the small intestine, one should consider HBS or a bleeding gastric ulcer. Blood found in the stomach only should make one look for a bleeding ulcer.

PLATE 487: HEMORRHAGIC BOWEL SYNDROME (HBS)

This is the chronic form of HBS. The hypertrophied mucosa can be seen pushed up as folds into the lumen. Much semidigested blood and blood clot is adherent to the necrotic mucosa. As this may affect only a single small segment of bowel, the entire small intestine should be examined to make the diagnosis.





PLATE 488: NECROTIC ENTERITIS

The mucosa of the small intestine is disorganized with missing epithelial crypts, some regenerating crypts and several crypts filled with necrotic debris. Many chronic inflammatory cells are present in the deeper layers of the mucosa and in the submucosa. While this is a case of HBS, it could represent any one of a number of infectious enteritides.

PLATE 489: DILATED AND NECROTIC INTESTINAL CRYPTS

Most of the intestinal crypts shown here are dilated and some contain necrotic debris, mostly neutrophils. Several crypts lack areas of epithelial covering, but most have an abnormally thin epithelial lining of bizarre regenerating epithelium. Only three of the crypts shown have original epithelial lining cells present. Fibrinous debris is in the intestinal lumen. Such a lesion is quite diagnostic for HBS in pigs, panleucopenia in cats, virus diarrhea in cattle and radiation injury in most species.

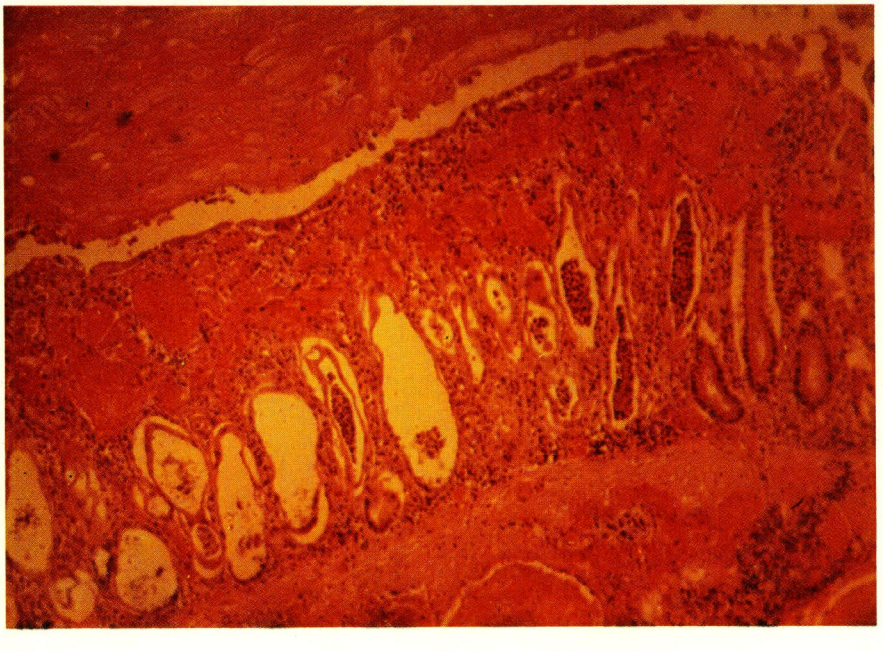



PLATE 490: FIBRINONECROTIC ENTERITIS

The ileum of this suckling pig is enlarged with fibrin and necrotic debris and its wall is moderately congested. The intestinal infection is severe enough to have caused a serosal inflammation as evidenced by the presence of fibrin on the surface of the affected bowel. Most of these cases are bacterial in origin and numerous agents may be isolated. Shigella spp. was isolated from this case.

PLATE 491: VILLUS ATROPHY

The well marked blunted and clublike villi with only a few inflammatory cells suggests a decrease in reepithelization of the affected mucosa in the intestine. This is a case of TGE in a piglet.

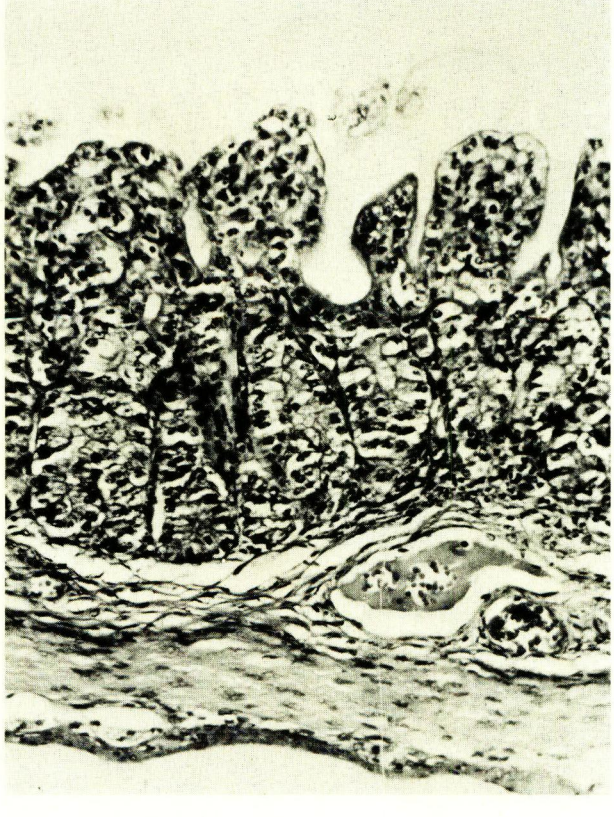

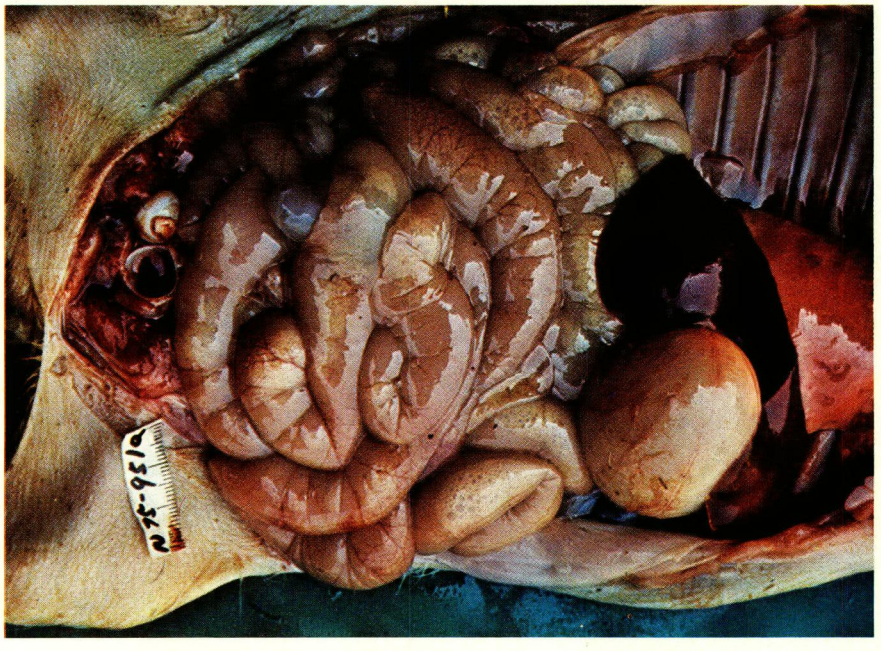

PLATE 492: GASTROINTESTINAL ATONY

The stomach and entire intestinal tract is flaccid and partially filled with gas and a foul watery content. There is no normal ingesta, even though feed was available to the animal. This is a common intestinal finding when animals are terminally ill for any reason and do not eat properly. A lack of body fat and a dark liver are also seen here.

PLATE 493: COCCIDIOSIS

The small intestine of this lamb has many small, pale, flat patches in its wall with an irregular central area of a more opaque white appearance. These are clusters of coccidia, Eimeria spp., a protozoan parasite. Diarrhea was present clinically. The whiter centers are the more concentrated foci of parasites, while the outer areas of each plaque are the areas of epithelial hyperplasia.





PLATE 494: NODULAR WORM DISEASE

The multiple, firm nodules on this animal's intestine are chronic foci of necrosis and abscessation caused by nodular worms, Esophogostonum spp.. They are common in sheep and less so in swine and cattle. Surprisingly, large numbers may be found without evidence of any clinical effect. They do occasionally serve as the nidus for intussusception formation.

PLATE 495: INTESTINAL PERFORATION

A thickened portion of small intestine has a small mound like elevation with the anterior part of a "thornyhead" worm protruding from its center. At first, one may confuse this parasite, Macracanthorhyncus hirudinaceus, with the ascarid, Ascaris lumbricoides, but these worms are attached while ascarids are not. These are also flatter than ascarids. Peritonitis, as in this case, is a common cause of death in this parastic disease.





PLATE 496: ASCARIASIS

The mass of worms in this intestine are all Ascaris lumbricoides and the absence of any reaction to them suggests they are being tolerated by their host. A surprising number can be found in an apparently normal pig but a single worm abnormally located, as in the bile duct, may cause the animal's death by duct perforation. There is some truth to the fact that the larger the host, the larger the individual worms may be. There is a characteristic sweet odor to these parasites if washed clean of feces and allowed to stand in a container for a short period of time.

PLATE 497: INTESTINAL EMPHYSEMA

The large numbers of gas pockets are in all layers of the gut wall, under the peritoneum and in the regional lymph nodes. Some edema is associated with these gas bubbles. They are nonsymptomatic. There is usually a foreign body reaction about these, even with the formation of foreign body giant cells. Their cause is unknown, but as excess glucose in the urinary bladder and stomach of various animals can cause a similar lesion, it should also be considered here.

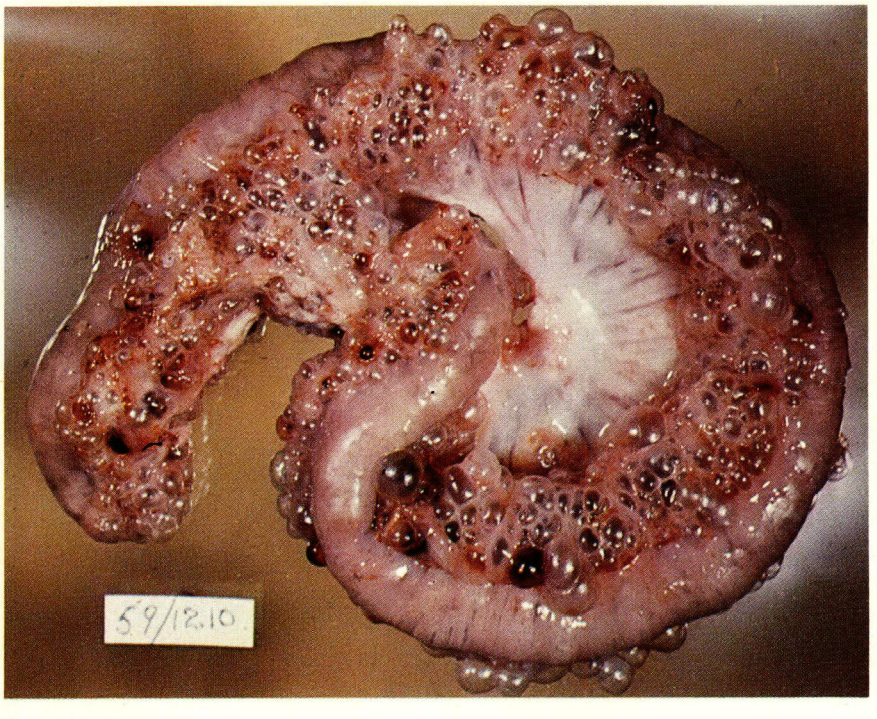



PLATE 498: INTESTINAL EMPHYSEMA

The wall of this pig's ileum is swollen with large numbers of gas pockets giving it a spongy feeling. It is a common lesion seen in the slaughter house. Its cause is unknown, but as it occurs in the urinary bladder of diabetics and in animals given excessive glucose, one should consider this relationship.

PLATE 499: INTESTINAL EMPHYSEMA

Relatively large bubbles of gas are present in the ileal mucosa and can be seen here in both the mucosal view and side view of the mucosa. No appreciable tissue reaction is seen to this lesion, although with time the bubbles will migrate to the regional nodes and foreign body giant cells may form about them. The several reddish spots at the top of several of the bubbles makes one consider that they may be related to intestinal lymph follicles, at least morphologically. Their actual cause is not known.

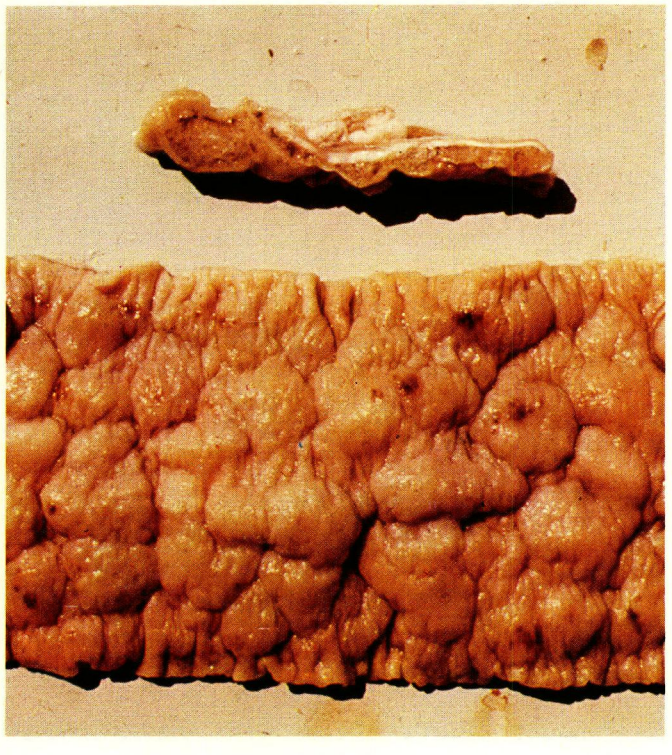

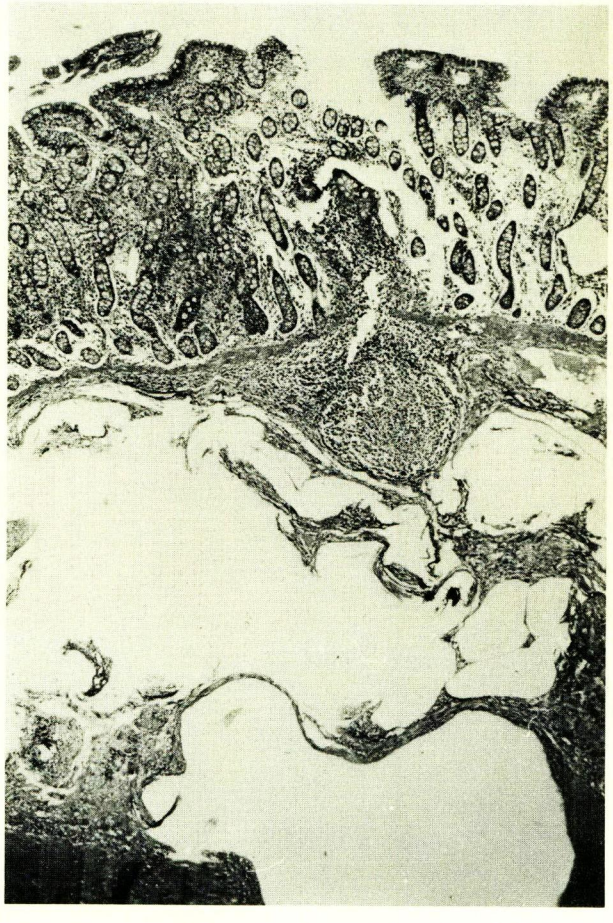

PLATE 500: INTESTINAL EMPHYSEMA

Large gas pockets are distending the submucosal tissue, primarily the lymphatics, in this pig's ileum. No appreciable tissue response is seen. It is a common lesion of pigs and has been seen in other species, but its cause is unknown.

PLATE 501: TRAUMATIC HEMORRHAGIC AND EARLY INFARCTION

This portion of small bowel had been stepped on through the abdominal wall by the sow. Marked hemorrhage and edema have formed under the serosa and have spread in both directions from the area of vascular damage. When opened for further examination, the mucosa was dull in appearance and the vessels to the area had been traumatically torn apart. In another similar appearing lesion, an embolic shower from the left heart resulted in an infarct of the area which demonstrates the need for caution in interpreting lesions.

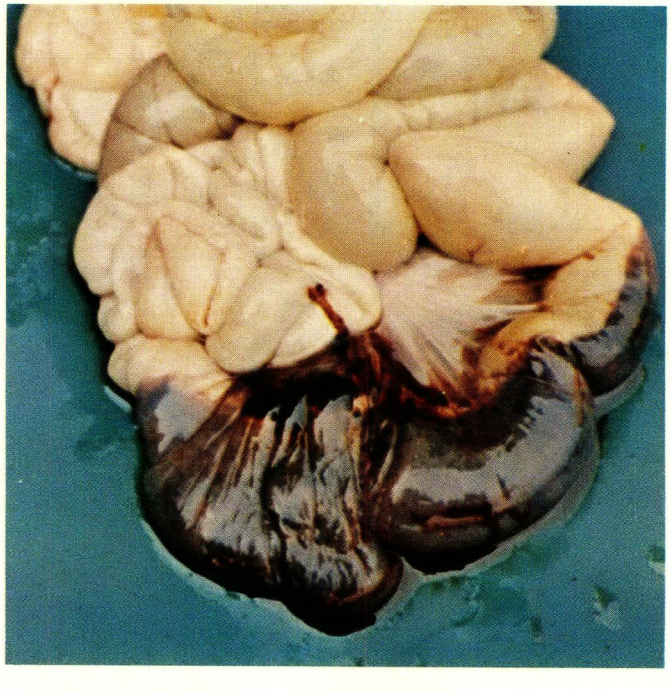



PLATE 502: NORMAL LYMPHOID FOLLICLES

Scattered throughout the colon are numerous 1-3 mm. opaque, pale foci which are normal solitary lymphoid aggregates. There are several more concentrated areas of lymphoid foci in the gastrointestinal tract located in the mucosa of the distal ileum and the mucosa of the colon near the ileocecal junction. All of these are often erroneously considered lesions by the neophyte.

PLATE 503: RECTAL AND VAGINAL PROLAPSE

Both the rectum and vagina have prolapsed several centimeters. Most cases of rectal prolapse are associated with diarrhea or chronic straining as from an anomaly of the rectum or an intrapelvic irritation. In older animals, a vaginal prolapse is usually associated with parturition. Automutilation or cannibalism sometimes partially cures the condition if it does not make it worse. Several outbreaks of this have been linked to dietary factors in both dogs and pigs.



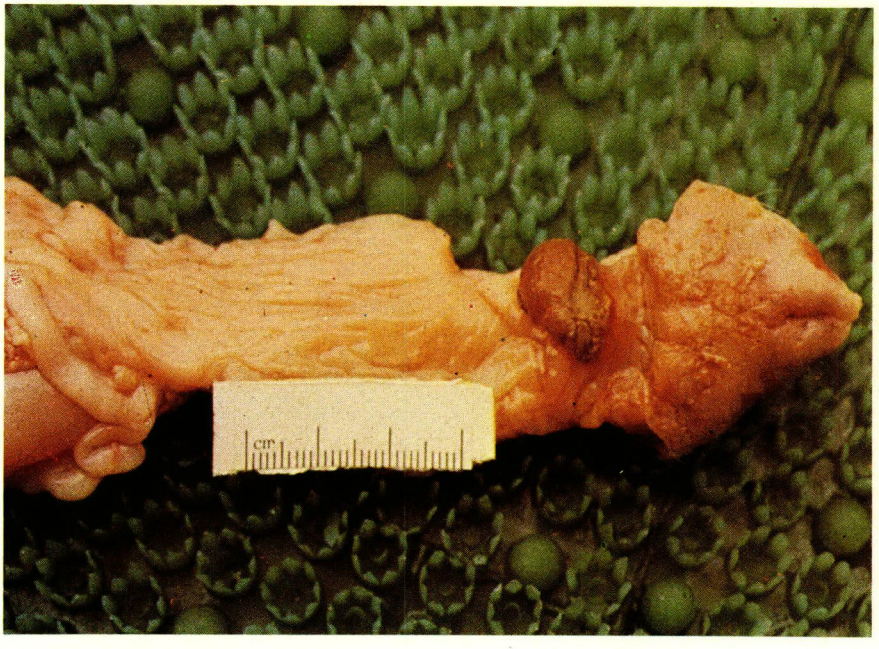

PLATE 504: RECTAL POLYP

The 1 x 1.5 cm. brownish mass located between the normal pale rectal mucosa and the slightly swollen vulva about 1 cm. cranial to the swollen anal ring is an edematous projection of rectal mucosa (polyp). The surface of the polyp is brown from congestion, hemorrhage and necrosis as the polyp itself was partially exteriorized in vivo. The constant irritation it caused made the anus and surrounding tissues edematous. The cause of the polyp is not known, but any anal irritation may cause a partial prolapse with this as a sequelae. Diarrhea or trauma may be suspect. In older animals, a mucosal or smooth muscle tumor should be considered. A tissue mass (polyp) projecting into a lumen of any sort may be seen in many locations such as the nasal cavity, stomach, urinary bladder or trachea to name a few.

PLATE 505: DIVERTICULOSIS

Two and a portion of a third outpocketings from the intestine are shown here in this hereditary defect problem in a pig. They are recognized as bulges of the entire intestinal wall with their own lumen continuous with the main bowel lumen. In this way, they may fill with ingesta, get infected as they may not empty and finally perforate to cause peritonitis, more often localized than generalized. Individual diverticuli may be found in any hollow organ, even the eye. They are not uncommon in several species in the distal esophagus and distal ileum.

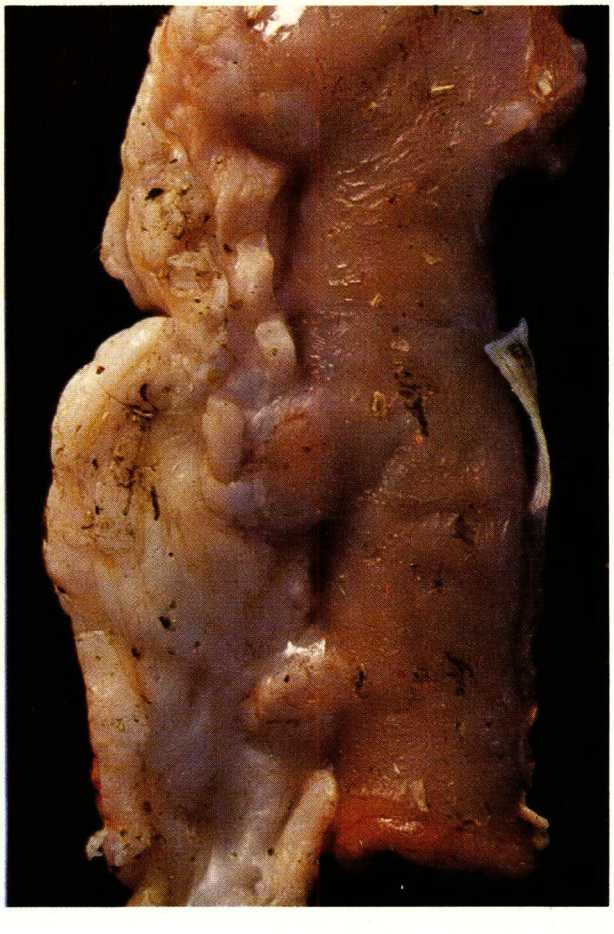

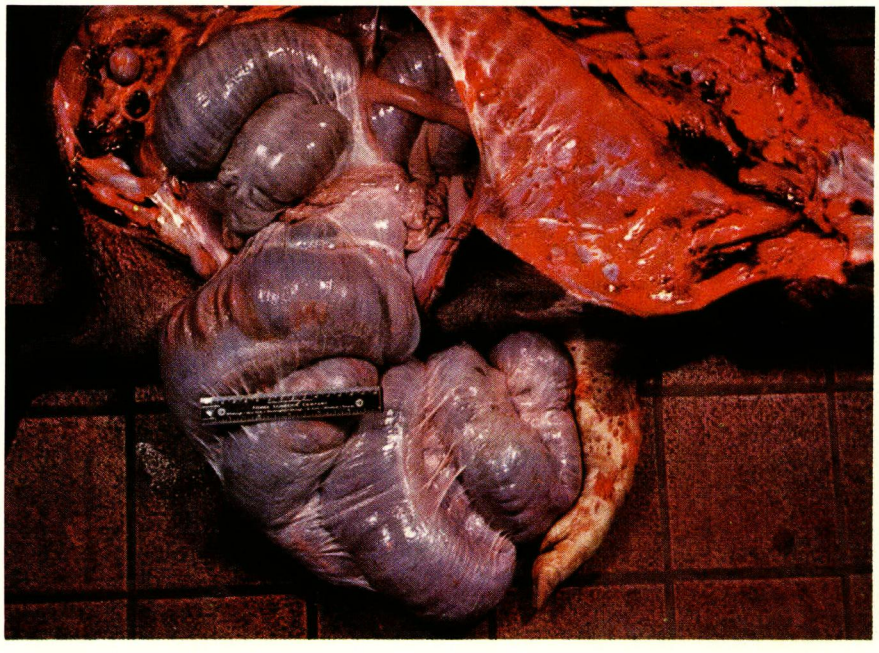

PLATE 506: MEGACOLON

This massively distended colon is filled with a pasty to dry, grey feces. Before being necropsied, the animal was very thin with an enlarged abdomen. Such a lesion is usually associated with an anal or rectal anomaly preventing fecal passage. It is surprising that some pigs, especially those on a nonroughage diet such as milk, may often live weeks or even months with this problem. Control by the use of "drastic slaughter" (castration of all relatives including mother, father, brothers and sisters) should be implemented to prevent more cases of this and similar diseases.

PLATE 507: ATRESIA COLI

The distended proximal portion of rectum ends as a blind stump. A small fibrous tag of tissue about 1 cm. long connects it to the caudal 8 cm. portion of rectum which itself is relatively small from disuse. This type of atresia may represent the segmental defect form of atresia in which a segment of bowel was not present embryologically.

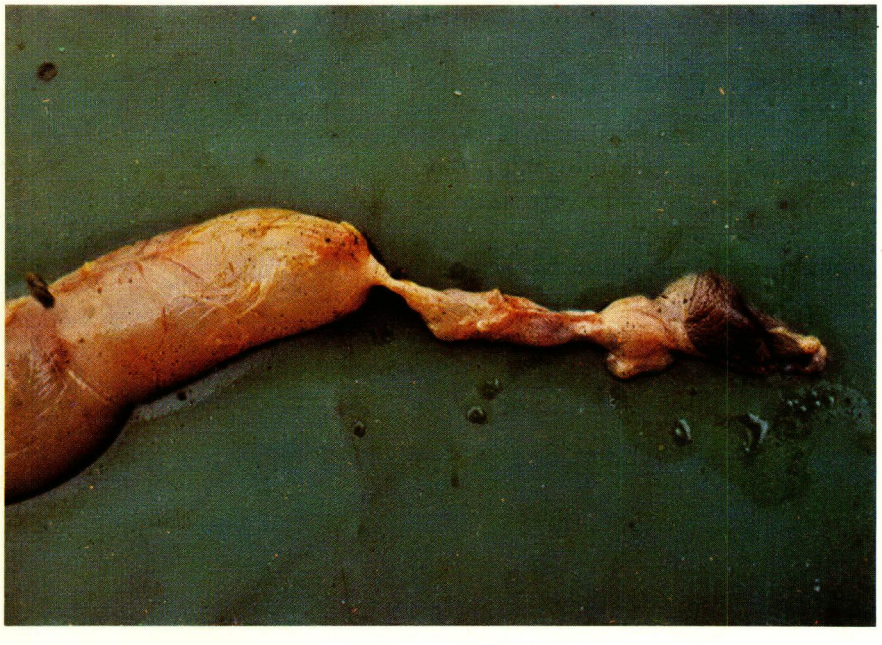



PLATE 508: ATRESIA COLI

The proximal segment of colon is markedly dilated (megacolon) and near the anus, the colon is constricted by connective tissue. A large patch of mucosa is absent from the colon proximally to this area of constriction, but histologically the muscle coat and some submucosa is still present making this an example of epitheliogenesis imperfecta of the colon and not a segmental defect.

PLATE 509: ATRESIA COLI

The anal ring and distal area of the colon are normal but lead to a constricted area of scar tissue in front of which the colon is greatly dilated. The colon is lacking epithelium in the zone immediately adjacent to the stricture. This is an example of epitheliogenesis imperfecta with this patch of mucosa absent allowing for inflammation and subsequent constriction (atresia) of the colon in this area.



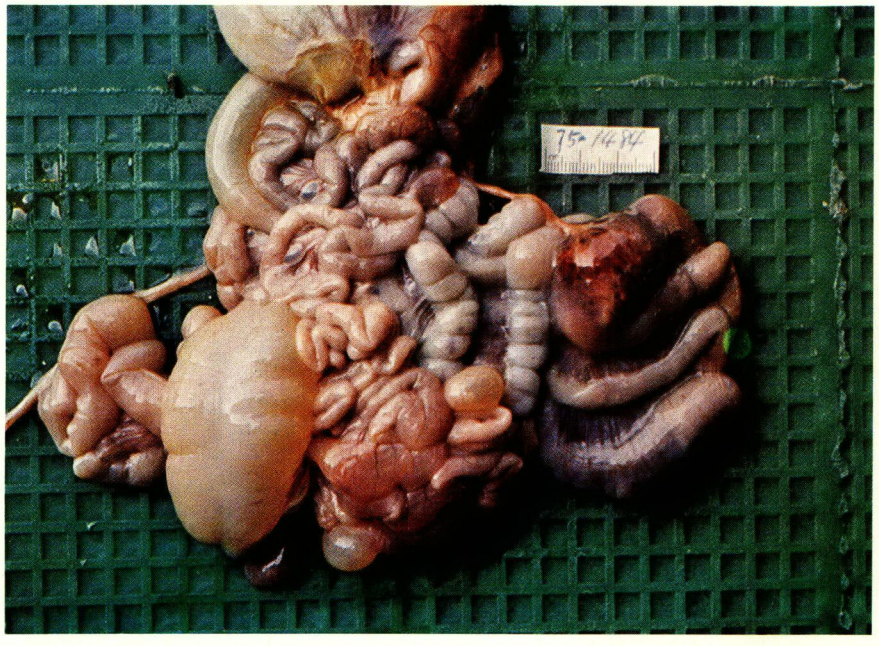

PLATE 510: COLON OBSTRUCTION

A 3 cm. red area in the spiral colon is seen with a connective band, a piece of omentum, running up to the root of the mesentery. The distal portions of colon in this spiral colon are reduced in size being relatively empty, and the portions cranial to the obstruction are dilated with ingesta and fluid. The major mass of small bowel is gas filled. The obstructive mass in this piglet is a firm lump of dry powdery feces (fecalith). Fecaliths made of hair (tricholiths, trichobezoars, hairballs) or plants (phytobezoars, phytoconcretions) are often seen in animals. Sand and plant concretions are common in horses; hair, milk strainers and masses of excelsior are common in cats and rubber balls and baby bottle nipples are common findings in obstructive lesions in dogs. Upper gastrointestinal obstructions often prove fatal much sooner than lower bowel obstructions.

PLATE 511: INTESTINAL STRANGULATION

One portion of this horse's intestine and mesentery is markedly congested and edematous while the other portion is remarkably unaffected. Attached to the mesentery near the line of demarkation is a 4 cm. mass of soft fat in a pocket of peritoneum. This mass of fat is called a pedunculated lipoma and it had encircled the portion of bowel to cause the strangulation. The pedunculated lipoma is not a true tumor, but it is a outpocketing of peritoneum which may arise on almost any organ in the abdomen and enlarges with the accumulation of fat. Sometimes the lipomas twist on their pedicle, become necrotic and calcify. Pedunculated lipomas like these are most commom in the horse, but they also occur in the cow. The lipomas in the dog are commonly found in the subcutaneous tissues of the neck and chest. There is some discussion about the true nature of lipomas in dogs. Of course, in all species, true neoplastic fat cell tumors, liposarcomas, are found.

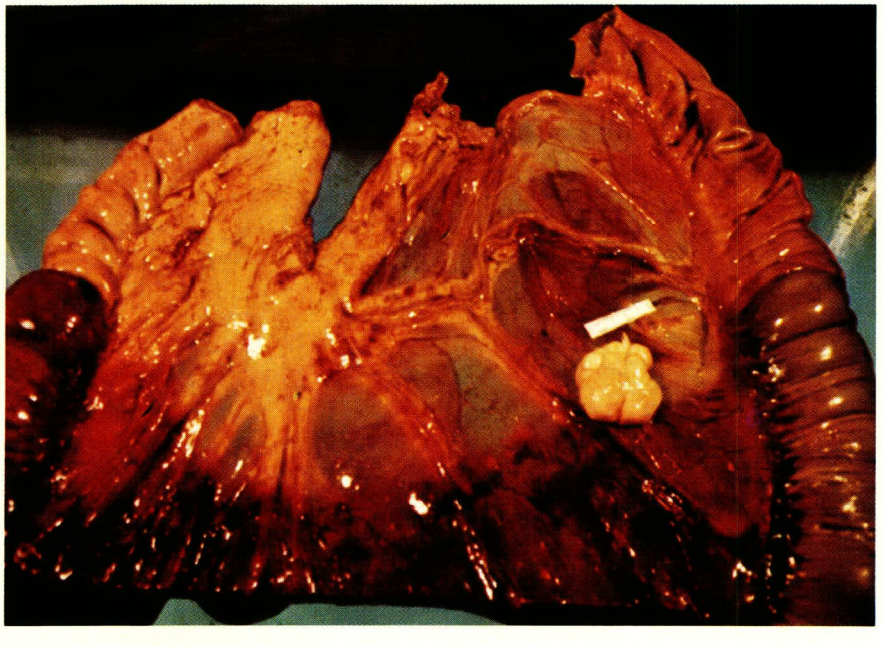

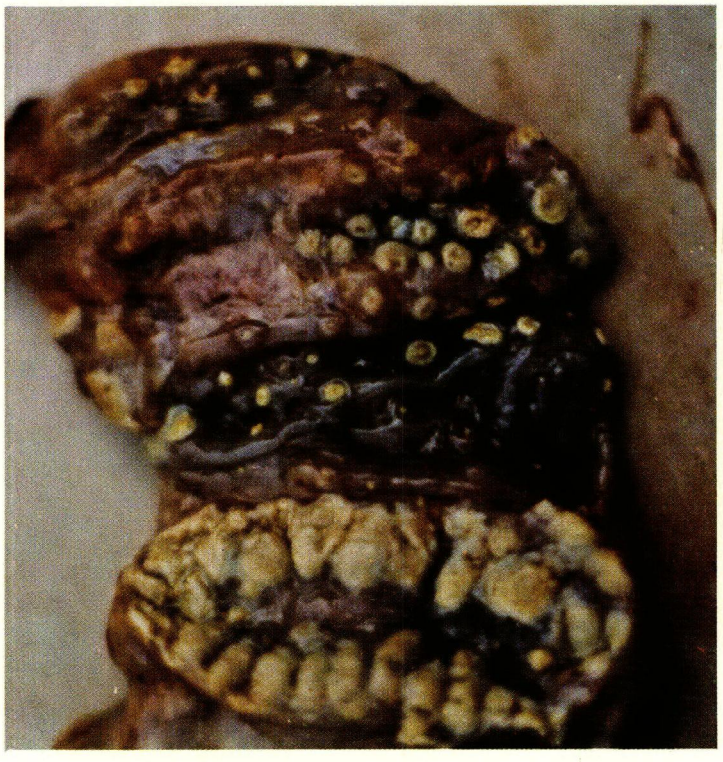

PLATE 512: BUTTON ULCERS

In the mucosa of this spiral colon are multiple, circumscribed, necrotic ulcers which are quite characteristic for Salmonella spp. infections and often associated secondarily with hog cholera. A few ulcers of this type may be found in normal pigs about the ileocecal junction in both the ileum and the colon.

PLATE 513: LYMPHOID FOLLICLE NECROSIS

The relatively normal epithelium is separated from the necrotic follicle by the crypt wall. The central surface area of the follicle shows caseation necrosis and the surrounding area has lost most of its lymphoid cells. The dark zone of cells between the two areas is the pyogenic membrane consisting mainly of neutrophils. This lesion grossly is an acute button ulcer of salmonellosis associated with hog cholera.

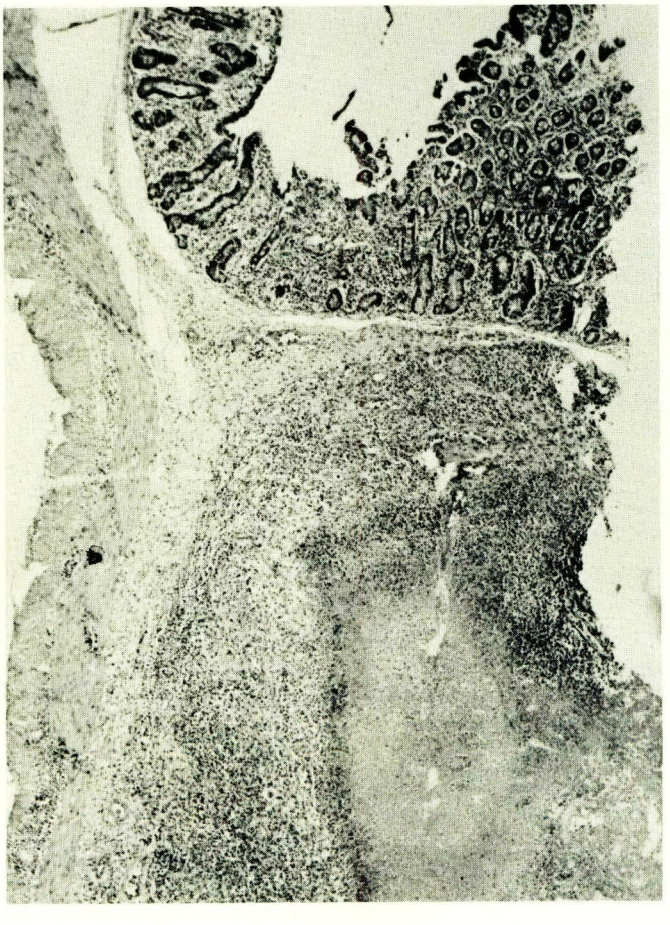



PLATE 514: SUBACUTE BUTTON ULCERS

The rounded knob, with several indentations on its surface at one edge of the picture, is the ileum as it projects into the cecum. Starting in this region, the aggregated lymph nodules (Peyer's patches) are enlarged with a swollen and congested periphery and a dark central depression of necrosis and some hemorrhage. In most of these cases of hog cholera, a virus disease, one can often isolate Salmonella spp. from the affected lymph nodules. They may also be seen in essentially normal pigs, but not usually as severe or extensive as this.

PLATE 515: EDEMA OF THE SPIRAL COLON

The watery material in the soft tissues between the loops of spiral colon is edema. In pigs with acute death and other compatible lesions such as eyelid and gastric wall edema, one should first think of edema disease of swine which is associated with an acute E. coli infection. This lesion may also be seen in cases of heart failure, from anomalies or chronic pericarditis with passive congestion of the abdominal vessels or in hypoproteinemias from any cause such as from bleeding gastric ulcers.



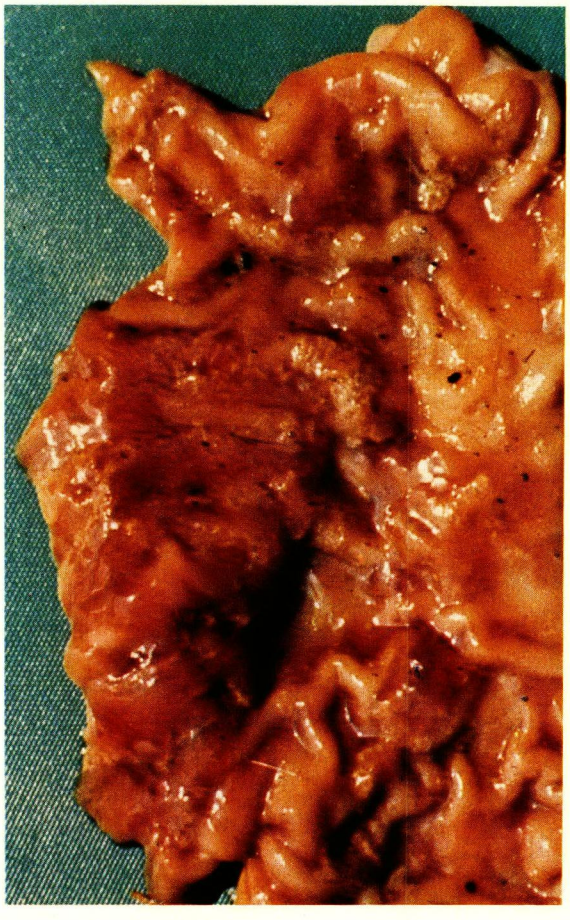

PLATE 516: MUCOHEMORRHAGIC COLITIS

This colon shows excess production of mucus and a catarrhal enteritis. These are the classical lesions of swine dysentery and are seen only in the colon. The mucus contains a large number of spirochetes, Treponema hyodysenteriae.

PLATE 517: MUCOHEMORRHAGIC COLITIS

Mucus mixed with inflammatory cells is on the surface of the mucosa. The epithelial cells at the extremities of the villi are slightly necrotic. The mucosa is congested. There is excess mucus in the crypts with infiltration of inflammatory cells into the lamina propria. The crypt epithelial cells are hyperplastic. This is from a pig with swine dysentery.

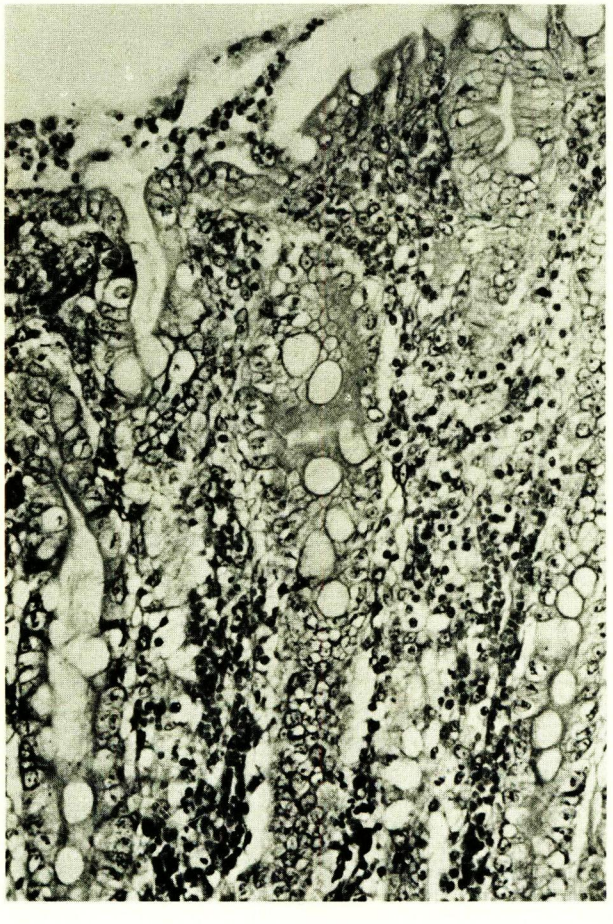



PLATE 518: FOCAL NECROTIC COLITIS

Several scattered, distinct, pale white plaques can be seen through the serosa in the wall of the colon. Several have been incised to show the thickened wall with yellowish, necrotic, crater like mucosal surfaces. A few have penetrated deep enough to cause a focal peritonitis. Hemorrhage and edema are noticably absent. The intestinal content was watery with bits and pieces of necrotic debris and it had a definite septic tank odor. Salmonella spp. was isolated. Some confusion with this disease and swine dysentery is common and not always separable grossly.

PLATE 519: NECROTIC COLITIS

The small length of ileum attached to the cecum is normal. The cecum is physiologically hyperemic as is the distal rectum and several scattered foci of distal colon. The remaining colon however is markedly thickened with congestion, edema and necrosis of the mucosa, which in several areas, has caused a marked inflammation of the muscle layer and serosa. Much of the necrotic mucosal surface has a dull greyish appearance. This is a case of subacute swine dysentery, a spirochetal disease caused by Treponema spp.

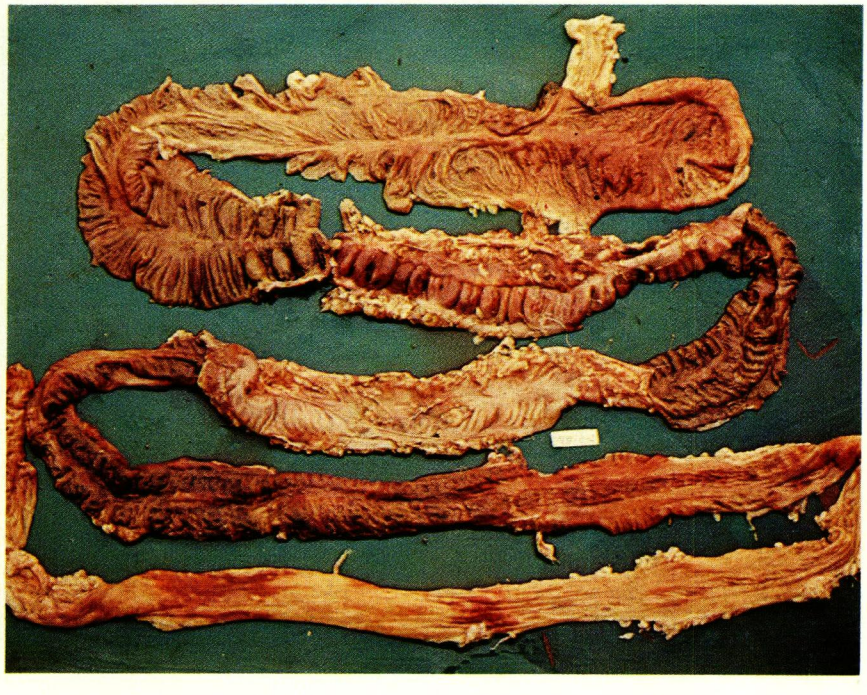

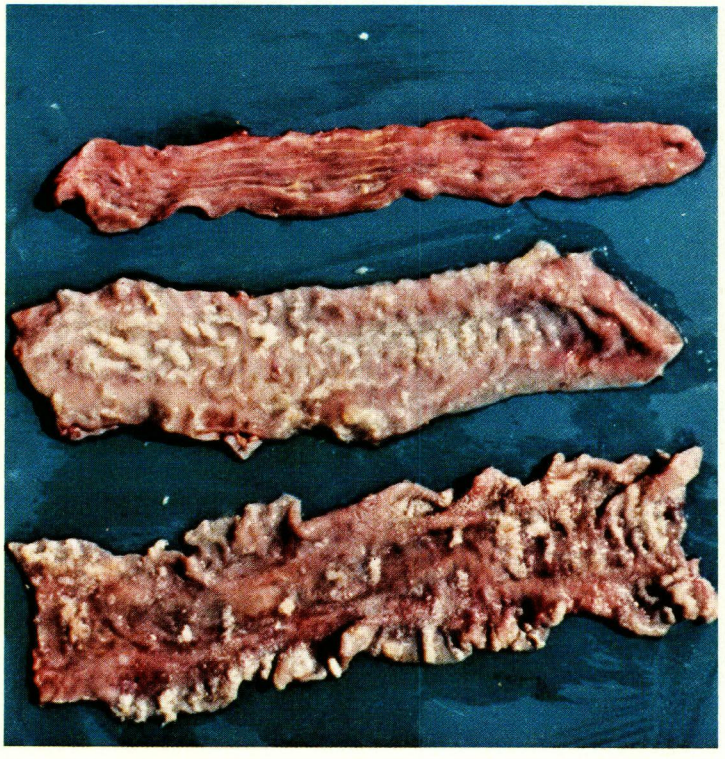

PLATE 520: NECROTIC COLITIS

The two sections of large intestine show multiple foci of yellowish necrotic debris attached lightly to the congested mucosa in a wavelike pattern in some of the areas. The unaffected congested ileum is the smaller bowel section. In some cases, the bowel is not greatly thickened or abnormal on its serosal surface and only incision of the bowel will demonstrate the lesion. This is a case of swine dysentery caused by Treponema spp.

PLATE 521: NECROTIC COLITIS

In this case of swine dysentery caused by Treponema spp., the colonic sacculations show the wavelike pattern of surface necrosis while deeper in the sacculations the mucosa is apparently normal. A copious foul smelling diarrhea with only a few strings of clotted blood was present. It should be noted that some cases are far more hemorrhagic and may actually bleed the animal to death. While most pigs have diarrhea with this disease, there are some with such a fulminating form that they may die from the colitis without time for the diarrhea to develop.

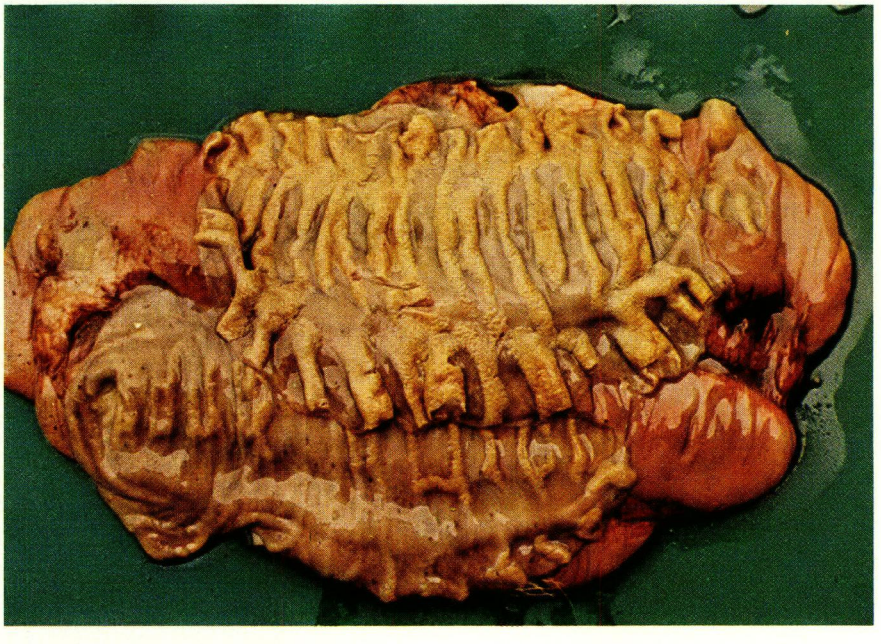

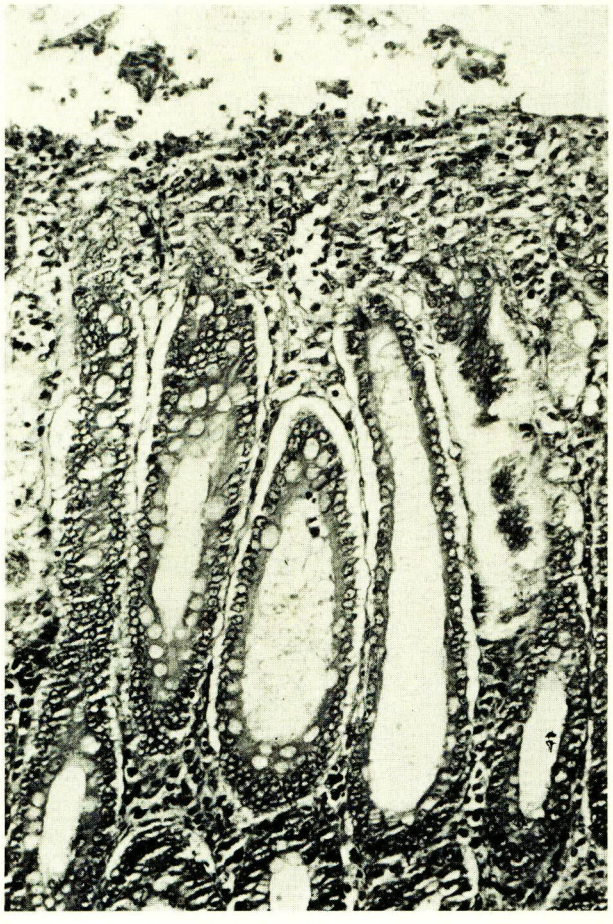

PLATE 522: SWINE DYSENTERY

The colonic crypts are dilated and one near the edge has lost its epithelium and contains strands of fibrin and cellular debris. Many neutrophils and much cellular debris are located in the more superficial mucosal layer but the surface epithelium has been lost by necrosis in this early stage of the disease.

PLATE 523: SWINE DYSENTERY SPIROCHETE SMEAR

Numerous spiral organisms, Treponema spp., and smaller, blunter organisms are present in this stained smear of the colon content of a pig with swine dysentery.

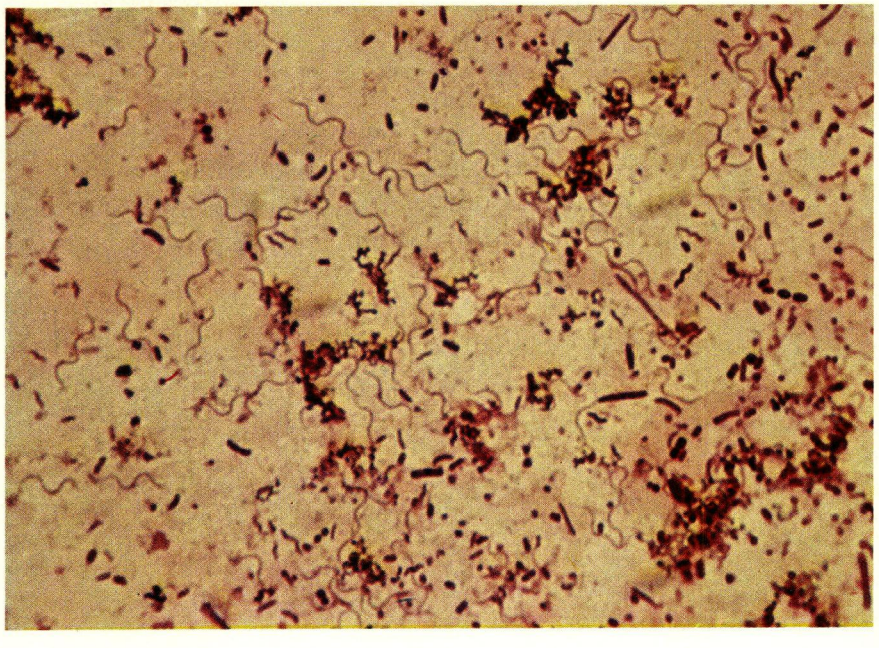

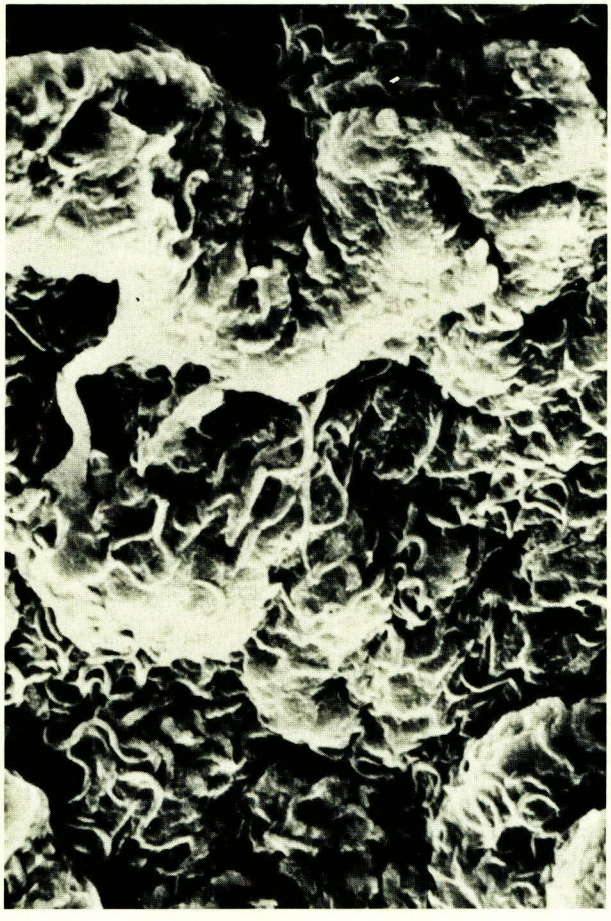

PLATE 524: SPIROCHETES OF SWINE DYSENTERY

This is a scanning electron microscopic photograph of the spirochetes on the mucosa of a pig with swine dysentery. These spiral organisms are Treponema hyodysenteriae.

PLATE 525: NECROTIC COLITIS

Grossly, this was one of many button ulcers in the colon of this pig. The many inflammatory cells in the ulcerated area and also in the debris on the surface have several large, single celled, ciliated protozoa mixed in with them. These are Balantidium coli. Most consider them an incidental finding in necrotic colitis caused by Salmonella spp. as they are common gut inhabitants in many animals.

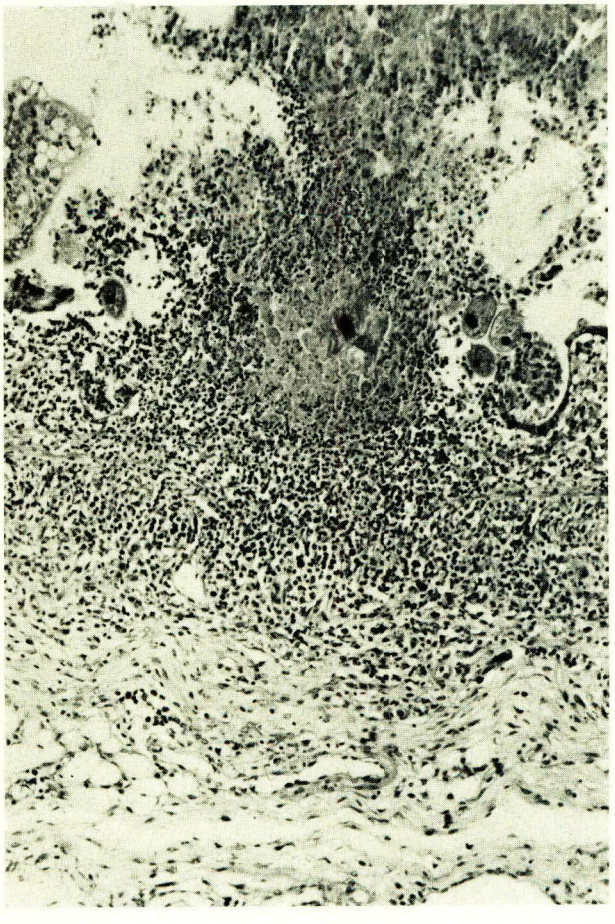



PLATE 526: TRICHURIASIS

Large numbers of whipworms, Trichuris spp., are attached to the mucosa of this colon. In most subclinical cases, the parasites are usually limited to the cecum. In clinical cases with diarrhea, they may be found throughout the colon. Other than the parasites themselves, there is usually no gross lesion in the gut. In cases of parasitism, there are some who use the term infestation when no clinical signs are observed and infection when signs are observed.

PLATE 527: TRICHURIASIS

Three sections of whipworms are embedded in the most superficial epithelium without appreciable tissue reaction. Deeper in the mucosa are scattered clumps of chronic inflammatory cells which appear to be extruding from the submucosal lymphoid follicles and probably are not related to the parasitism.

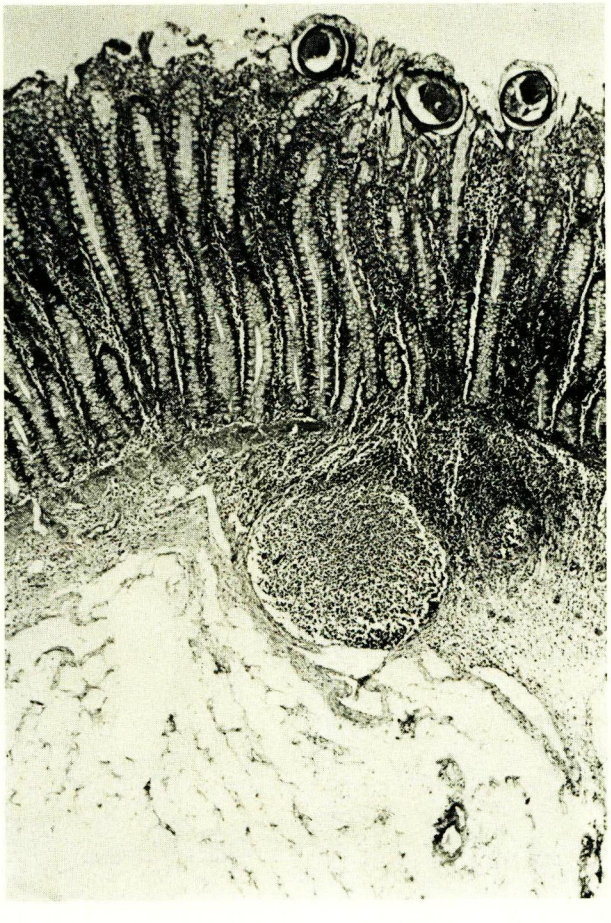

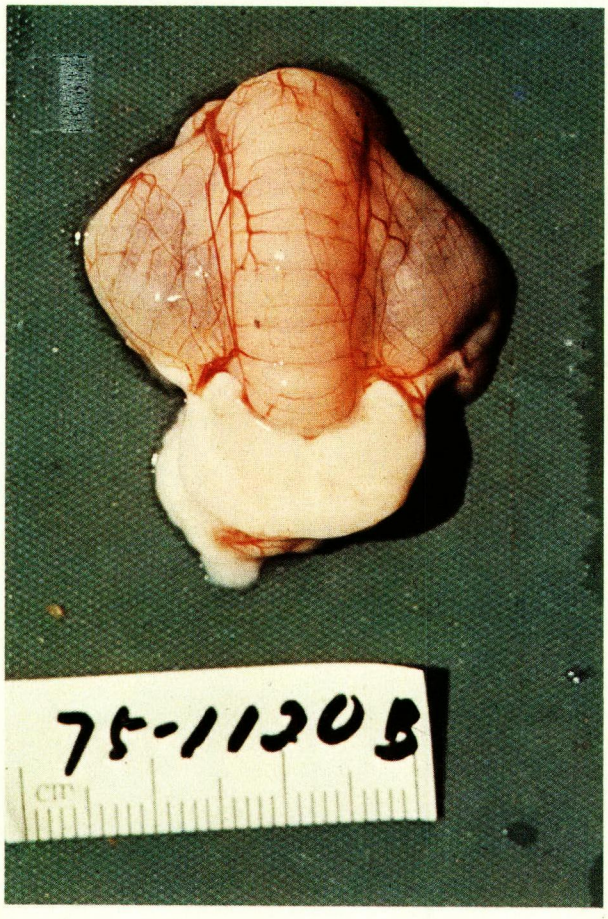

PLATE 528: MELANOSIS

Both lateral hemispheres of the cerebellum have a definite greyish appearance from melanin deposition in this Hampshire pig. This is a normal finding especially in black and white pigs, but may be seen in others. Its appearance is to be differentiated from pseudomelanosis which does not affect the brain usually and is a postmortem artefact.

PLATE 529: MELANOSIS

Bilaterally in this sheep's brain stem are well marked areas of black pigmentation of normal melanosis. The brain and meninges as well as the lung, aorta, adrenals, uterus and stomach are common areas for this normal congenital melanosis in most species of animals. It is to be differentiated from the pseudomelanosis which is a postmortem artefact of blood in association with bacteria. This specific finding in the brain of sheep has been mistaken for a lesion of a plant poisoning.

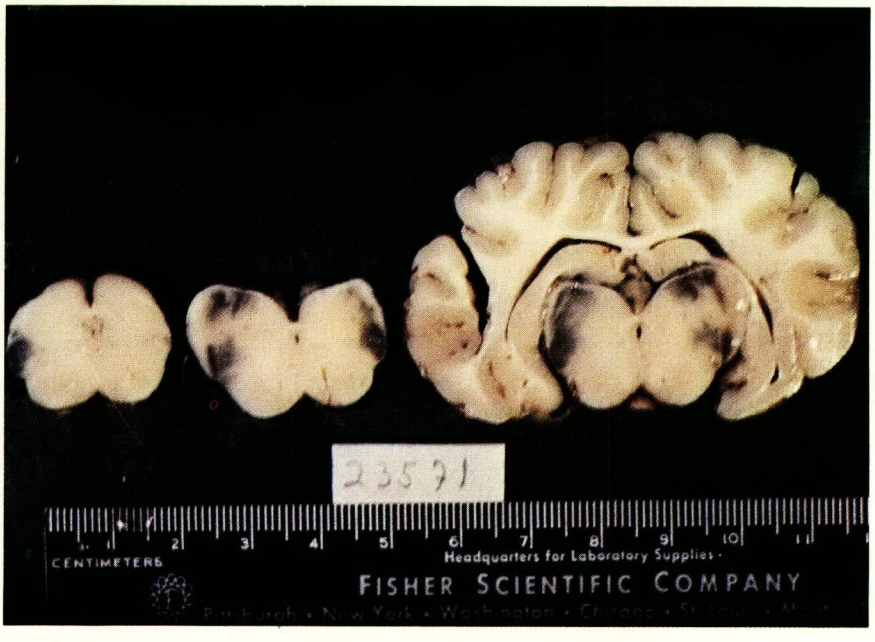

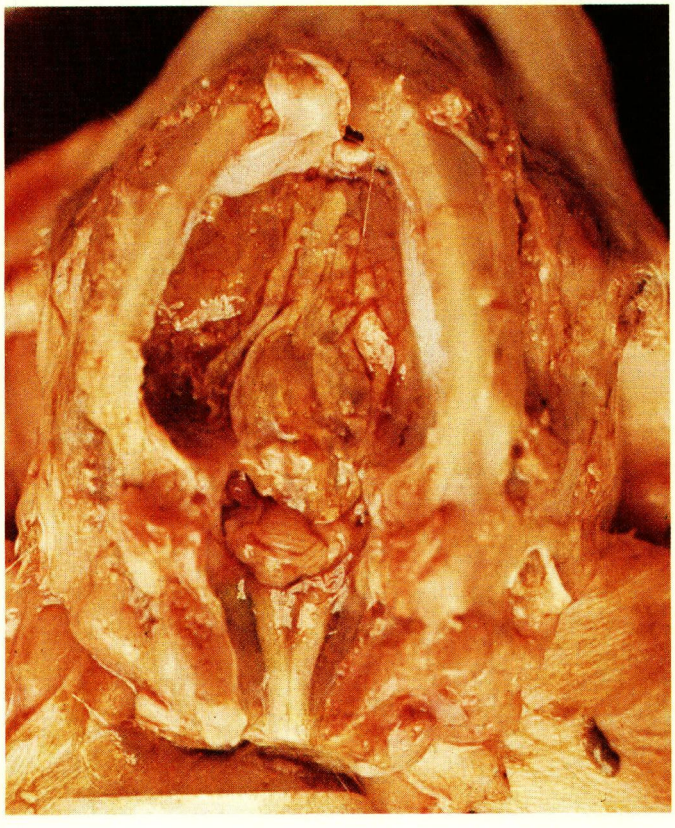

PLATE 530: HYDROCEPHALUS

Only the reduced size cerebellum, the medulla and a small portion of cerebrum with meningeal vessels can be recognized in the cranial vault. The remaining cerebrum is barely seen as a collapsed sac of tissue. Japanese B encephalitis virus was isolated from this newborn piglet.

PLATE 531: ENCEPHALOMALACIA

This one gyrus of the cerebrum shows a vacuolated central area in the white matter with only a few strands of fibrillar material running through the space. The remaining parenchyma is hypercellular and somewhat distorted. Such a lesion is nonspecific and can be seen in any tissue destructive lesion as infarcts, hydrocephalus, trauma, infections, etc.. This can be one stage in abiotrophy.

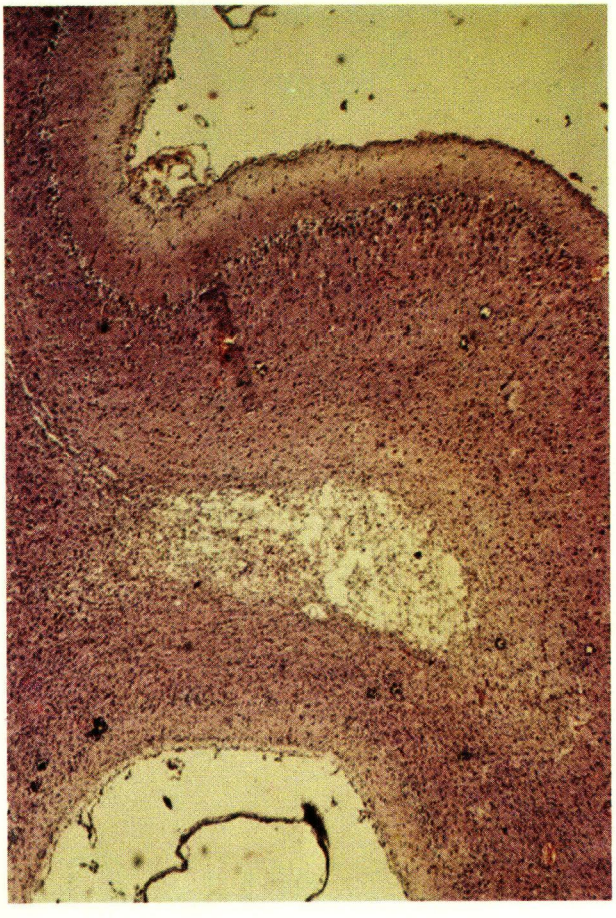



PLATE 532: CYCLOPS

The large median cystic structure is a malformed single eye and the tube like structure above it is the proboscis. The tongue is turned upward beside the fleshy upper jaw. All degrees of this anomaly can occur. This is a common anomaly in pigs.

PLATE 533: PARTIAL ANENCEPHALY

The cerebrum is absent (cerebral aplasia) and only the corpora quadrigemini and cerebellum are present in this cycloptic piglet. Such anomalies are often related to in utero induction by viruses, chemicals, defective genes, etc..

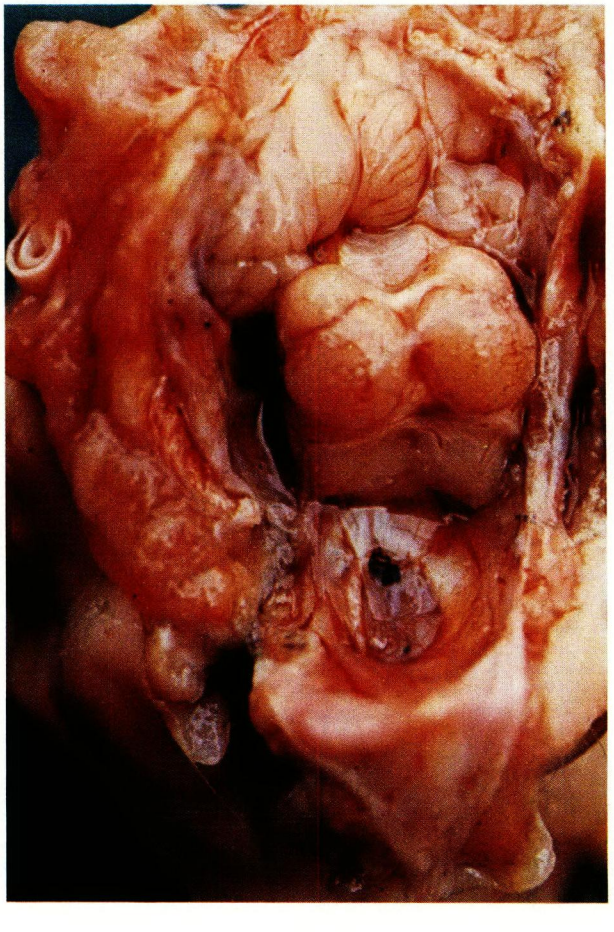



PLATE 534: PROLAPSED CEREBELLUM

Just above the slightly concave surface of the medulla some similar tissue, the medial vermis of the cerebellum, is seen. Normally, a slight empty space is in this area when the head is removed at the atlantooccipital articulation. An acute space occuping lesion such as an abscess, edema, or meningitis has caused the brain to swell and push outwards. Although brain tumors are space occuping, they usually grow too slowly for edema to develop and cause such a lesion.

PLATE 535: PROLAPSED CEREBELLUM

The darker brain and head are normal. The paler brain shows wider gyri and more shallow sulci of both the cerebrum and the cerebellum. In addition, the caudal ventral tip (nodulus) of the cerebellum is projecting outwardly and caudally (cerebellar coning). It had actually protruded through the foramen magnum when the skullcap was in place. Any space occupying lesion can cause this, but a brain or meningeal infection are the most common causes. Neither animal was bled out, but apparently the animal with the darker blood filled tissues died in a position with its head lower than the rest of its body to allow for this hypostasis.



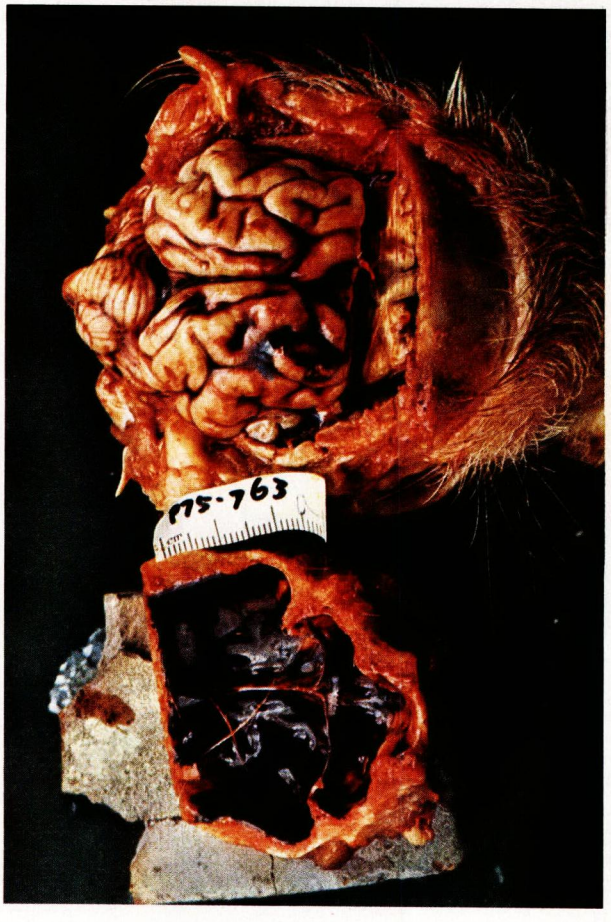

PLATE 536: DURAL HEMORRHAGE

On the inner lining of the skull cap and somewhat on the right cerebral hemisphere is a moderate amount of blood from trauma to the skull. This occurred at birth in this instance. Hypostatic congestion can sometimes be well marked but it will not leave large pockets or pools of blood on the tissue involved. In many cases, it is common to find no evidence of trauma on the skin or overlying skull.

PLATE 537: HEMATOMA OF THE BRAIN

The elongated pocket of hemorrhage (hematoma) on the floor of the right cerebral hemisphere is apparently traumatic in origin in this 100 Kg. pig. Part of the left hemisphere has been removed to show the lesion. Because of the hard cover of the brain, which in effect is a semifluid mass, a blow to the outside of the skull in one area often causes a rebound lesion such as this in the area of brain opposite the site of external contact. This is called "contra coup".

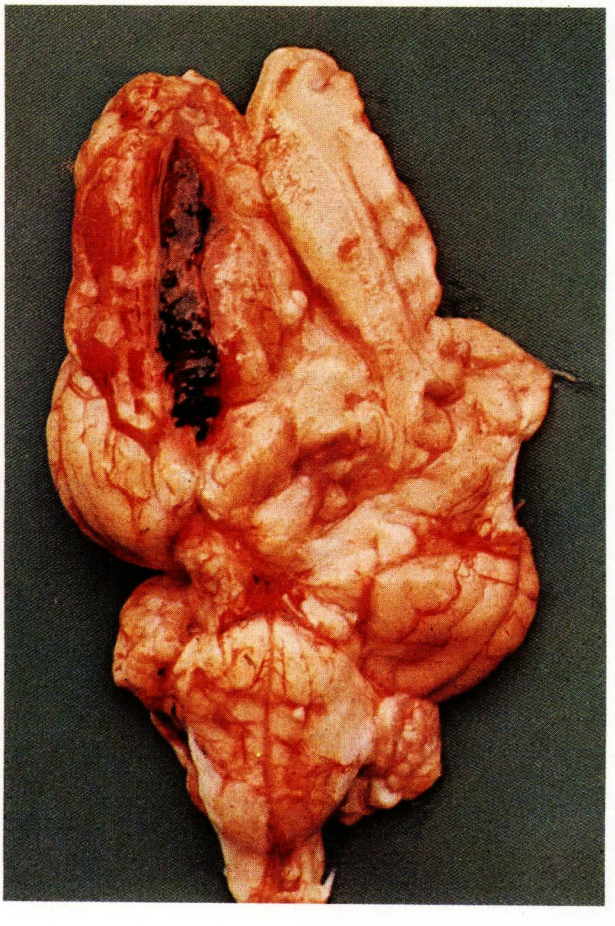

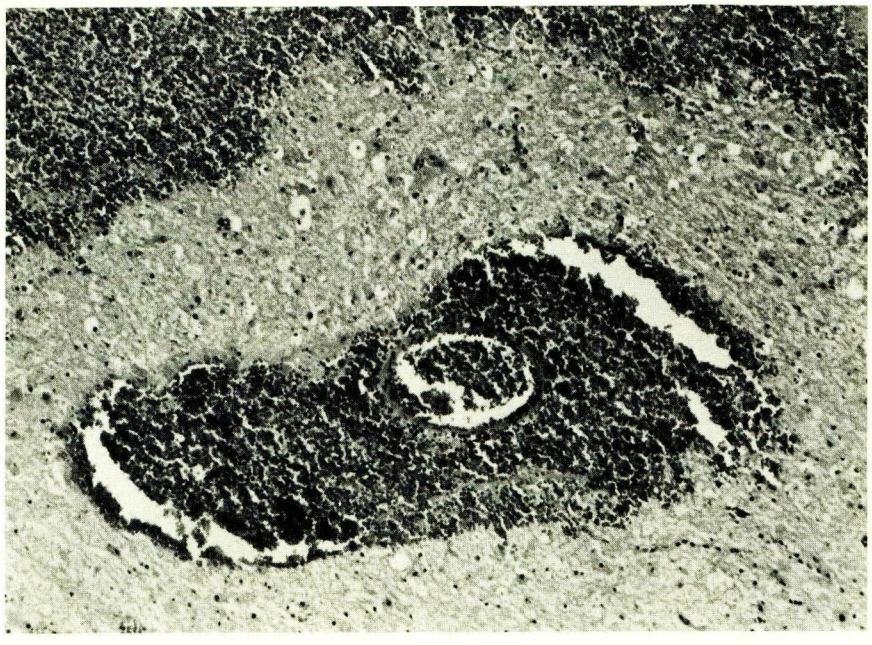

PLATE 538: PERIVASCULAR AND PARENCHYMAL HEMORRHAGE

The perivascular space is markedly dilated with blood and the parenchyma at one side is almost completely replaced by hemorrhage. As yet no cellular response has occurred as the animal died too soon. Such large areas of hemorrhage are usually traumatic, but smaller foci can be from capillary damage by viruses as in hog cholera. Bleeding diatheses may also cause such lesions, both large and small. Their clinical manifestations often depend on the area damaged.

PLATE 539: NEURONAL LIPODYSTROPHY

The black granules in the cytoplasm of this pig's neuron are lipid droplets stained with a special stain to demonstrate their lipid nature. This pig's disease is one of the newer types of disease problems that can be grouped under the heading of a congenital biochemical defect. In this case, an enzyme needed for the normal metabolism of lipids is deficient or absent. Similar diseases are seen in other species and most are considered hereditary in nature.

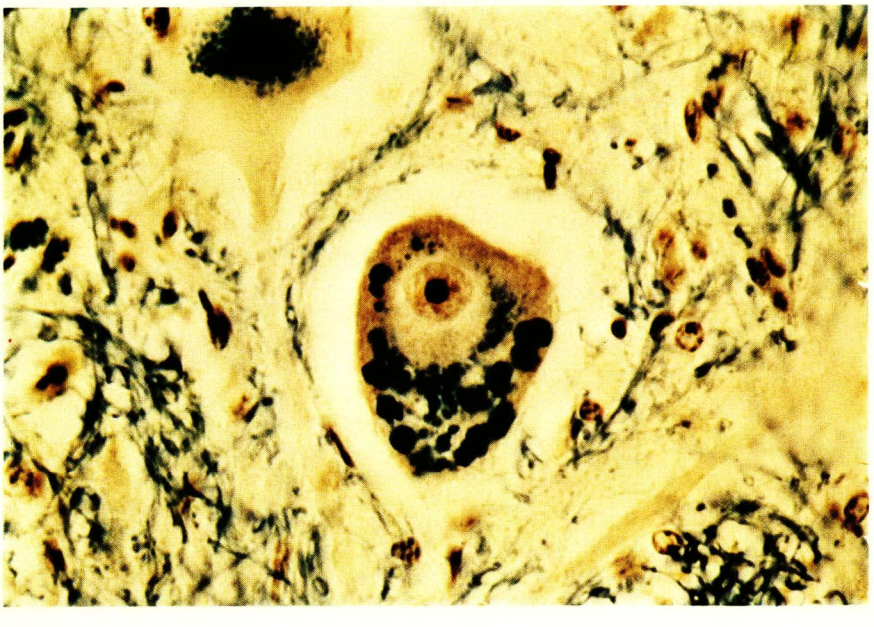



PLATE 540: CEREBELLAR AND CEREBRAL HYPOPLASIA

The abnormal brain shown here has a slightly reduced overall size, but the cerebellum is only about 1/5 normal size. The cavity in the anterior portion of the normal brain is an artefact. This failure of proper development has been shown to be caused by embryological viral diseases such as Herpes in the dog and horse, panleukopenia in the cat and hog cholera in the pig. In this case, the entire litter was affected with myoclonia congenita at birth and also had this lesion. No evidence for hog cholera in its dam's history could be found. This type of brain lesion is also called abiotrophy.

PLATE 541: HYDROCEPHALUS

Both lateral ventricles and the third ventricle are dilated (hydrocephalus). The corpus callosum is thinned more on one side than the other, and in general, one side is slightly more affected than the other. Many cystic spaces (porencephaly) in the grey and white matter are seen scattered in the remaining parenchyma. These spaces are the sequelae of encephalomalacia. It is to be noted that the more sensitive white matter is more severely affected than the grey matter. This day old piglet was infected in utero with the virus of Japanese B encephalitis.

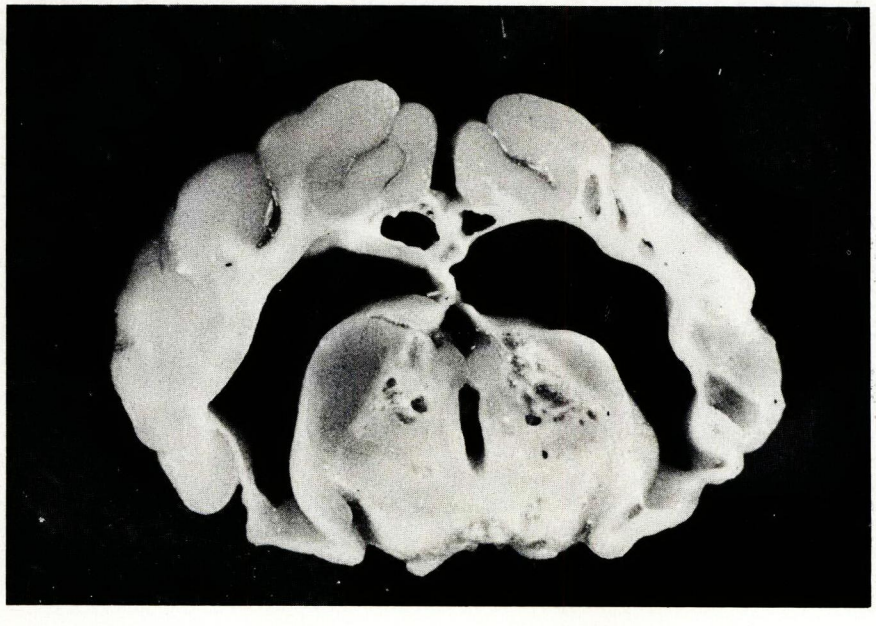

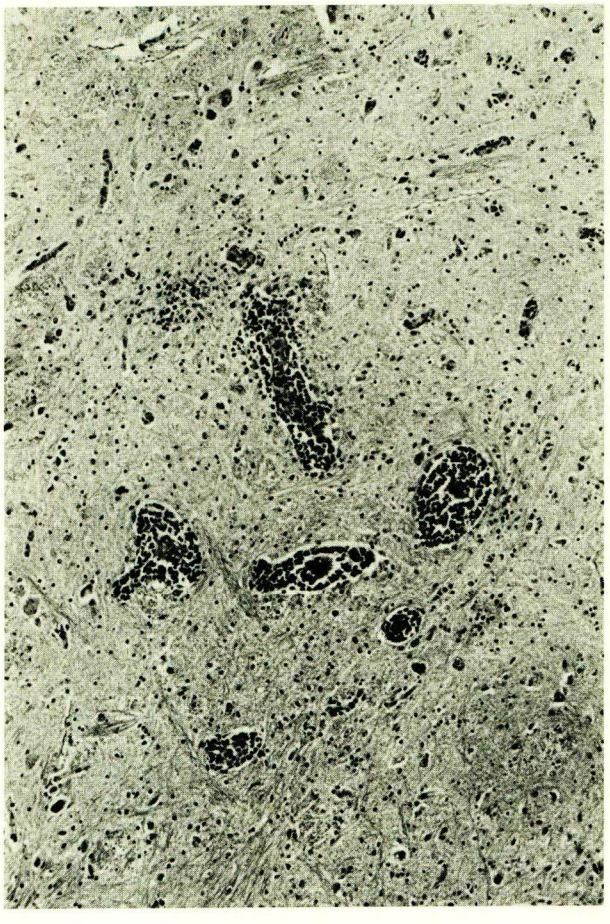

PLATE 542: PERIVASCULAR CUFFING

Several longitudinally cut vessels and a cross sectioned one show a number of round cells about them. Histologically, most of these cells are lymphocytes making this part of a non-suppurative encephalitis. This is from a case of hog cholera.

PLATE 543: NONSUPPURATIVE ENCEPHALITIS

This large clump of round cells in the pia mater consists mainly of mononuclears mostly lymphocytes, monocytes and plasma cells. The lack of neutrophils helps differentiate this viral disease from the suppurative encephalitides usually caused by bacterial agents. Almost any of the viral agents could be involved in this case as it is not a diagnostic lesion by itself.



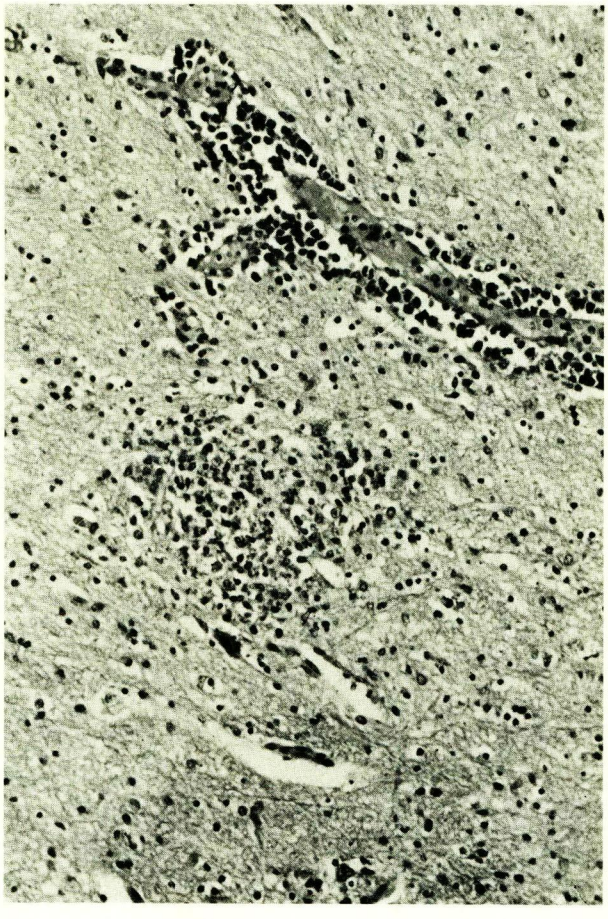

PLATE 544: PERIVASCULAR CUFFING AND GLIOSIS

This large infiltration of small round cells (cuff) about the vessel consists mainly of lymphocytes. A distinct focus is seen to one side of, not actually associated with, the vessel (gliosis). These represent a nonsuppurative encephalitis which in this case is pseudorabies (Aujeszky's disease). Most of the other viral diseases of the brain may make a similar lesion.

PLATE 545: NONSUPPURATIVE ENCEPHALITIS

This large accumulation of imflammatory cells are mostly glial cells and chronic inflammatory cells such as lymphocytes. There are more than the usual number of neutrophils present which is characteristic of pseudorabies (Aujeszky's disease) even though it is a viral disease. This is from a natural case in a piglet and is to be differentiated from hog cholera which usually lacks this neutrophilic response in its cuffs and glial nodules.

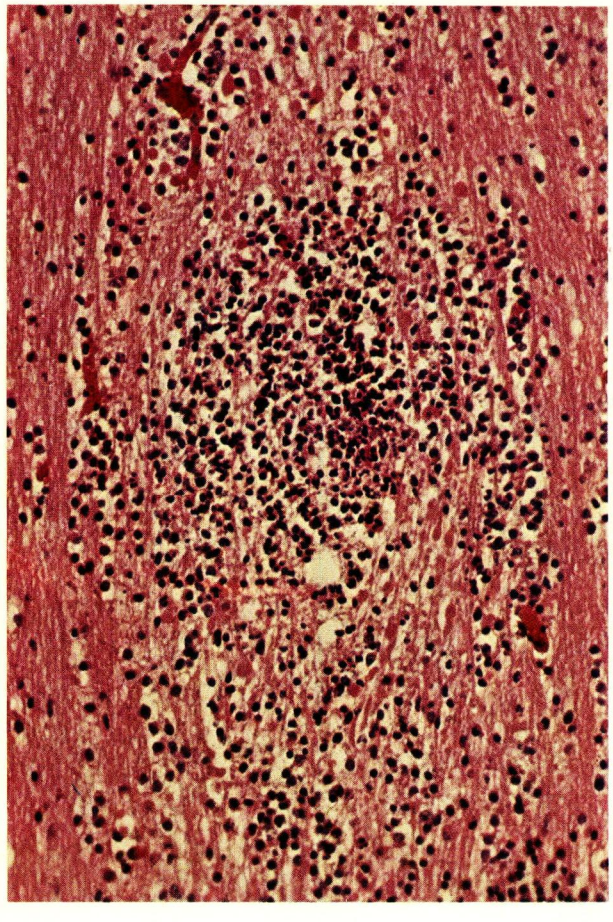



PLATE 546: NONSUPPURATIVE MENINGITIS

This triangular piece of pia mater is markedly infiltrated with round cells that at higher magnification were found to be mostly lymphocytes. A few round cells are also concentrated about one of the vessels in the parenchyma. Thus this can be labeled a case of nonsuppurative meningoencephalitis. The major portion of these are viral caused which is of differential value in separating such brain involvements from bacterial brain disease which are usually suppurative (purulent). The homogeneous material in the pia mater is serum and red blood cells. In most cases of a nonsuppurative encephalitis, there are no grossly recognizable lesions in the brain which again helps to differentiate them from bacterial diseases.

PLATE 547: INCLUSION BODIES

These distinctly reddish bodies in the cytoplasm of several neurons are the Negri bodies of rabies virus infection. A varying amount of nonsuppurative encephalitis often accompanies these inclusions. As the Negri bodies do not form early in this disease, it is best not to kill the animal, but to let it die for the largest production of the inclusions. Almost any neuron may have these inclusions but the Purkinje cells of the cerebellum and neurons of Ammon's horn are usually examined with the most profit.

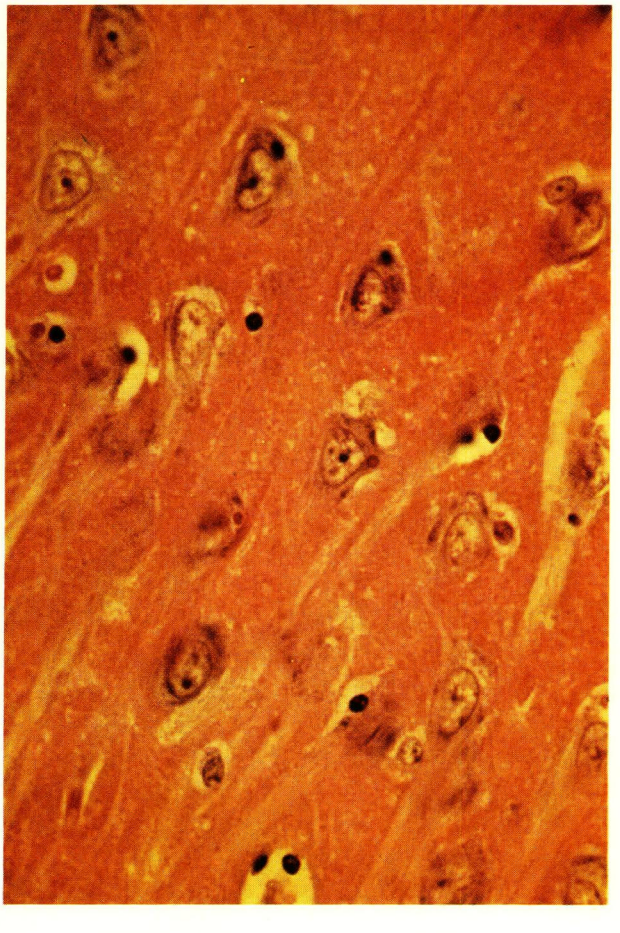

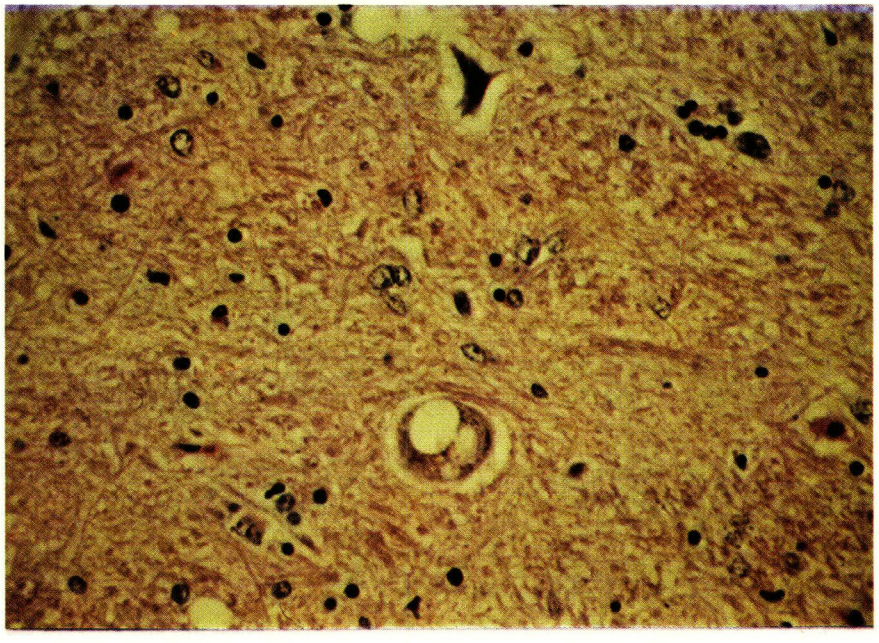

PLATE 548: NEURONAL VASCUOLIZATION

The single neuron with the three various sized, clear vacuoles is from a sheep with "scrapie", a virus disease. These may be found in various areas of the brain, but they are usually more common and sometimes limited to the medullary area. They may also be found as a diagnostic lesion of cholinesterase inhibition poisoning as vacuolated neurons in the ventral nucleus of the vagus.

PLATE 549: VASCULITIS

This large vascular lesion looks at first like a regular perivascular cuff. Closer observation shows it to be degeneration of the wall itself with many of the reactive cells being neutrophils. In some cuffs, not shown here, the reaction may involve only one segment of the wall and not its entire circumference. This is a case of swine vesicular disease (SVD).

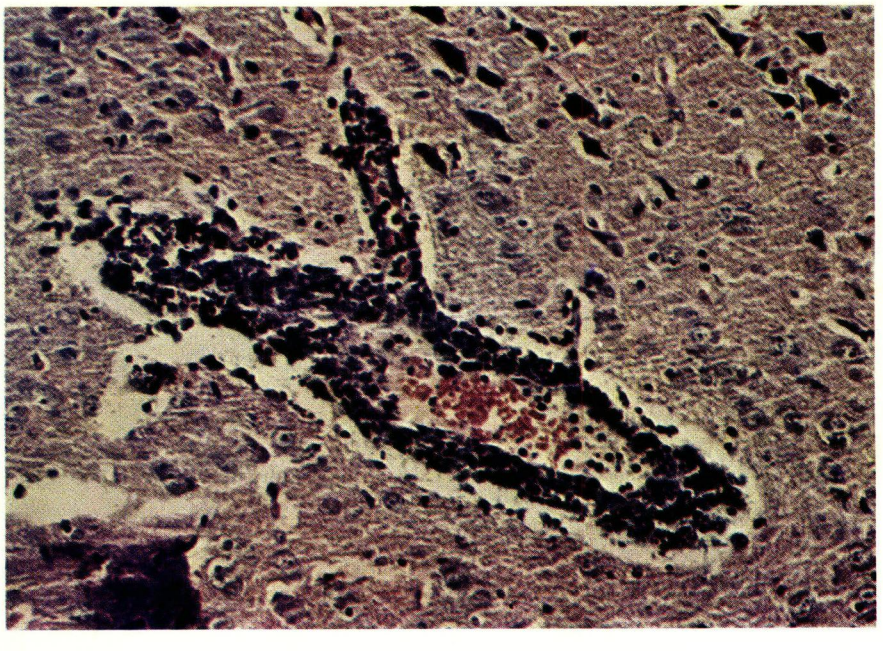

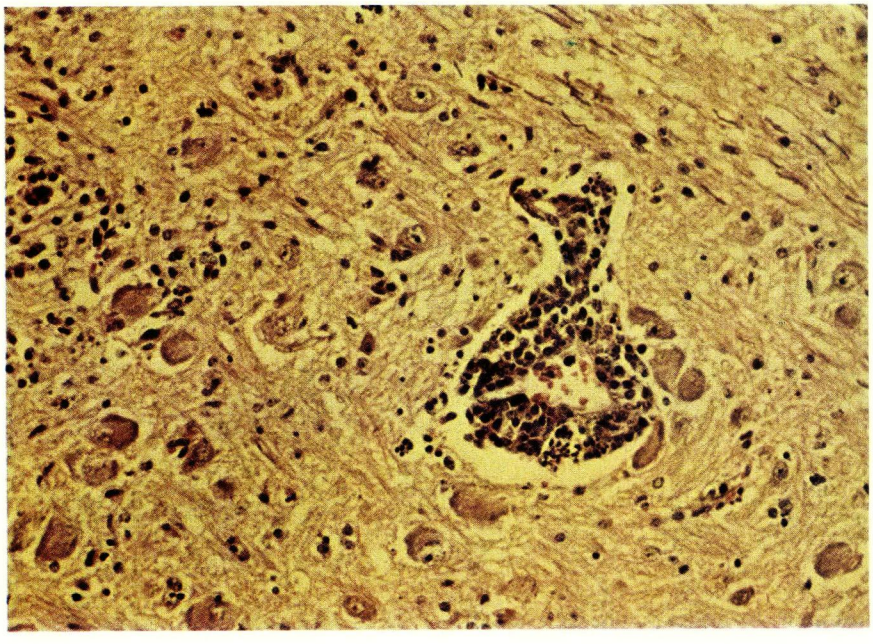

PLATE 550: VASCULITIS

This vessel shows a well marked cuff of round cells, but at both ends one can see a clump of small nuclear granules, the remains of neutrophils. The neutrophils should make one consider that this could be a bacterial infection or a viral disease that may stimulate more neutrophils than a viral disease usually does. Some types of equine encephalitis, pseudorabies (Aujeszky's disease) or swine vesicular disease should be considered in the various species. The fact that the vessel wall appears to be involved in a degenerative process suggests that this is an inflammation of a vessel and not just a perivascular cuff with neutrophils. This is a case of SVD.

PLATE 551: PURULENT MENINGITIS

The meninges of the cerebrum are glistening with edema and many petechiae are scattered among the congested vessels. On the meninges of the cerebellum are several patches of opaque white fibrin with several patches also on the meninges of the right cerebral hemisphere. This is a moderate case, as mild cases often have no grossly visible lesion on the surface and severe ones may be covered completely by a sheet of fibrin. Many septicemic organisms may cause this. If mostly ventral, an extension from a middle ear infection can be suspected.





PLATE 552: PURULENT MENINGITIS

The skull cap with the adherent dura mater has been removed leaving the pia mater with an opaque white appearance especially over the medial vermis of the cerebellum. An edematous, slightly cloudy appearance is seen over the occipital pole of the cerebrum. Histologically, a marked neutrophilic invasion along with much edema was present. Many organisms can cause such a lesion from septicemia or by direct extension as from a middle ear infection.

PLATE 553: PURULENT MENINGITIS (SUPPURATIVE MENINGITIS)

The pia mater on the surface of this brain is heavily infiltrated with inflammatory cells which on closer inspection were mainly neutrophils. While this was a case of polyserositis, almost any septicemic bacterial disease can cause it as well as extensions from local infections of the middle ear or the nasal cavity.

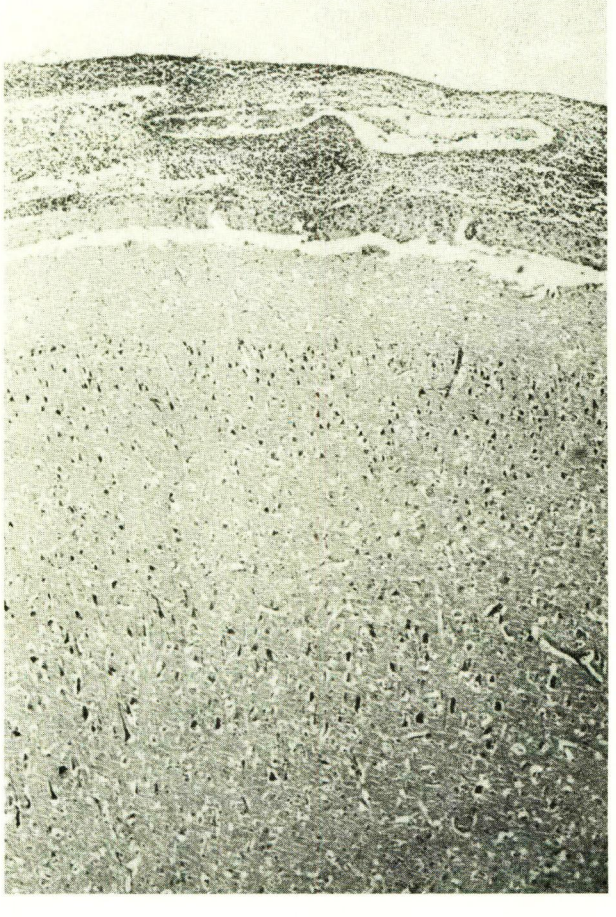

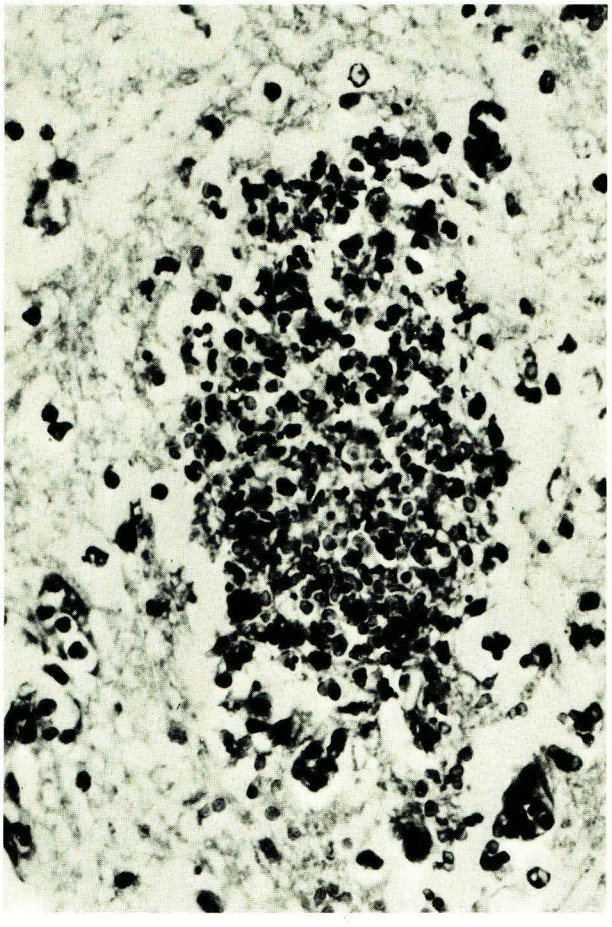

PLATE 554: MICROABSCESSTION

This clump of cells and debris is probably in a small vessel and might well represent a small embolic shower that has obliterated the vessel. The small dark nuclei and the nuclear fragments suggest that most of these are neutrophils or pieces thereof. The clear spaces in the brain tissue proper represent edema and possibly some myelin swelling. One of many bacterial agents could cause such a lesion. Listeria should be a prime suspect.

PLATE 555: ABSCESSATION OF MEDULLA

The distinct 9x5mm. focus in the middle portion of this medulla is rather discrete and bulges from the cut surface. A few petechiae and ecchymotic hemorrhages are also scattered in the medulla. While it is possible for almost any bacterial agent to be isolated from such a case, it is most prudent to consider first Listeria monocytogenes as in this cattle case. Of note is the fact that cold storage of this brain prior to culture attempts often enhances the chances to isolate the organism. The great majority of acute listeriosis cases do not have gross lesions, but chronic cases such as those treated with antibiotics may have such a lesion as shown above.

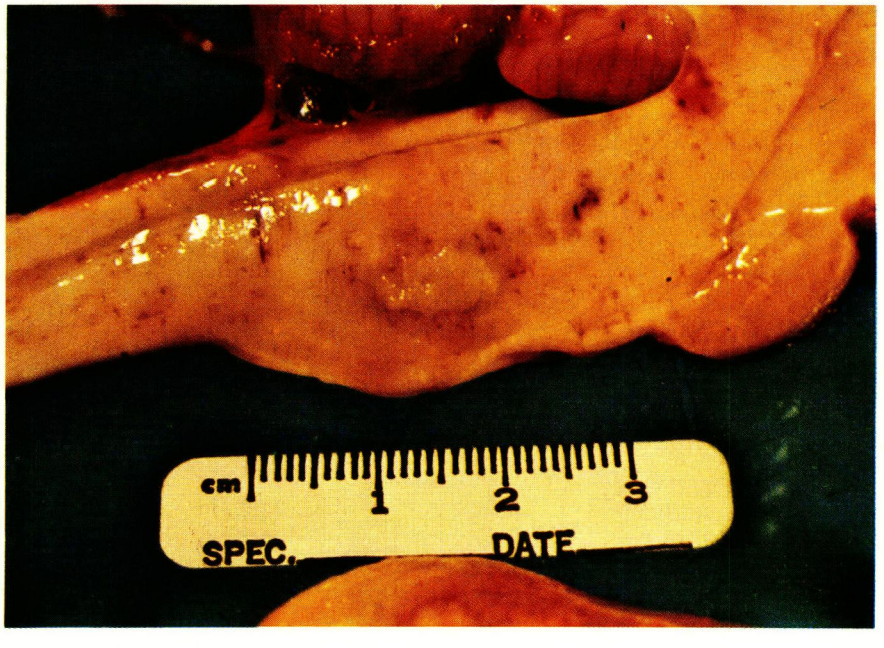



PLATE 556: CRYPTOCOCCAL GRANULOMA

This relatively large lesion in one vermis of the cerebellum is a mass of tissue debris, inflammatory reaction and a central pocket of liquefaction associated with Cryptococcus neoformans in a cat.

PLATE 557: TOXOPLASMA GRANULOMA AND HYDROCEPHALUS

The discrete round mass in this brainstem is a solitary granulomatous mass caused by Toxoplasma gondii. The lateral ventricles are dilated and were more so before the brain was opened to let the cerebrospinal fluid (CSF) escape. The granulomatous mass has effectively blocked the aqueduct of Sylvius to cause this acquired hydrocephalus. This photograph is a good "case in point" to show that a mass or lump is often just that, a "lump", until examined further. Grossly, this was diagnosed incorrectly as a neoplasm.

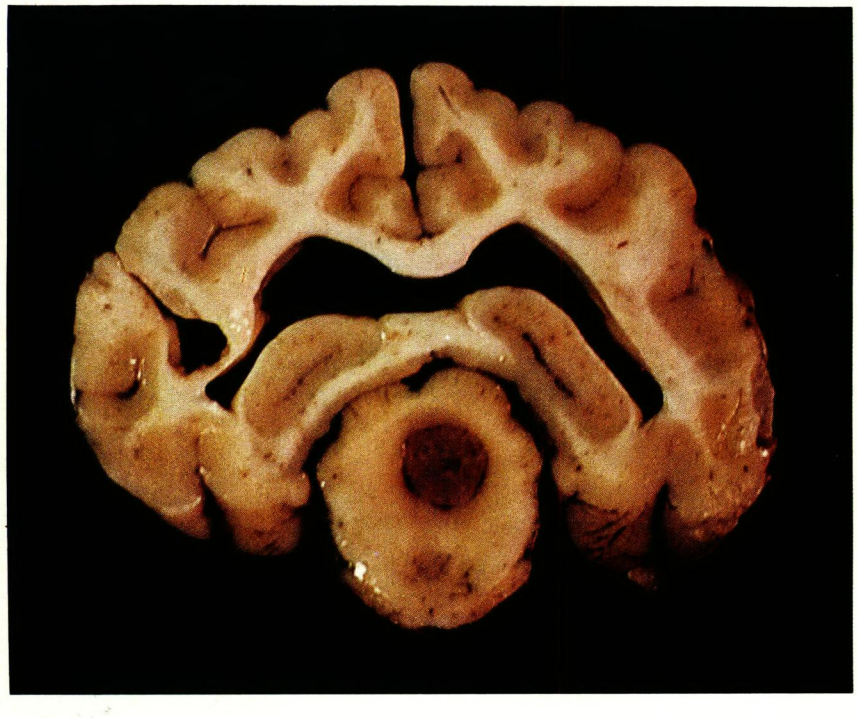

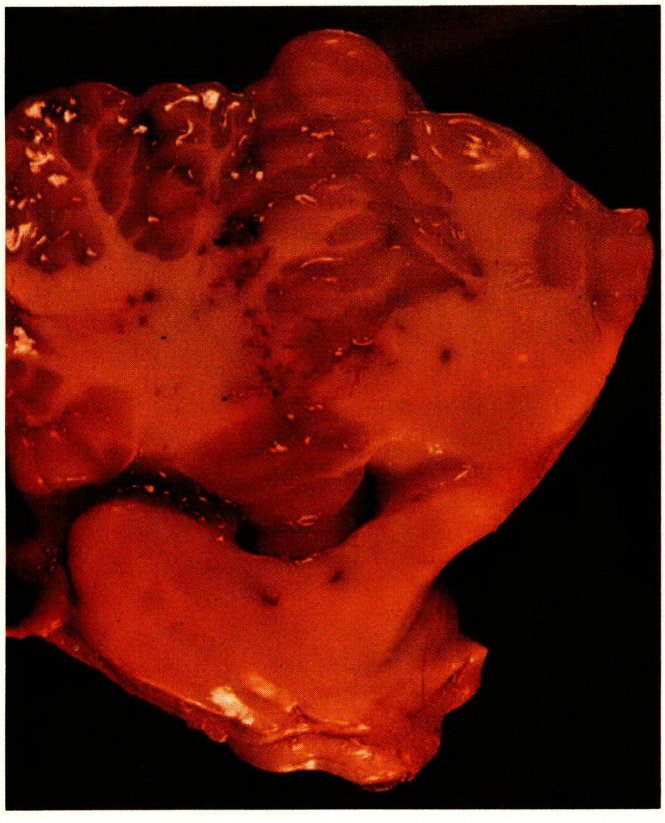

PLATE 558: EMBOLIC ENCEPHALITIS

The several scattered dark foci in the white matter of the medulla and cerebellum and the more concentrated area in the middle portion of the cerebellum shown are areas of acute necrosis and inflammation from vascular obstruction caused by an embolic shower. This horse had a parasitic aortitis in the arch of the aorta caused by S. vulgaris larvae. Pieces of the degenerate, thrombotic debris apparently broke free of the thrombi, became embolic and resulted in this lesion. It is surprising that in the many bacterial vegetative endocarditis cases in domestic animals more emboli do not go to the brain.

PLATE 559: EOSINOPHILIC CUFFING

The majority of cells making up the cuffs around these vessels are eosinophils. In pigs with almost timed nervous convulsions, such as every 5 minutes or every 12 minutes, etc. plus having this lesion histologically, one can almost be positive it is a case of "salt poisoning". In general, one should consider a parasitic migration quite likely in any species. In sheep and cattle, eosinophilic cuffing may be prominent about the lesions of Listeriosis.

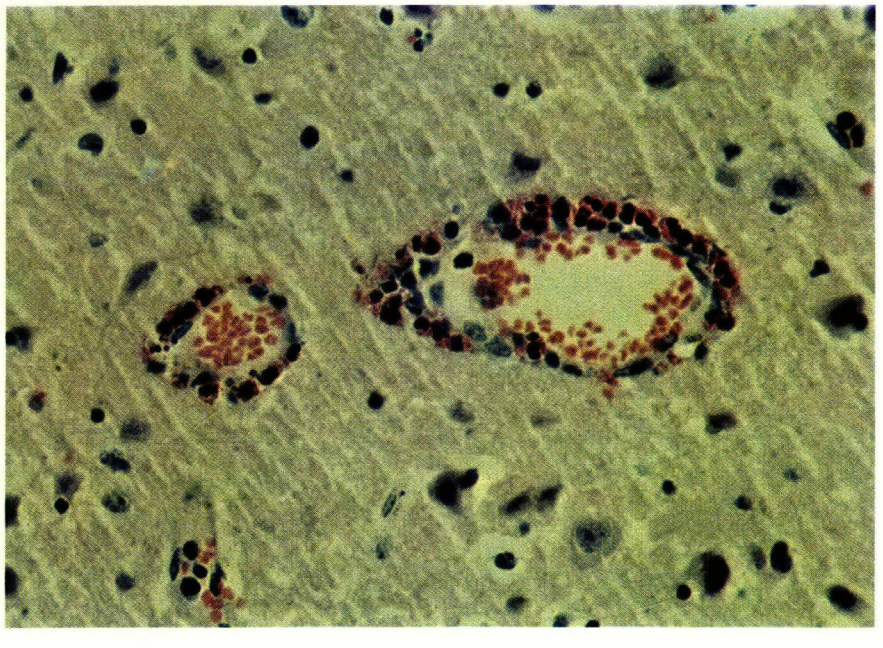



PLATE 560: DURAL OSSIFICATION

The many elliptical, dark streaks and the fewer paler ones are plaques of dural ossification in the relatively thin spinal cord dura mater. These are hard bony plaques. This is most commonly seen in dogs of the large breeds such as Great Danes and St. Bernards. They tend to form, as seen here, over the body of the vertebra leaving the area over the intervertebral discs less involved. Their cause is unknown, although at one time they were considered a sequelae of chronic pachymeningitis. Their dark color is primarily due to bone marrow which has developed in these metaplastic pieces of bone. Marrow formation commonly occurs in any metaplastic bone even that associated with experimentally transplanted urinary bladder epithelium.

PLATE 561: VERTEBRAL CANAL ABSCESSATION

In the vertebral canal just above L6-S1 and L4-L5, there are two yellowish dry abscess pockets. These are associated with a purulent infection of the adjacent spinal cord with resultant paresis. The pig was "down" in the rear quarters and had decubital sores on its hocks and tail stump. The amputation of the tail, which may have been caused by tail biting, is considered the source of entry for the Staphylococcus spp. which was isolated from these abscesses. Some animals with a similar lesion higher in the cord may ambulate by balancing, or attempting to, on their forelimbs with their rear quarters swinging between their forelimbs.



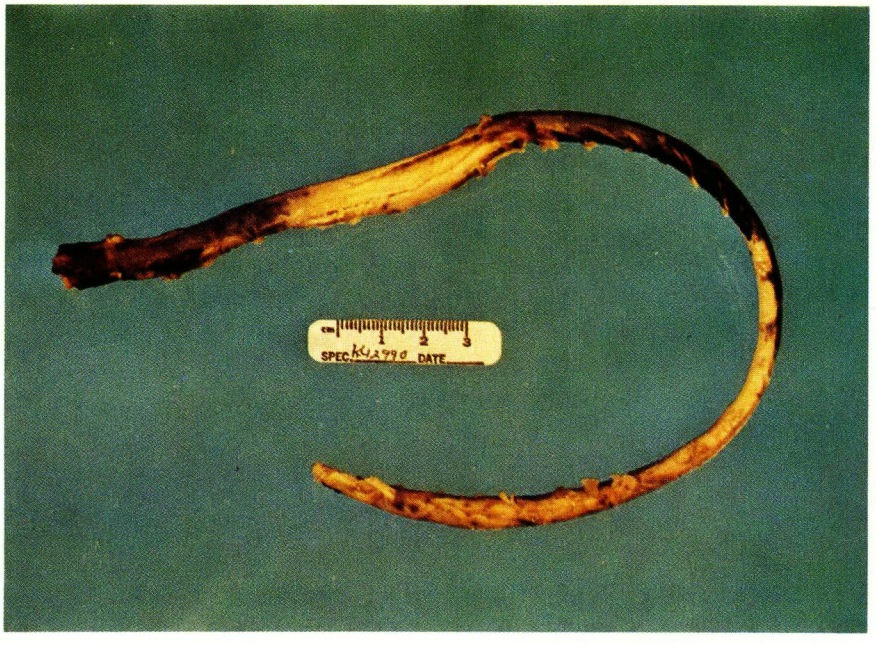

PLATE 562: HEMORRHAGIC MENINGITIS

The two large areas of hemorrhage in the meninges of this dog's spinal cord are associated with the so called "beagle pain syndrome". Histologically, a severe necrotizing vasculitis was found. The lesion may also be in the brain proper. Its exact cause is unknown. The affected animals act like they have severe cervical cord disease of some type and any forced movements of the head may elicit a pain response. It is not limited to beagle dogs. The picture is included here as such a gross lesion may be seen in any animal with an acute bacterial meningitis, a bleeding disorder or trauma to the cord. In fact in one of the author's first cases of beagle pain syndrome, the lesion was grossly considered to be a traumatic one until the histological findings demonstrated the morphological lesion in the vessels. Traumatic cord lesions may make a somewhat similar lesion grossly.

PLATE 563: MYELOMALACIA

This longitudinal section of spinal cord shows the denser grey matter in the center and the markedly vacuolated white matter on either side. The vacuoles are demyelinated nerve fibers and edema. Many slightly elongated oval areas of vacuolated fibers are easily seen, some of which have bits and pieces of degenerated axon material in them. This lesion occurs at the area of trauma as from vertebral fractures or prolapsed intervertebral discs (traumatic myelomalacia). Cross sections of this lesion may show just oval vacuoles. Just one or two vacuoles in the case of equine wobblers may be all that is seen in the cord to justify the diagnosis. Wandering parasites may make a similar lesion.

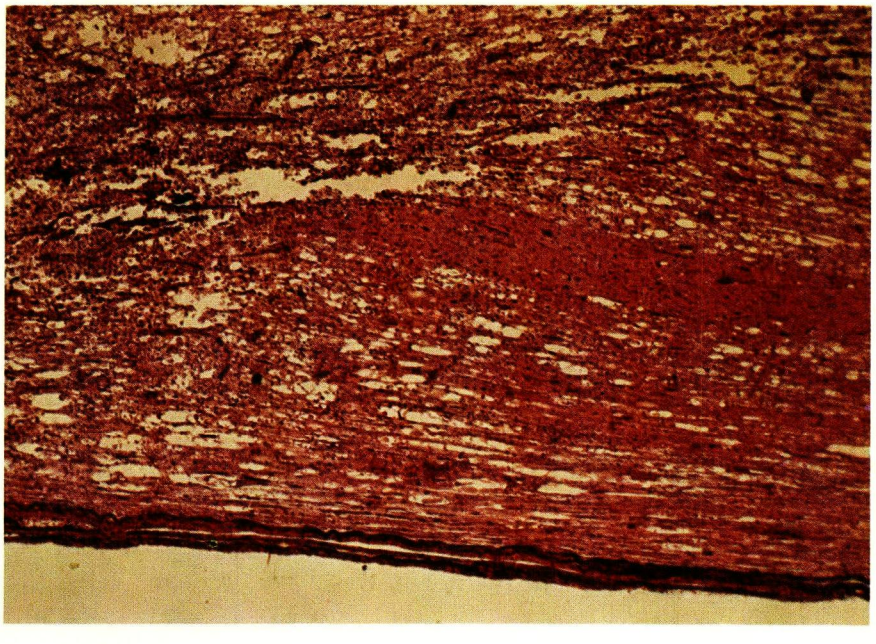



PLATE 564: HYPOPYON

The opaque white material in the anterior chamber is a clump of purulent debris. Histologically, neutrophils will be present in the ocular tissues to show that this is an inflammatory process. This lesion in any young animal can almost be considered pathognomonic for septicemia. If one does not look closely, or if the fibrin is also in the posterior chamber, it may be mistaken for a cataract (pathological clouding of the lens), or a pseudocataract that results from chilling, but which clears up when the carcass is rewarmed.

PLATE 565: KERATITIS

The anterior medial aspect of this piglet's left cornea has an irregular, opaque surface. Histologically, there is surface irritation with many neutrophils invading the periphery of the lesion. This could be the result of a traumatic injury to the cornea with a secondary infection or it could be a primary infection. From this view, one would have to be careful to distinguish it from a clump of fibrin in the anterior chamber (hypopyon).





PLATE 566: CONGENITAL GOITER

These two lambs have massively enlarged thyroid glands which histologically turned out to be hyperplastic goiter. While most cases of goiter are associated with iodine deficiency there are others, such as these, which are related to a plant poisoning caused by members of the Brassicaceae family, rape and kale. These were eaten by the ewe and the lambs were born with the condition, congenital goiter. It should be noted that there is some difficulty in goiter evaluation as twin lambs may be born with one lamb having hyperplastic goiter and the other having colloid goiter. Often in congenital cases at least, hair covered animals may have wool like hair and in wool covered animals, the wool may be more hair like.

PLATE 567: GOITER

The tongue and lung are normal but the thyroid is probably 100 times normal size. The large cystic appearance suggests this is cystic goiter and not hyperplastic goiter with cellular proliferation of the follicular epithelium. Iodine deficiency itself or some plant related problem as with rape and kale pastures can be involved.

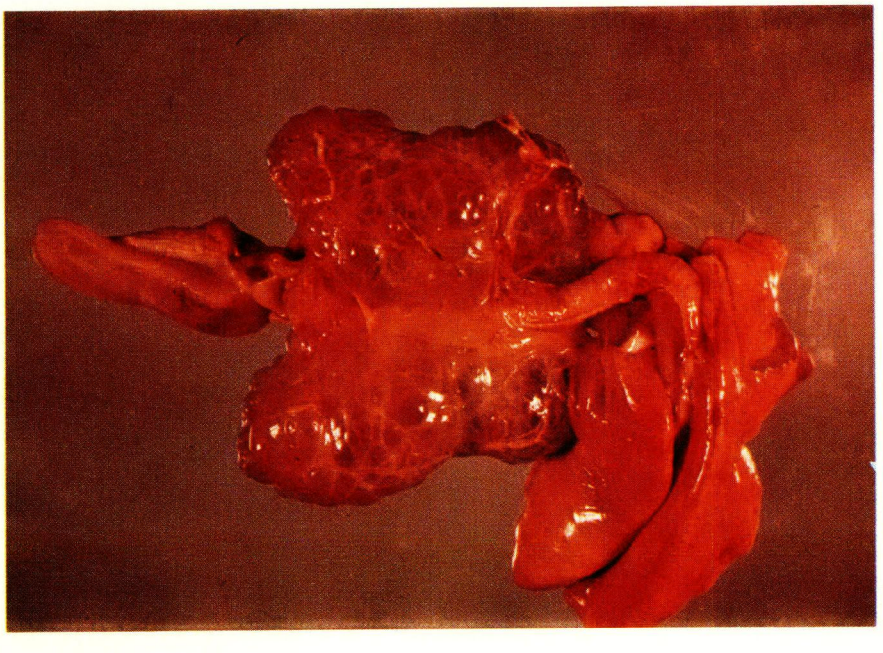

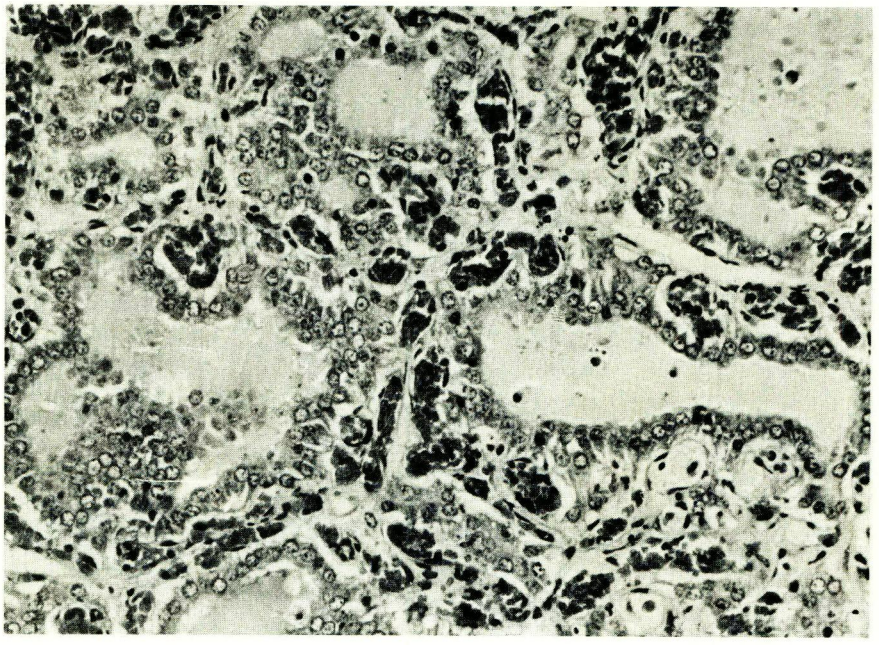

PLATE 568: HYPERPLASTIC GOITER

There is a marked increase of cuboidal cells about these follicles and in some areas have piled up upon themselves. There is a decrease in follicle pressure as indicated by the infolding and collapse of the follicular walls and colloid is absent. A few small dark cells in the cuboidal epithelium suggests increased mitosis. Most of the capillaries are engorged. Iodine corrected this problem in the herd of pigs.

PLATE 569: ADRENAL CONGESTION

The extreme congestion of the adrenal of one piglet is in contrast to the adrenal from another normal piglet. This is considered an incidental lesion in cases of septicemias. Its true significance is unknown.



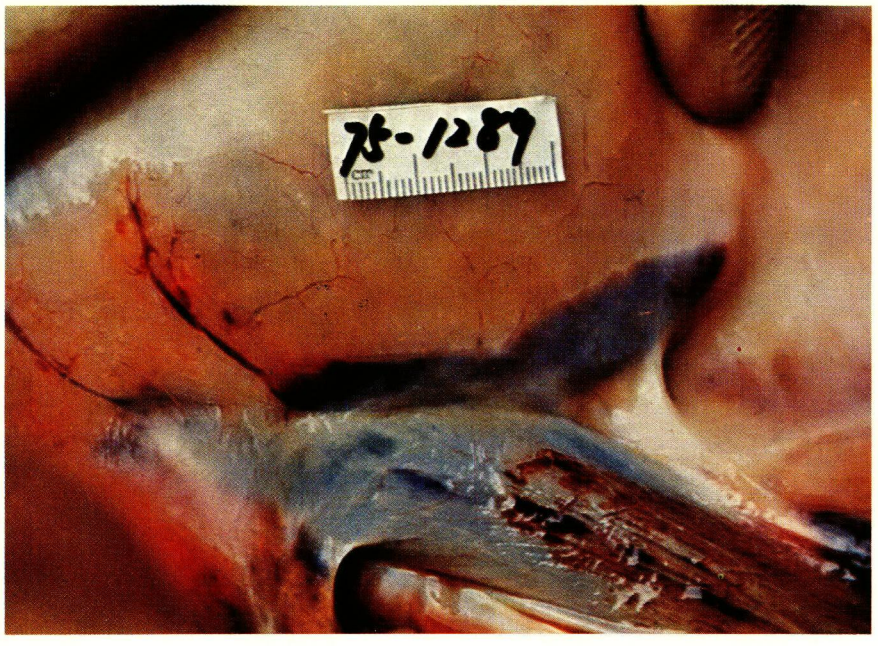

PLATE 570: ADRENAL ATROPHY

The number label lies on the normal pale kidney. Slightly medial and anterior to this, the curved, dark, flattened, atrophic adrenal lies between the kidney and the abdominal vena cava. The brownish tissue on the vena cava is adventitious liver. A normal adrenal is usually more pale and bulges above the peritoneum in an elongated, roundish lump like fashion. Most cases of adrenal atrophy in animals are associated with disuse atrophy such as is commonly seen in captured wild animals. These wild animals often die after a sharp, loud noise or other stress, from adrenal failure to stimulate gluconeogenesis. The animals die in hypoglycemic convulsions. This pig died with classical PSS (porcine stress syndrome) with a history of sudden death, marked elevation of fresh carcass temperature, scattered pale muscle masses with interfascial edema, some excess of fluid and fibrin in body cavities and greatly reduced adrenal gland size. This adrenal lesion is a progressive one and the adrenal gland lesion may be seen without the other lesions if the animal happened to die from some other intercurrent disease first. A genetic predisposition is suspected. PSS is just one of the five stages of this problem of adrenal atrophy. The entire problem is not fully understood.

PLATE 571: ADRENAL ATROPHY

The five sets of adrenal glands shown here demonstrate well the problem that exists in the interpretation of this lesion. The pair of glands set off by themselves are essentially normal and weigh a total of 7.6 gm. in this 32 Kg. pig. The other four are in various stages of atrophy. The total adrenal and body weight for each is 3.03 gm.-33 Kg., 3.95 gm.-32 Kg., 4.3 gm.-90 Kg. and 5.03 gm.-90 Kg. respectively. The two 90 Kg. pigs had the typical necropsy findings of porcine stress syndrome (PSS) which included fibrin in the body cavities, high carcass temperature and pale major muscle masses with interfascial edema. The smaller pigs had small adrenals and died from some other intercurrent disease not necessarily related to the adrenal lesion. The cause of this problem is not known, but a genetic problem is suspected.

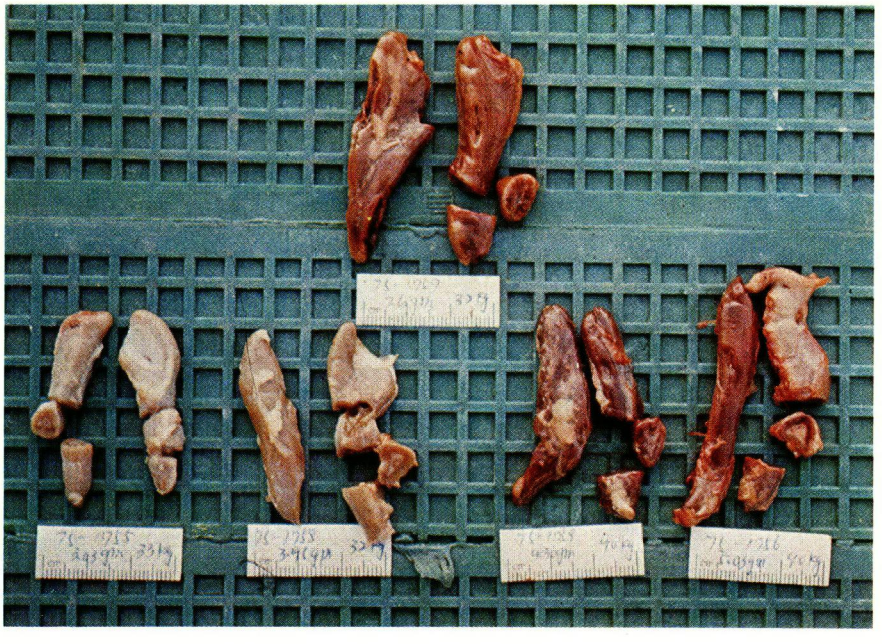



PLATE 572: ADRENAL ATROPHY

The middle pair of adrenal glands are greatly reduced in size and weight in this 59 Kg. pig. The other two pairs are essentially normal in size and weight. This affected animal had pale muscles with interfascial edema and it had died suddenly with a high fever. Porcine stress syndrome (PSS) was diagnosed. The actual cause of this atrophy is unknown. There may be a genetic factor involved.

ADDITIONAL NOTE

In the study of this problem during 1975 in Taiwan, there appears to be five different recognizable categories. The first four categories usually include pigs over 35 Kg. that die suddenly, often following stress. Most have some fibrin deposition with slight excess fluid in serous cavities. Pigs in the first category have, in addition to the above, a high fever at death, early onset of rigor, pale muscles with edematous fascia and small adrenal glands. Pigs in the second category are similar to the first category pigs except their adrenals are normal grossly. The third category pigs do not have muscle or fascial lesions, but they may have a high fever at death and their adrenals are smaller than normal. Forth category pigs are similar to the third category but their adrenals are normal. The fifth and largest category includes the many pigs with small adrenals that die from some intercurrent disease. Given time and proper conditions they probably would have died in the same fashion as category one and three pigs. The explanation for all these is not known but one should consider a functional defect of the adrenal in the categories II and IV. Their adrenals are grossly normal, but the history and gross findings are similar to groups I and III. A hereditary problem is suspect in this disease complex, but disuse atrophy can not be ruled out. Category I and II pigs are recognized as having classical PSS. Occasionally, a pig may die with an intercurrent disease which triggers the PSS lesions.

ADRENAL FAILURE

	Stress	Large Pig 35Kg.	Sudden Death	Serous Cavity Fibrin	High Fever at Death	Early Rigor	Pale Muscles	Fascial Edema	Small Adrenals
I	+	+	+	+	+	+	+	+	+
II	+	+	+	+	+	+	+	+	–
III	+	+	+	+	±	±	–	–	+
IV	+	+	+	+	–	–	–	–	–
V	?	?	?	?	?	–	–	–	+



PLATE 573: PHEOCHROMOCYTOMA

This irregular portion of abdominal vena cava shows a reddish brown nodule extending into its lumen from the adrenal gland which has been cut across. The cut section shows the brown, essentially normal cortical tissue and a red, glistening, swollen center which is the pheochromocytoma derived from the medulla. The tumor has invaded into the adrenal vein and the vena cava. This is a relatively common tumor of older animals especially rats and dogs, and, in this case, a bull. Most are not clinically evident.

PLATE 574: PITUITARY HYPERPLASIA

Portions of the hyperplastic pars anterior of the pituitary are bulging out on both sides of the pars distalis from the pituitary fossa on the floor of this sheep's skull. Histologically, there is a marked cellular increase (hyperplasia) of the anterior part (pars anterior) of the pituitary, but the cause is not known. The other endocrines were normal. This is one of several aged ewes having this lesion that died suddenly with lesions of "overeating disease" caused by C. perfringens type D.

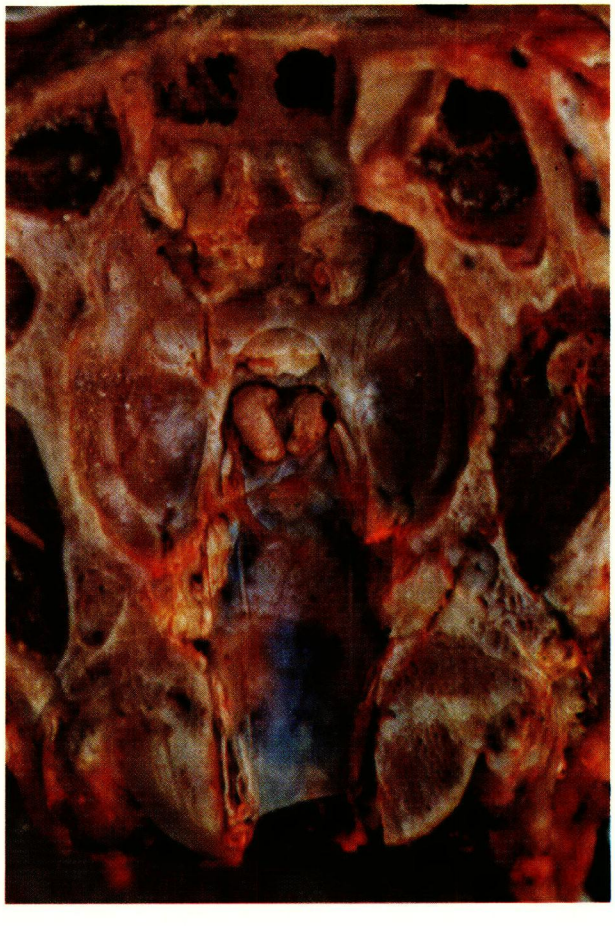

Index

Abdominal press, 477
Abiotrophy, 531, 540
Abortion, mycotic, 50
Abscess, embolic, 143, 200, 201, 305, 306, 423
  femur, 62
  hematogenous 305, 306, 423
  intradural, 39
  jaw, 49
  joint, 81
  liver, 304
  lung, 276, 279, 303
  medulla, 555
  metastatic, 143
  ovary, 230
  urachal, 224
  vertebral, 84
  vertebral canal, 561
Adenocarcinoma, 248
  mammary gland, 248
  metastatic, 154
  nasal, 271
Adenomatoid reaction, 338, 339, 340, 342
Adenomatosis, 338
Adipocere, 114
Aelurostrongylus abstrusus, 405
Aflatoxicosis, 136, 139, 140, 141
Algor mortis, 1
Alizarin Red S, 56
Allergy, 15
Alopecia, endocrine, 17
Amelia, 165
Amyloid, iodine test, 191
Amyloidosis, 430
  glomerular, 191, 192, 193
  primary, 138, 430
  secondary, 138, 430
Anaphylaxis, 298
Anasarca, 22
  fetal, 20
Anemia, 6, 7, 60
Anencephaly, partial, 533
Anomaly, 298
  anus, 10
  brain, 532, 533
  congenital, 11
  heart, 23, 274
  limb, 55
  lymphatics, 20
  palate, 262
  renal, 167
Anoxic change, liver, 122
Anthracosis, 301
Anus, imperforate, 10
Aplasia, renal, 166
Arteritis, verminous, 406
Arthritis, chronic, 77, 78, 384
  fibrinous, 75
  serofibrinous, 76
Ascaris, 150
Ascaris lumbricoides, 495, 496
Ascites, 107
Aspergillosis, 50, 436, 443
Atelectasis, 321
  acquired, 279, 289
  artefactual, 289
  fetal, 275, 288
Atony, gastrointestinal, 492
Atresia, coli, 507, 508, 509
  recti, 10
Atrophic rhinitis, 261, 263, 265, 266, 267, 268
Atrophy, adrenal, 570, 571, 572
  disuse, 570
  liver, 128
  testicle, 254, 256
  villus, 491
Atypical interstitial pneumonia, 339, 340
Aujeszky's disease, 544, 545, 550
Autolysis, postmortem, 117, 118
Azoturia, 98

Baby pig anemia, 6, 411
Balantidium coli, 525
Beagle pain syndrome, 562
Benign juvenille hyperplasia, 247
Besnoitia leuckarti, 469
Besnoitiosis, 469
Bezoars, 510
Blackleg, 103
Blackwater, 98
Blister, 29
Blood, inhaled, 293
  smearing of rump, 3
Blue tongue, 404
Bone formation, mesentery, 113
Bordetella bronchiseptica, 265, 266, 319
Bots, 272
Bovine virus diarrhea, 489
Brachygnathia, 60
Bracken fern, 223
Brain/Heart syndrome, 381, 382
Brassicaeae, 566
Bronchiectasis, 327
Bronchiolitis obliterans, 339, 341
  obliterans fibrosa, 341
Bronchitis, parasitic, 349, 351
Bronchopneumonia, 319
  chronic, 310, 322
  necrotic, 332, 333
  purulent, 321
  resolving, 293, 320
Brucella, 254, 258
Bullae, 295
Bull nose, 263, 264
Burn, chemical 249
  first degree, 29
  second degree, 29

Cachexia, 224
Calculi, cystic, 221
Callus, 62, 63
Canalization, thrombus, 396
Candidiasis, 443, 444, 445
Canine distemper, 336, 340
Carcinoma, pancreatic duct, 154
  squamous cell, 54, 86, 214, 440
Carotenoids, 8
Cast, fibrinous, gallbladder, 155
  renal bile, 195
  renal tubules, 193
Cataract, 564
Cellulitis, 249
Cerebellar coning, 535

Cholangitis, 127, 152
parasitic, 153
Circulation, collateral, 398
Cirrhosis, 125
biliary, 125, 127
cardiac, 125, 126
hepatic, 140
Cleft palate, 262
Clonorchis, 152, 153
Clostridium chauvoei, 103
hemolyticum, 130
perfringens, 574
Clot, chicken fat, 392
currant jelly, 392
postmortem, 392
stagnation, 393
Coccidiosis, 493
Coli, atresia, 507, 508, 509
Colitis, focal necrotic, 518
mucohemorrhagic, 516, 517
necrotic, 519, 520, 521, 525
Compression, spinal cord, 43
Congestion, adrenal, 569
artefact, 164
chronic passive, 121, 122, 123, 124, 125
passive, 2
pulmonary, 290, 291
renal, 175
Coning, cerebellum, 535
Content, hernial, 87
Contra coup, 537
Corynebacterium pyogenes, 47, 49, 84, 216, 326
renale, 198, 199
Cor pulmonale, 320, 374, 376
Cryptococcosis, 269, 556
Cryptorchid, 255
Cuffing, eosinophilic, 559
Curvature, snout, 263
Cuterebra, 272
Cyclops, 532
Cyst, bursal, 5
daughter, 148
mesosalpinx, 228
ovarian, 227
parasitic, 148, 149
renal, 171
Cysticercus, 149
Cystic esophageal gland ducts, 450
ovaries, 227
Cystitis, hemorrhagic, 216, 217
necrotic, 218

Decompensation, heart, 298
Decomposition, 117, 118
Decubital sores, 42, 43
Defect, inter-atrial septal, 371
Defect, segmental colon, 507
segmental ureter, 169
subaortic septal, 299, 369, 370
Deficiency, iodine, 566, 567, 568
prothrombin, 26
renal, 172
Vit A, 236
Vit E, 481
Vit K, 26, 27, 95, 158, 404
zinc, 14

Degeneration, fibrinoid, 400, 401
mucoid, 74
myocardial, 382
testicular, 256
Zenker's, 378, 380, 381
Dehydration salts, 161
Deposition, cholesterol, 281
Dermatitis, chemical, 29
mycotic, 50
parasitic, 51, 52, 53
swine pox, 30
swine vesicular disease, 31, 32, 33, 34, 36
ulcerative, 46
Deviation, snout, 263
Diamond skin disease, 37
Dictyocaulus, 347, 349, 350
Dilatation, myocardial, 374, 375
segmental oviduct, 226
Dipetalonema, 352
Dirofilaria, 352
Disease, Aujeszky's, 544, 545
edema, 515
Glasser's, 277, 278
greasy pig, 40, 41
hardware, 447
hemolytic, 287
overeating, 574
silo filler's 341
stiff lamb, 98
swine vesicular, 31, 32, 33, 34, 35, 36, 549, 550
Disease, Vit E/Se responsive, 132, 133, 134, 135
white muscle, 98
yellow fat, 108
Dislocation, cervical vertebra, 61
Disseminated intravascular coagulation, 176, 180
Distemper, canine, 336
Diverticulosis, 505
"Downer", 42
Drastic slaughter, 506
Dwarf, 13, 59

Ear biting, 4
notch infection, 44
Ecchymoses, 294
Echinococcus, 148
Ectopia, 252
Edema disease, 400, 401, 463, 464, 515
gallbladder, 116A
gastric, 463, 464
generalized, 22
hypoproteinemia, 377
perivascular, 403
pitting, 24
pulmonary, 290, 291, 298
spiral colon, 515
subcutaneous, 23
submucosal, abomasal, 470
terminal, 298
Embolism, fat, 354
septic, 71
tumor, 214
Embolus, 395
Embryonal nephroma, 211, 212
Emphysema, 322
bullous, 295
intestinal, 497, 498, 499, 500
mediastinal, 282

node, 427, 428
rumen, 471
terminal, 290, 292, 320
urinary bladder, 222
Empyema, 279, 311, 312, 313
Encephalitis, embolic, 558
equine, 550
nonsuppurative, 543, 544, 545
parasitic, 559
suppurative, 543, 546
viral, 543, 546
Endocardiosis, verrucous, 389
Endocarditis, vegetative, 37, 373, 384, 385, 386, 387
Endocrine alopecia, 17
Endogenous lipid pneumonia, 354
Endometritis, chronic, 234
purulent, 233
Enteritis, fibrinonecrotic, 490
necrotic, 488
Enterotoxemia, 472
Enzootic hematuria, 223
Epidermitis, 34, 41
Epididymitis, 259
Epistaxis, 261
Epithelization, 325
Epithelial pearls, 54
Epitheliogenesis imperfecta, 11, 12, 508, 509
Equine infectious anemia, 294, 300, 393
viral rhinopneumonitis, 147
wobbler, 563
Erosion, skin, 34
Erysipelothrix rhusiopathiae, 37, 78, 384, 385
Erythema, 25
Escherichia coli, 243
Esophogostonum, 494
Estrus ovis, 272
Exostoses, 65
multiple cartilagenous, 57, 58
Exsanguination, 458, 459
Extramedullary hematopoiesis, 411, 116
Exudative epidermitis, 40, 41

Failure, congestive heart, 299
False joint, 81
Fatty liver, 136
Fecalith, 510
Fermentation odor, 243
Fetalization, 340
Fibroma, 242
Fibrosa, osteodystrophia, 66
Fibrosis, absolute, 182
chronic valvular, 389
relative, 120, 182
Fibrotic tags, 237
Fimbria, tongue, 442
Fistula, 48
Foamy liver, 118
Focal fibrotic nodules, 237
Foot and mouth disease, 32
Foot rot, 79, 80
Foramen ovale, normal, 367
persistent, 368
Foreign body, bronchial, 312, 313
esophagus, 447
Fracture, femoral, 62
nonhealing, 81
vertebra, 64
Frosting, uremic, 465
Froth, tracheal, 292

Galactophoritis, 245, 246
Gangrene, dry, 21, 45
extremity, 21
Gastrophilus, 272
Gastritis, mycotic, 467
parasitic, 468
ulcerative, 468
Generation, lymphoid, 325
Giant cell, foreign body, 257, 428, 497
Langhans' type, 257
Glasser's disease, 277, 278
Gliosis, 544
Glomerulonephrosis, 183, 184
Goiter, 567
colloid, 566
congenital, 566
hyperplastic, 566, 568
Gongylonema, 449
Granuloma, cryptococcal, 556
epididymis, 254
parasitic, 151
spermatic, 257, 258, 259
spirochete, 46, 47
Greasy pig disease, 40, 41, 51
Granulosa cell tumor, 240

Hairball, gastric, 473, 474
Hamartoma, bronchial, 296, 297
myocardial, 364
vascular, 296
Hardware disease, 447
Hepatitis, infectious canine, 116
Hepatization, grey, 324
red, 324
Hepatomegaly, 121
Hepatosis dietetica, 132, 133, 134, 135, 400, 401
Hermaphroditism, 250
Hernia, congenital, 87
diaphragmatic, 90, 91, 92
genetic, 87
inguinal, 88, 249
liver, 120
liver parenchyma, 119
umbilical, 87
Heart failure lung, 287
Hemangiosarcoma, 115
Hematocyst, endocardial, 366
Hematoma, brain 537
muscle, 95
renal, 172
subcutaneous, 28
traumatic, 129
Hematopoiesis, 74
extramedullary, 115
Hematuria, 28
Hemonchus contortus, 6, 7
Hemophilus, 275, 317, 318, 328, 329, 330, 331, 332, 333, 334, 335, 358
Hemorrhage, brain, 538
by diapedesis, 484
C-M junction, 171
dural, 536

endocardial, 362
epicardial, 361, 363
myocardial, 362
ovary, 229
pancreas, 158
peripheral node, 429
perivascular, 538
petechial, 273
renal pelvis, 173
subcutaneous, 26, 27
vascular, 404
Hemorrhagic bowel syndrome, 3, 6, 7, 484, 485, 486, 487, 488, 489
Hemosiderosis, lung, 287
Hirsutism, 18
Histoplasmosis, 145
Hog cholera, 273, 421, 512, 513, 540, 542
Hookworms, 6, 7
Hyaline membrane formation, 338, 339
Hydrocephalus, 530, 541, 557
Hydrometra, purulent, 231, 232
Hydronephrosis, 170, 218
Hydropericardium, 355
Hydroperitoneum, 107
Hydrosalpinx, 226, 228
Hydrothorax, 274
Hydroureter, 170, 218
unilateral, 169
Hyostrongylus rubidus, 468
Hyperemia, physiological, 451, 452
Hyperkeratosis, 14
gastric, 461
Hyperostosis, 65
Hyperplasia, benign juvenile, 247
compensatory, bone marrow, 74
cystic, gallbladder, 156
lymphoid, 325
nodular, liver, 141, 142
nodular, spleen, 412
pituitary, 574
Hypertrophic pulmonary osteoarthropathy, 65, 310
Hypertrophy, idiopathic, distal esophagus, 478
ileal, 478, 479
parathyroid, 280
right heart, 376
tunica media, 405
Hypervitaminosis, D, 280, 399
Hypoderma, 272
Hypoplasia, cerebellum, 540
cerebrum, 540
pancreas, 157
testicle, 255
Hypopyon, 564, 565
Hypostasis, postmortem, 291

Icterus, generalized, 8
Infection, granulomatous, nocardia, 260
Imbalance, mineral, 64, 66, 68, 69, 81
Vit/minerals, 399
Immune sites, 424
Impetigo, 38, 39
Implantation, splenic, 413
Inclusions, acid fast, 67, 70, 137, 188
bodies, distemper, 466
bodies, neuronal, 547
intranuclear, 147
lead, liver, 137
Infarction, bone marrow, 73
healed, 181, 182
liver, 130
polar, 178
renal, 177, 180
splenic, 417, 418, 419, 420, 421
traumatic, 129
traumatic, intestinal, 501
Infarcts, terminal, 176
Infection, costochondral joint, 83
ear notch, 44
hematogenous, 71
Herpes, 540
spirochete, 46, 79, 80
Infectious canine hepatitis, 116
Infiltration, myocardial, 383
Influenza, swine, 337
Intussusception, terminal, 476

Japanese B encephalitis virus, 530, 541
Jaundice, hemolytic, 8
hepatic, 8
obstructive, 8
toxic, 8

Keratitis, 19, 565
Kidney, end stage, 206
horseshoe, 167

Lacrimation, 19
Lactic acid indigestion, 472
Leiomyoma, 241, 242
Leiomyometaplasia, 480, 481
Leiomyometaplasts, 480,481
Leptospira, 202
Leptospirosis, 202, 260
Lesion, end stage, 308
iatrogenic, 26
lung, definition, 283
pathognomonic, 155
Lipidosis, tension, 131
Lipocere, 114
Lipodystrophy, neuronal, 539
Lipofuscinosis, 480
Lipoma, pedunculated, 511
Listeria, 554, 555
Listeria monocytogenes, 555
Liver, adventitious, 570
foamy, 118
nutmeg, 107
threshold of regeneration, 127, 142
Livor mortis, 1
Lordosis, 18, 84
Lung, heart failure, 287, 300, 379
marbling, 316
Lungworm, 289, 348, 350
Lymphadenopathy, 433, 434
Lymphedema, 22
Lymphoid follicles, normal, 502
Lymphomatosis, 67, 73, 440, 441, 470
nasal, 270
renal, 213
uterine, 239

Mange, demodectic, 53
sarcoptic, 51, 52
Marbling of lung, 316
Mastitis, chronic suppurative, 244
septic, 243
Mastocytosis, 475
Megacolon, 10, 506, 508
Mastitis, chronic suppurative, 244
Meningitis, hemorrhagic, 562
nonsuppurative, 546
purulent, 551, 552, 553
suppurative, 553
Meningoencephalitis, nonsuppurative, 546
Mesothelioma, 115A
Metaplasia, bony, 560
squamous, 234
Metastases, 154
Metastrongylus, 348, 349, 350
Microabscessation, brain, 554
Microangiopathy, 400, 401
Microfilaria, 352
Microphthalmia, 56
Milk sand, 246
Milk spots, liver, 132, 150
Mineralization, basement membrane, 190
dystrophic, 281, 399
gastric, 280
metastatic, 281, 399
muscle, 99
pleural, 280
uremic, 465
vascular, 280, 399
Modification, rumen papillae, 462
Moniliasis, 444, 445
Mucormycosis, 50, 208
Mucosalpinx, 226
Muellerius capillaris, 289
Multiplicity of anomalies, 56
Mycotic glossitis, 443
Myelomalacia, traumatic, 563
Myositis, foreign body, 93, 94
gangrenous, 103
iatrogenic 93

Necrosis, coagulation, 438
fat, 159
fat, pancreatic, 159, 160
focal, node, 431
intestinal crypts, 489
locally extensive, liver, 132
lymphoid follicle, 513
multifocal, node, 431
multifocal, liver, 132, 133, 135, 144, 145, 146
renal cortical, 25, 179
tail, 45
tonsil, 435
tumor, 441
vaginal, 238
Negri body, 547
Neonatal isoerythrolysis, 8
Neoplasia, lymphoid, 441
vertebral, 86
Nephritis, 184
bacterial, 200
chronic interstitial, 203, 204, 205, 207
granulomatous, 208
suppurative, 199
Nephrosclerosis, 206
Nephrosis, 185, 186, 187
biliary, 195
hemoglobinemic, 194
Nocardia, 279
Nodular worm disease, 494
Normal fold, spleen, 409
Nosebleed, 261
Nutmeg liver, 23, 24, 107, 122, 123, 124, 368, 371, 372
Nutritional, anemia, 6
muscular dystrophy, 96, 97, 98, 378, 379
secondary hyperparathyroidism, 66
Nymphomania, 240

Obstruction, colon, 510
Odor, fermentation, 243, 459
parasitic, 496,
rancid, 103
Oedemamagena tarandi, 272
Onchocerca, 352
Opisthorchis, 153
Orbital sphenoid bone, protruding wing, 59
Orchitis, allergic, 256, 259
Ossification, dural, 560
mesenteric, 113
Osteodystrophia fibrosa, 66
Osteodystrophy, 64, 68, 69
renal, 280
Osteomyelitis, 71
Osteopetrosis, 60
Osteoporosis, 69A
Osteosclerosis, 70

Palatoschisis, 262
Pallor, postmortem, 360
Panleucopenia, 489, 540
Parachute reaction, 389
Parakeratosis, 14, 51
gastric, 461
Paralysis, 42
Parathyroid hyperplasia, 465
Paresis, 42, 64
front leg, 42
Pasteurella, 309, 358, 435
Perforation, esophagus, 447
intestine, 495
Periarteritis nodosa, 402
Pericarditis, adhesive, 23
fibrinous, 358
fibrous, 359
acute, 358
chronic, 359
purulent, 357
Perimetritis, 232
Peritonitis, 110, 112
bile, 110
chronic, 112
fibrinous, 111
Perivascular cuffing, 542, 544
Peromelia, 165
Persistent foramen ovale, 122
Petechiae, 294
renal, 174
urinary bladder, 215
Pheochromocytoma, 573

Phlegmon, 249
Photosensitization, 19
Pigmentation, endogenous, 8
exogenous, 9
"Pits on pressure", 24
Pityriasis rosea, 15, 16
Placentation, adventitious, 235
Pleomorphism, 248
Pleuritis, adhesive, 278
fibrinous, 276, 277, 318
purulent, 311
serofibrinous, 275
suppurative, 279
Pneumoconiosis, 301
Pneumonia, abscess, 326
atypical interstitial, 339, 540
diffuse distribution, 285
distemper, 336
embolic, 304
endogenous lipid, 354
enzootic swine, 299, 323, 324
fibrinous, 315, 316, 317
foreign body, 279, 308, 314
gangrenous, 308, 309
hematogenous, 302, 303
hemophilus, 328, 329, 330, 331, 334, 335, 405
hemorrhagic, 328, 329, 330
inhalation, 308, 310
locally extensive, 284, 308, 309, 315, 319, 336
mineral oil, 314
multifocal, 283, 302, 303, 304
mycoplasma, 323
pasteurella, 315, 316, 317, 318
post fogging, 347
proliferative, 338, 339, 340
Poisoning, chlorinated naphthalene, 236
cholinesterase inhibition, 548
copper, 194
dicumarol, 404
ergot, 21
fescue, 21
gardenia, 9
heavy metal, 70, 188
lead, 67, 70, 137, 188
mercury, 186
oxalates, 189
salt, 559
selenium, 21
snake bite, 21
warfarin, 26
Polycystic kidney, 168
Polyp, rectal, 504
Polyserositis, 75, 275, 277, 278
Porcine stress syndrome, 98, 100, 101, 102, 570, 571, 572
Portal of entry, 44, 45
Postmortem epidermal sloughing, 4
Postparturient hemoglobinuria, 194
Proboscis, 532
Prolapse, cerebellum, 534, 535
rectal, 503
uterus, 225
vagina, 225, 503
Proliferation, alveolar lining cell, 325, 338, 339, 340
bile duct, 139, 140, 141
endothelial, 422
reticuloendothelial, 424
Proliferative pneumonia, 338, 339, 340
Protostrongylus, 349, 350
Pseudoc. aract, 564
Pseudocyst, toxoplasma, 344, 439
Pseudohermaphrodite, 251
Pseudoinfarct, splenic, 416
Pseudomelanosis, 48, 92, 106, 116, 163
Pseudorabies, 544, 545
Pteridium aquilinum, 223
Pyelonephritis, ascending, 199
bilateral, 196, 197, 198, 199
descending, 199
Pyometra, 231
Pyothorax, 279, 311

Rancid odor, 103
Ranula, 49
Reaction, parachute, 389
Recurring fever, 384, 385, 386
Regeneration, nodular, 141, 142
tubular, 182, 187
Renal cortical necrosis, 25
Rickets, renal, 66
Rigor mortis, 1, 572
Ring, hernial, 87
Ringtail, 45
Rot, 117
Ruminitis, emphysematous, 471
toxic, 472
Runting disease, 13
Rupture, esophagus, 446, 448
urinary bladder, 219, 220

Salmonella, 144, 155, 512, 513, 518, 525
paratyphi, 483
Salmonellosis, 302, 483
Sarcoma, osteogenic, 85
Sarcosporidiosis, 104
Scar, ascarid, 150, 209
parasitic, 209
Scirrhous cord, 88, 89, 249
Scrapie, 548
Sequestration, 72
Serous atrophy of fat, 74, 162
Setaria, 352
Shigella, 146, 306, 490
equirulis, 200
Shigellosis, 200
Siderotic plaque, 416
Silo filler's disease, 341
Silver stain, 202
Sinus, normal frontal, 55
Sirenomelus, 56
Spherophorus necrophorus, 45, 47, 263, 264
Spirochete, 260, 523, 524
granuloma, 47, 48,
Spleen, anesthetic, 410
nembutal, 410
Splenomegaly, 410, 414, 415, 454, 455
Spondylitis, 82, 84
Spondylosis, 82
Squamous cell carcinoma, 54
metaplasia, 236
Staphylococcus, 231, 232, 244, 275, 307, 561
hyicus, 40

Starvation, 139
Steatitis, 108, 109
Stenosis, functional, ureter, 170
  subaortic, 372, 373
Stephanurus dentatus, 210
Stiff lamb disease, 98, 378
Stomach worms, 6
Strangulation, intestinal, 511
Streptococcus, 38, 39, 49, 197
Strongylus vulgaris, 406, 558
Swine erysipelas, 37
  dysentery, 3, 6, 517, 519, 520, 521, 522, 523, 524
  influenza, 337
  pox, 30
  vesicular disease, 31, 32, 33, 34, 35, 36, 549, 550

Tail amputation, 43
  biting, 43
  necrosis, 45
Tamponade, cardiac, 356
Tension lipidosis, 131
Testicle, cryptorchid, 260
Tetany, grass, 68
  winter, 68
Thornyheaded worm, 495
Threshold of regeneration, 127, 142
Thrombus, 393
  embolic, 394
  propagating, 394,
  septic, 394
Thrush, 443, 444, 445
Thymoma, 425, 426
Tonsillitis, mycotic, 436
Torsion, gastric, 414, 454, 455
  intestinal, 477
Torus pyloricus, 453
Toxoplasma, 144, 145, 345, 346
Toxplasmosis, 343, 437, 438, 557
Transmissible respiratory adenoma of sheep, 271
Trauma, 26
Treponema hyodysenteriae, 516
Trichina spiralis, 105
Trichinosis, 105
Trichobezoar, 473, 474
Trichoconcretion, 473, 474
Trichuriasis, 526, 527
Trichuris, 526
True hermaphrodite, 250
Trypanosoma evansi, 408
Trypanosomiasis, 408, 424
Tuberculosis, 116, 431, 432
Tumor, adrenal, 573
  aortic body, 407
  blood vessel, 115
  carotid body, 407
  fetal, 296, 364, 365
  granulosa cell, 240
  heart base, 425
  interstitial cell, 260
  Leydig cell, 260
  malignant, 248
  nonsclerosing, 353
  pituitary, 18
  sclerosing, 353
  Sertoli cell, 260
  smooth muscle cell, 241, 242
  striated muscle cell, 242
  sustentacular cell, 260
Turkey egg kidney, 174

Ulcer, abomasal, 6, 7
  bleeding, 411
  button, 512, 514
  decubital, 48
  duodenal, 475
  gastric, 3, 6, 7, 110, 122, 457, 458, 459
  superficial gastric, 460
  skin, 34
Ulcerative dermatitis, 46
Urachus, persistent, 165
Uremia, 99
Uremic frosting, 280

Vacuoles, neuronal, 548
Vascularization, compensatory, 456
  medusa head, 456
Vasculitis, brain, 549, 550
  necrotizing, 562
Verrucous endocardiosis, 389
Vesicular exanthema, 32
  stomatitis, 32
Vit E/Se responsive disease, 96, 97, 98, 108, 132, 133, 134
  135, 378, 379

Wall, hernial, 87
Warbles, cattle, 272
Whipworms, 527
White muscle disease, 98, 378
Worms, kidney, 210
Wry tail, 56

Yellow fat disease, 108

Zenker's degeneration, 96, 97, 98, 99, 101, 102

AN ATLAS OF GENERAL PATHOLOGY

WITH SPECIAL REFERENCE TO SWINE DISEASES

家畜病理學圖譜

有著作權・不准翻印

著　　者　John M. King　徐興鎔
洪春彬　李崇道

著作權所有人　中國農村復興聯合委員會
代表人　李崇道

發行人　同上

發行所　中國農村復興聯合委員會
中華民國台灣，台北市南海路卅七號

印刷所　中華彩色印刷股份有限公司
中華民國台灣，台北市博愛路六十號六樓
中華民國65年5月出版・1000本
定價：台灣區　新台幣760元
海外美金23元

行政院農委會圖書室
0011314